

MUSCULOSKELETAL SYSTEM

ABDOMINAL WALL

Dr. Aiman Qais Afar
Surgical Anatomist

College of Medicine / University of Mutah
2nd Semester MSS
2025-2026

Monday 9 March 2026

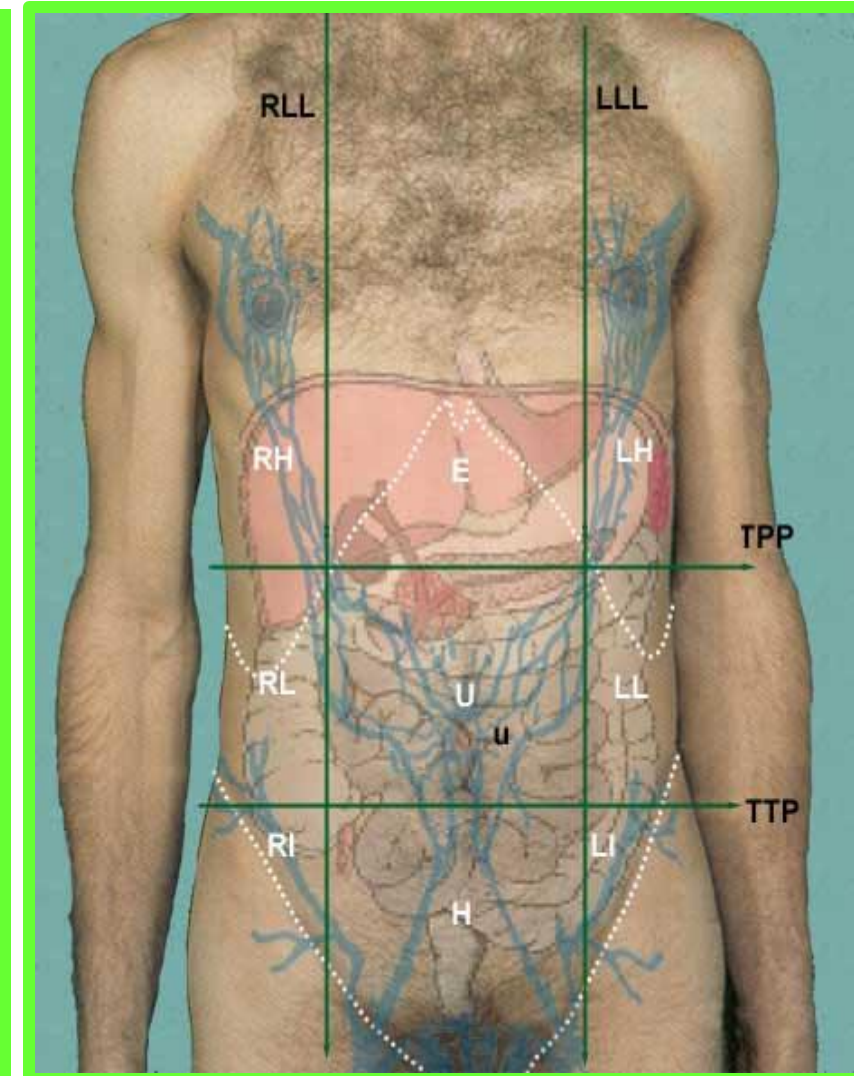
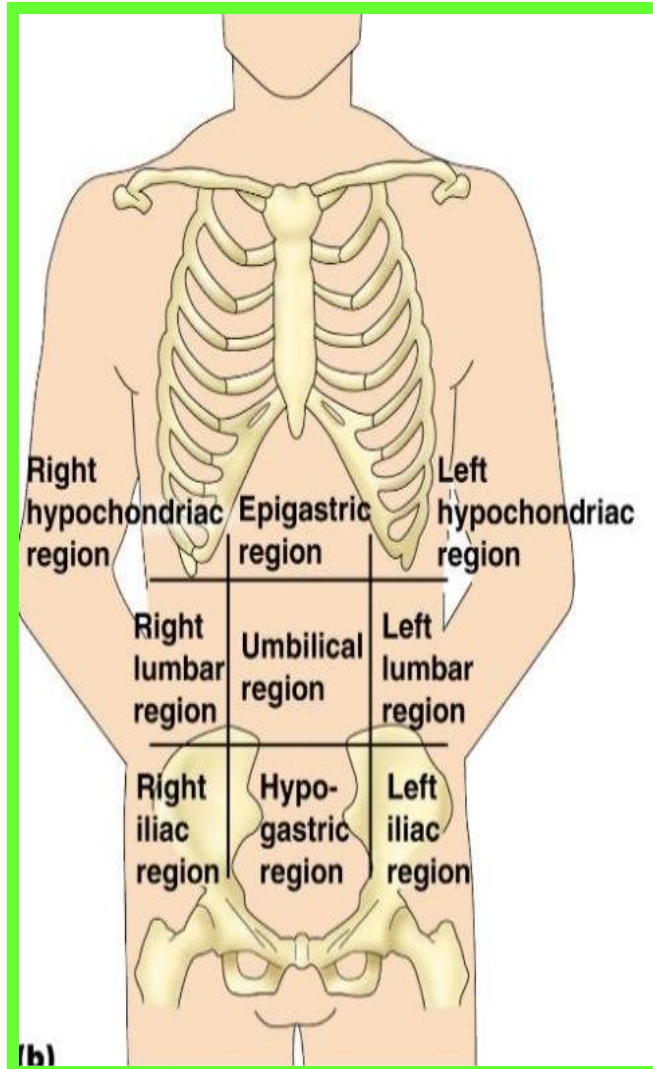
ANTERIO- LATERAL ABDOMINAL WALL

❑ The abdomen is the part of the trunk between the thorax and the pelvis

❑ For clinical purposes the abdomen is divided into nine regions by:

✓ Two vertical lines (**midclavicular, midinguinal**)

✓ Two horizontal lines (**intertubercular plane**) between the tubercles of the iliac crest and the (**transpyloric plane**)



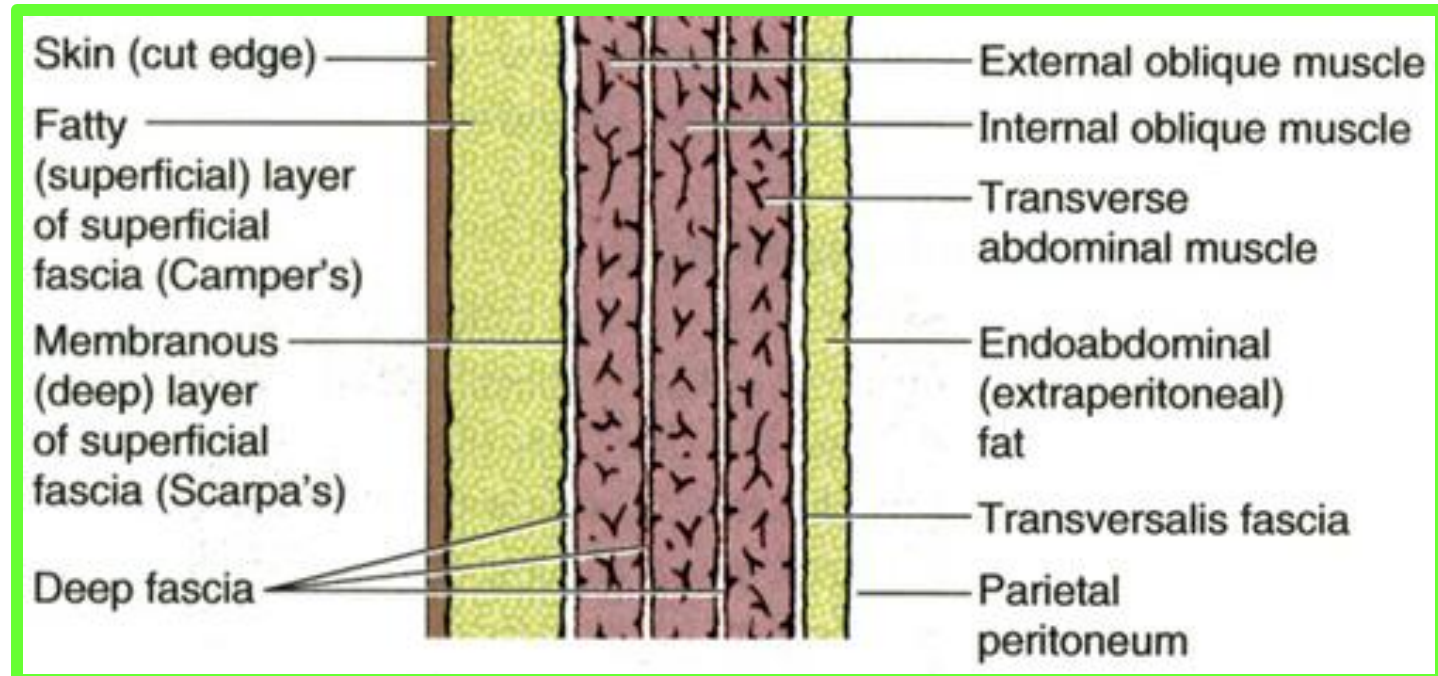
ANTERIO-LATERAL ABDOMINAL WALL

The wall consists of :

❖ Skin attaches loosely to the subcutaneous tissue, except at the umbilicus, where it adheres firmly.

❖ The subcutaneous tissue here has two layers: a superficial fatty layer (**Camper fascia**) and a deep membranous layer (**Scarpa fascia**).

Males are especially susceptible to subcutaneous accumulation of fat in the lower anterior abdominal wall



Muscles of the Anterolateral Abdominal Wall

3 flat muscles:

External oblique

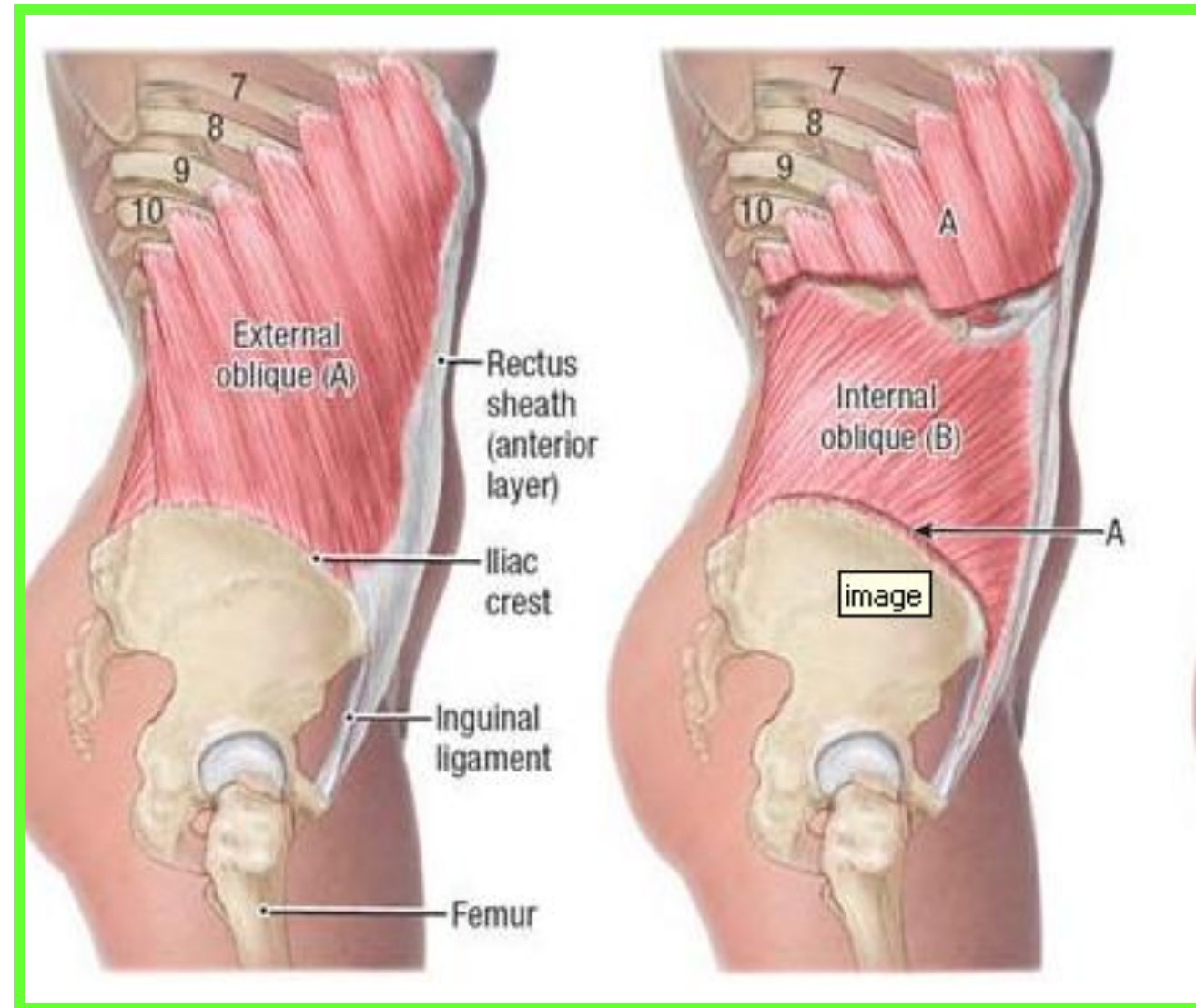
Internal oblique

Transversus abdominis

2 Vertical muscles:

Rectus abdominis

Pyramidalis



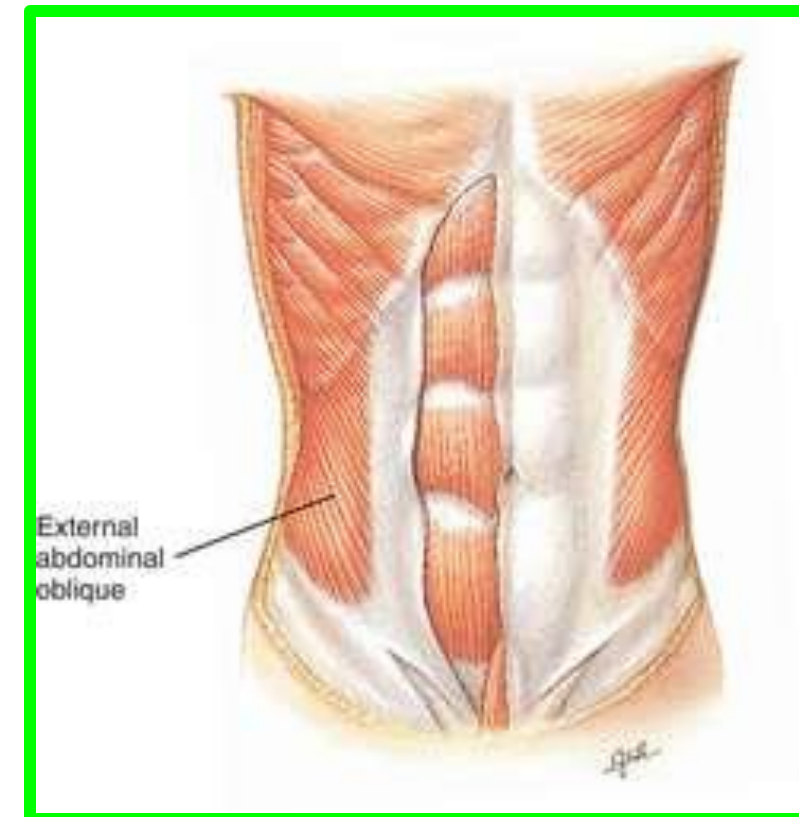
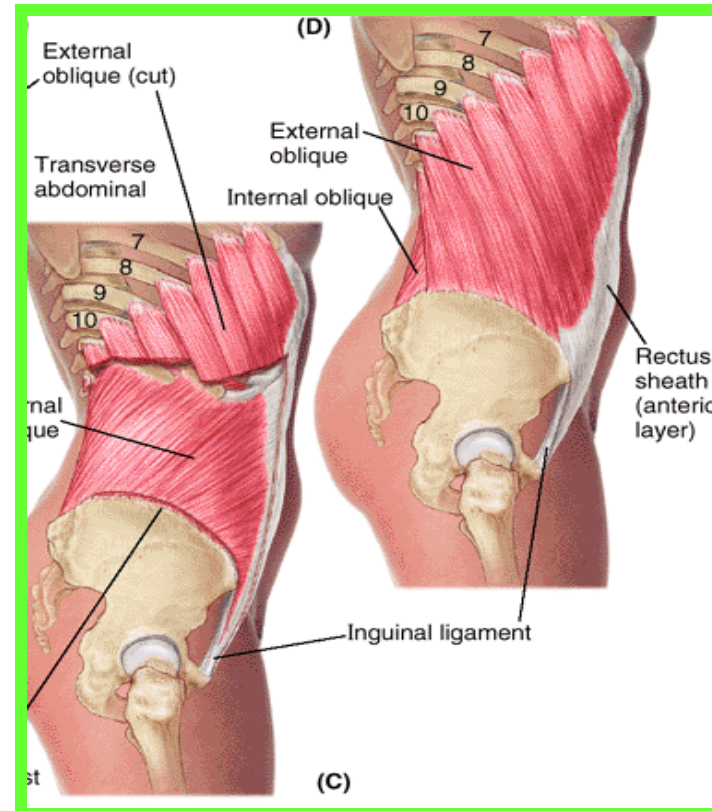
External Oblique Muscle

Dr. Aiman Qais Al -Maathidy

- ❖ Is the largest and most superficial of the three flat anterolateral abdominal muscles.
- ❖ **The fleshy part** of the muscle contributes primarily to the lateral part of the abdominal wall.
- ❖ **Its aponeurosis** contributes to the anterior part of the wall.

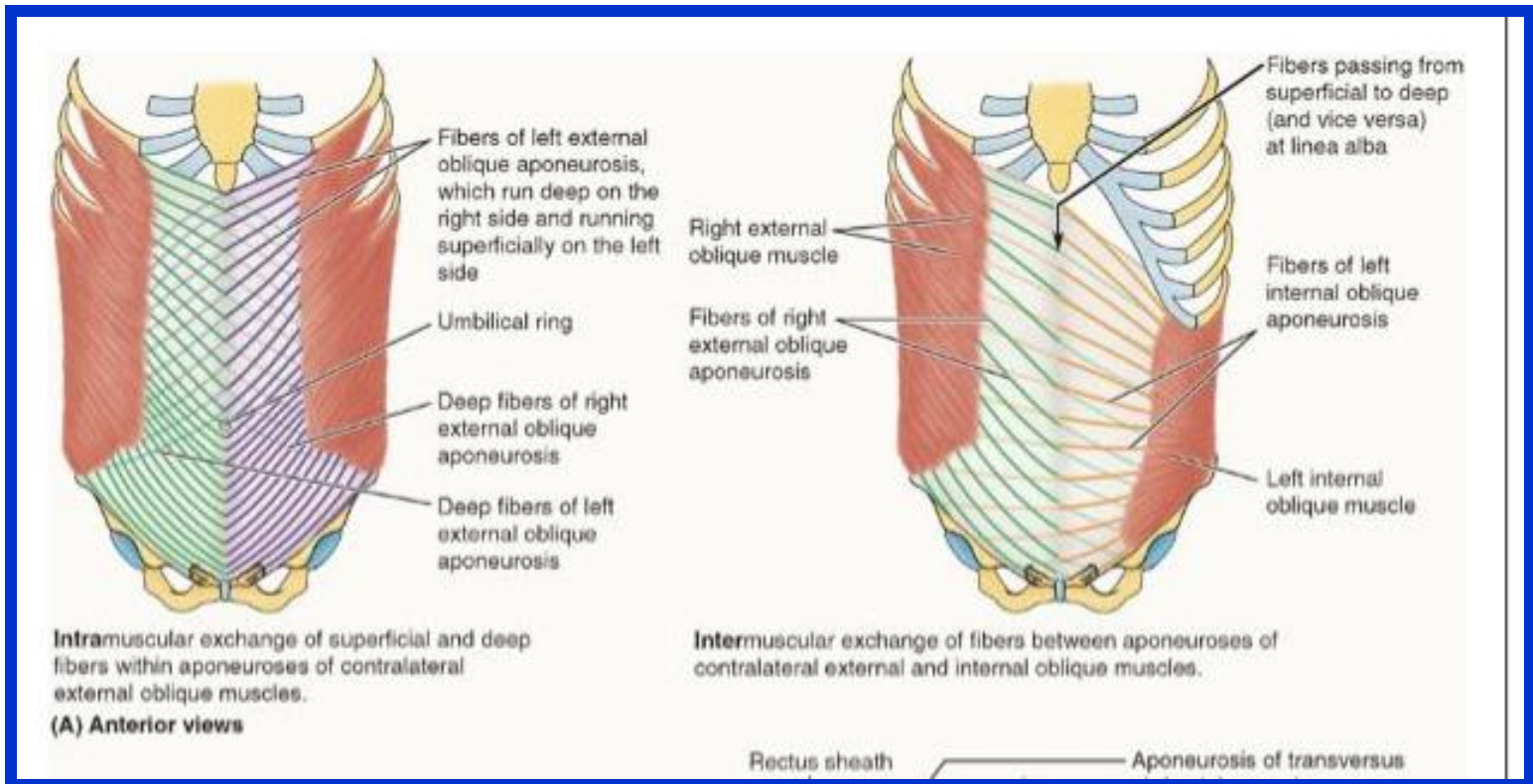
❖ **Origin :** External surfaces of 5th--12th ribs

❖ **Insertion :** Linea alba, pubic tubercle, and anterior half of iliac crest



External Oblique Muscle

- ❖ The muscle fibers become aponeurotic approximately at the **MCL** medially and at the **spinoumbilical line** (line running from the umbilicus to the **ASIS**) inferiorly, forming a sheet of tendinous fibers that decussate at the linea alba, **most becoming continuous with tendinous fibers of the contralateral internal oblique**
- ❖ Thus the contralateral external and internal oblique muscles together form a “**digastric muscle,**” a two-bellied muscle sharing a **common central tendon** that works as a unit



Dr. Aiman Qais Al -Maathidy

Monday 9 March 2026

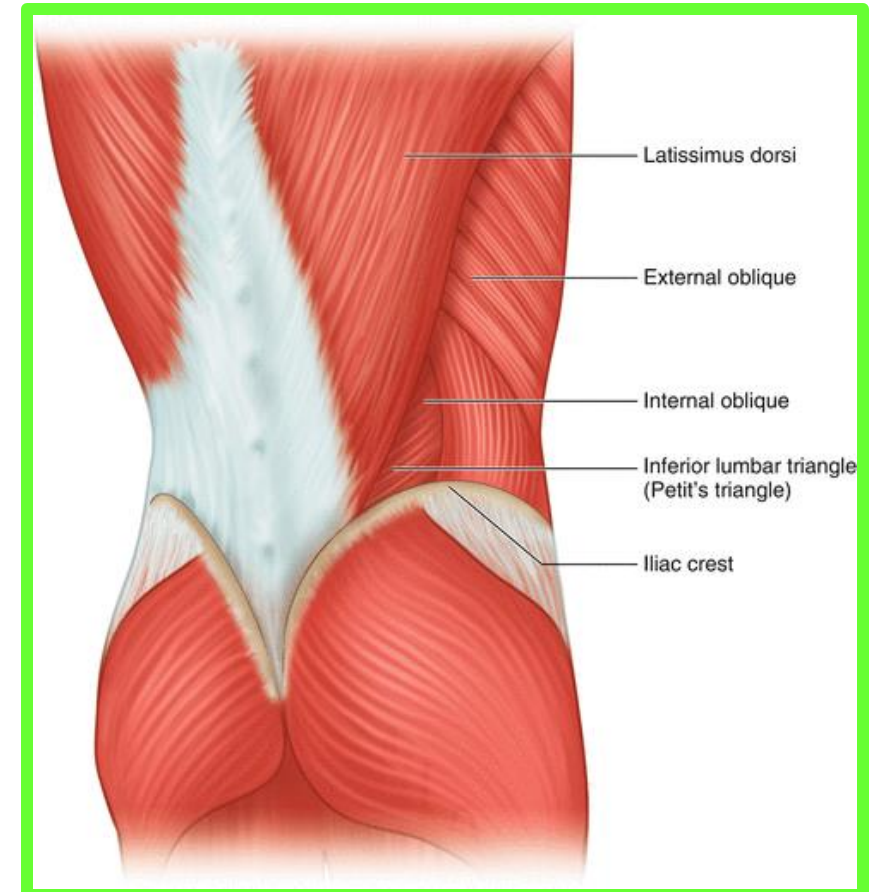
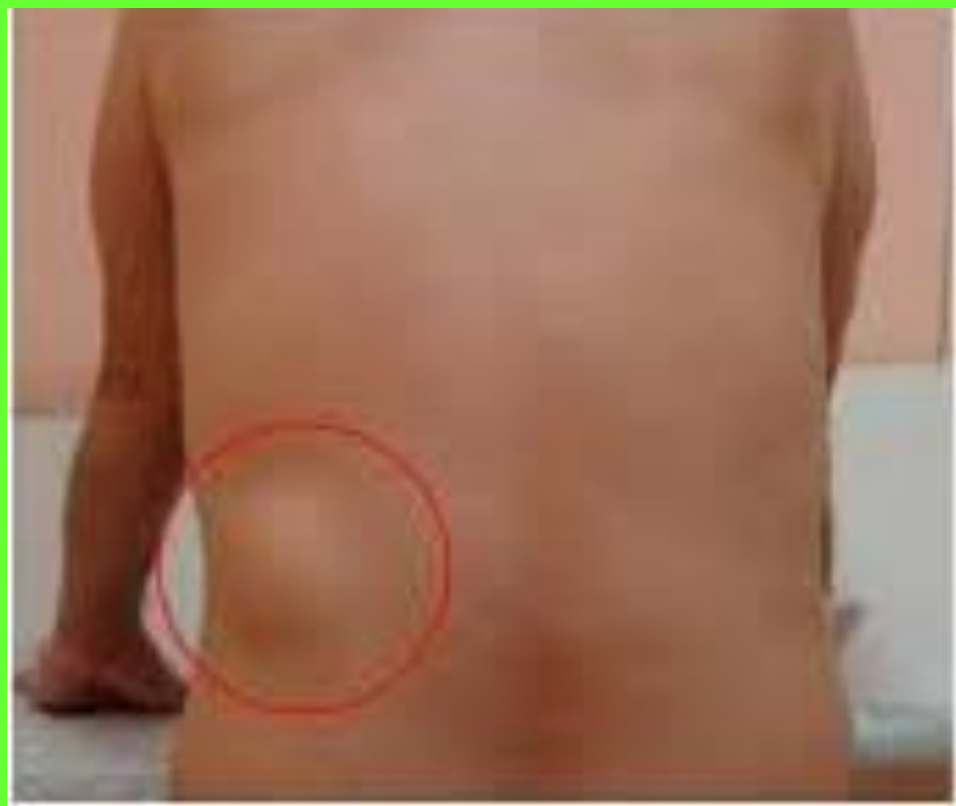External Oblique Muscle

7

Dr. Aiman Qais Al -Maathidy
Monday 9 March 2026

The free posterior border of the muscle forms the anterior boundary of **the lumbar triangle (of Petit)**

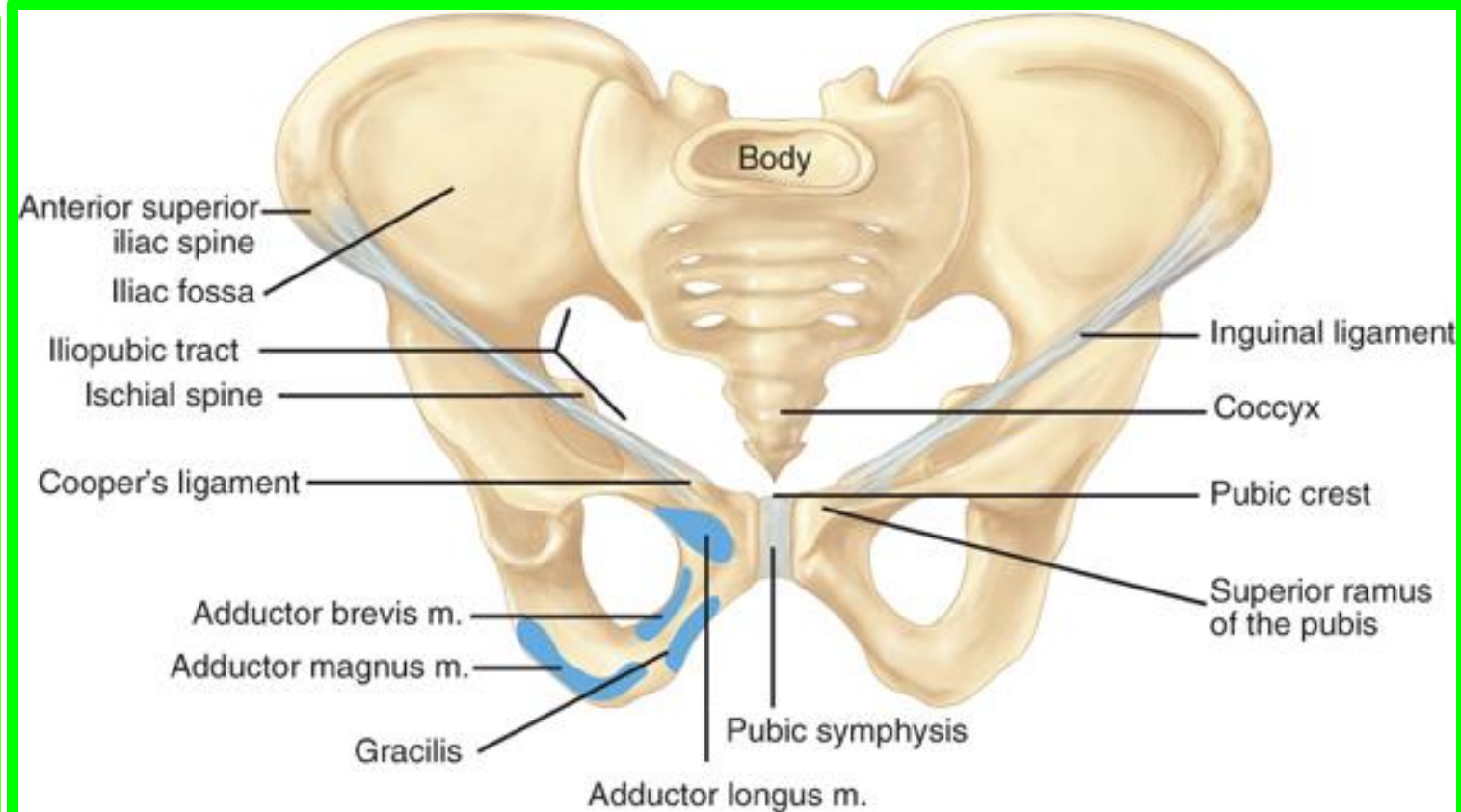
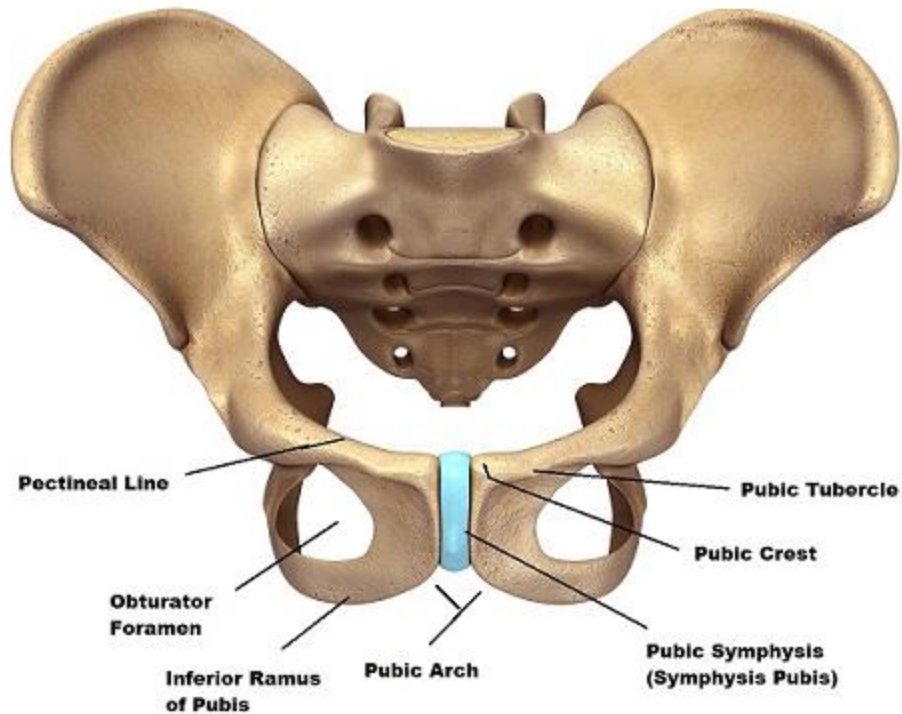
that is floored in by the **internal oblique** and bounded behind by the **anterior border of latissimus dorsi** and below by the **iliac crest**. **The triangle may be the site of a rare lumbar hernia**



External Oblique Muscle

- ✓ Inferiorly, the external oblique aponeurosis attaches to the pubic crest medial to the pubic tubercle.
- ✓ The inferior margin of the external oblique aponeurosis is thickened as an undercurving **fibrous band** with a free posterior edge that spans between **the ASIS** and the pubic tubercle as **the inguinal ligament (Poupart ligament)**

Bony Pelvis (Anterior View)



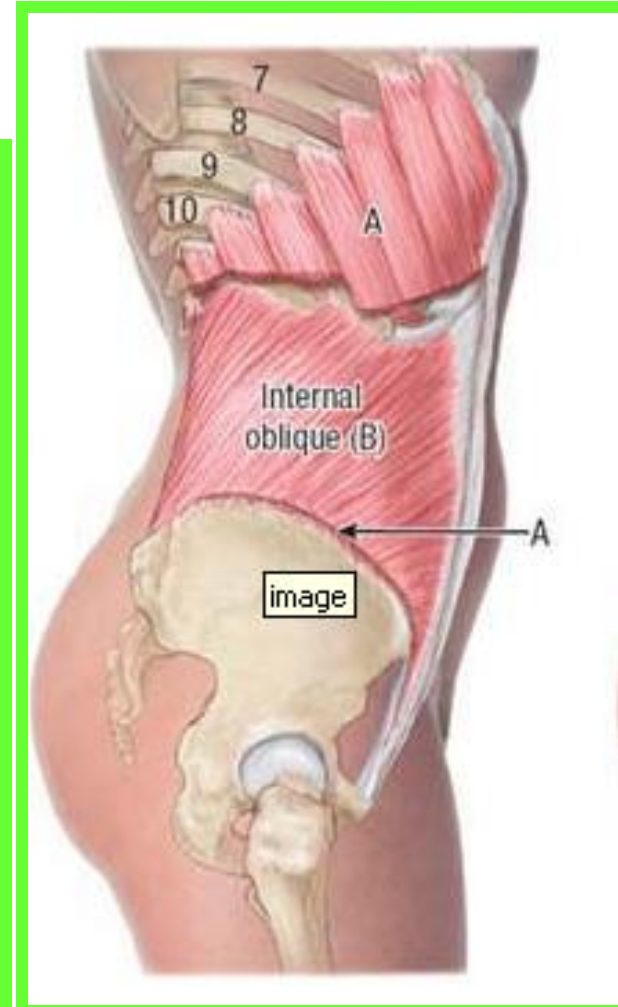
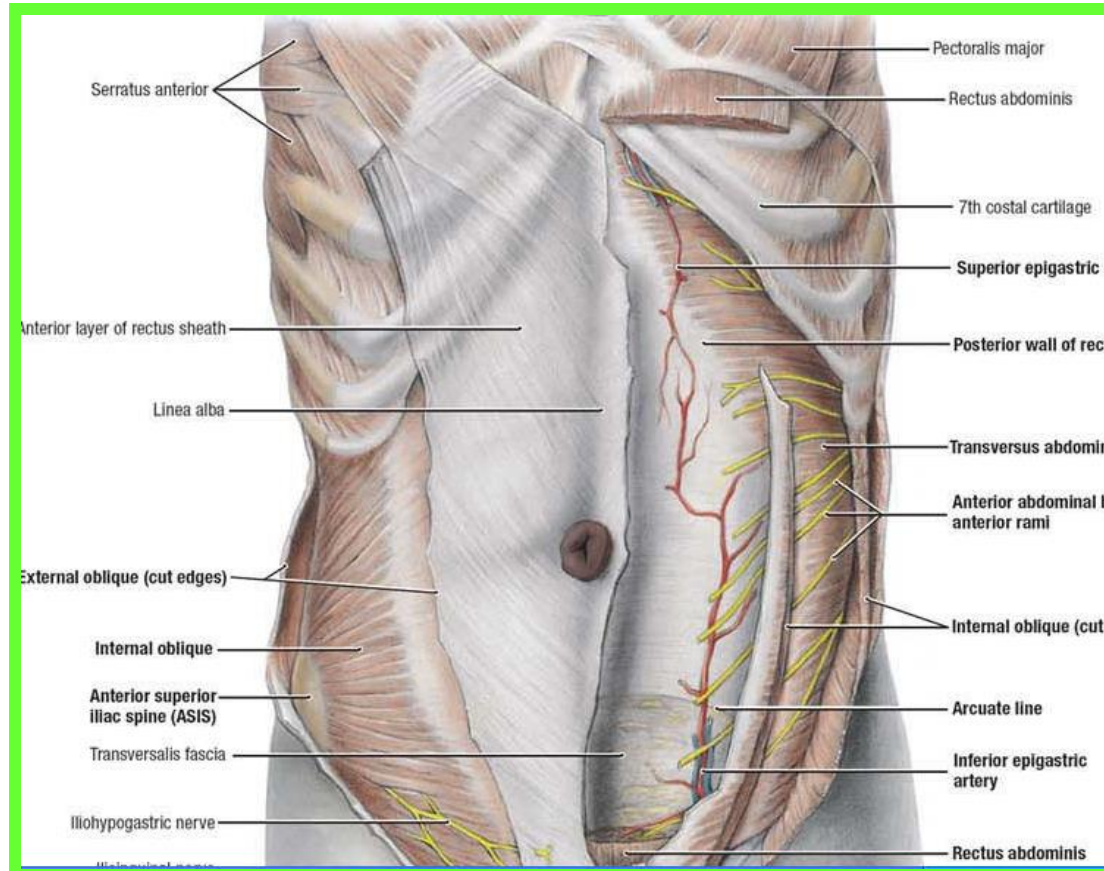
Internal Oblique Muscle

❖ The intermediate of the three flat abdominal muscles
❖ its fleshy fibers run perpendicular to those of the external oblique, running superomedially (like your fingers when the hand is placed over your chest).

❖ **Origin:** Thoracolumbar fascia, anterior two-thirds of iliac crest, and lateral half of inguinal ligament

❖ **Insertion:** Inferior borders of 10th-12th ribs, linea alba, and pecten pubis via conjoint tendon

Dr. Aiman Qais Al -Maathidy
Monday 9 March 2026



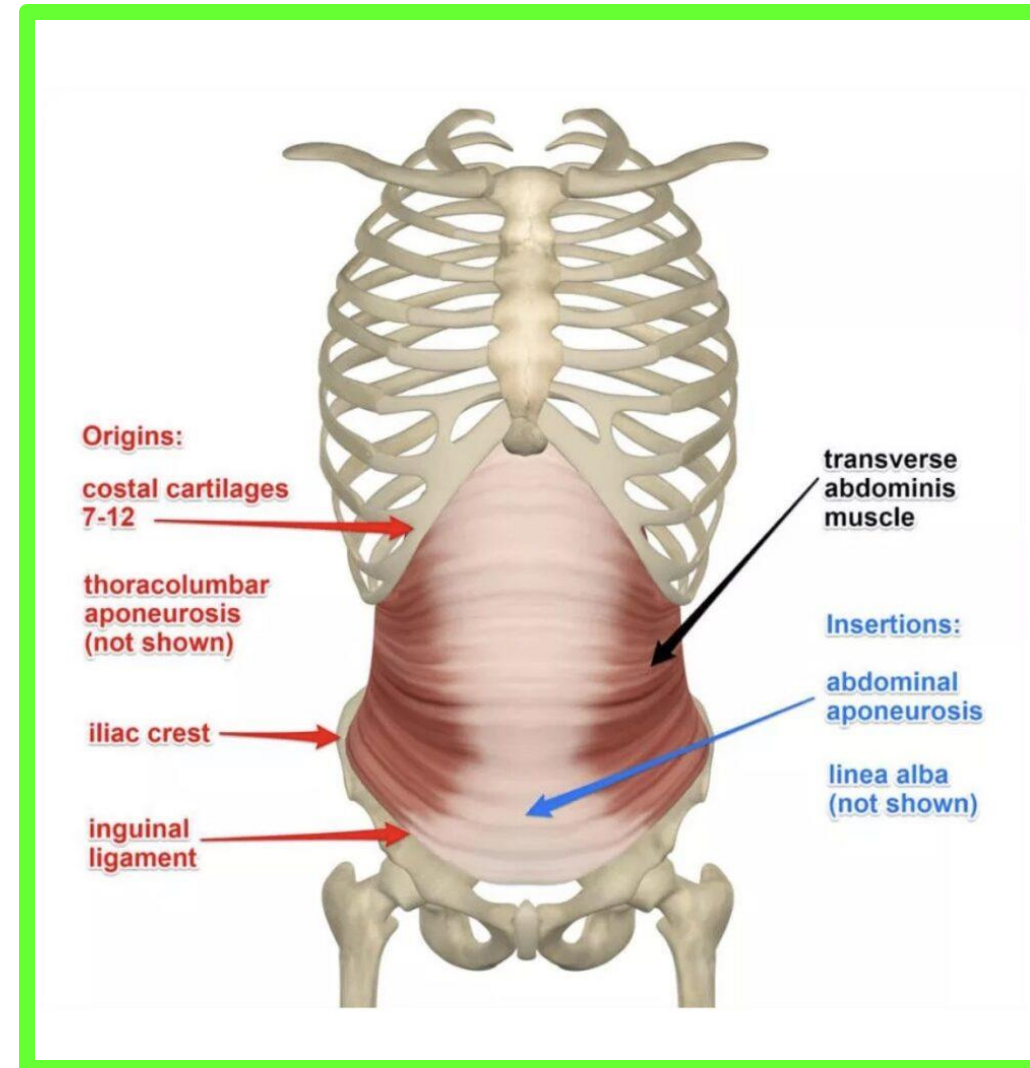
Transverse Abdominal Muscle

- ❖ The innermost of the three flat abdominal muscles
- ❖ Run more or less transversally, except for the inferior ones, which run parallel to those of the internal oblique.

- ❖ **Origin:** Internal surfaces of 7th-12th costal cartilages, Thoracolumbar fascia, iliac crest, and lateral third of inguinal ligament

- ❖ **Insertion:** Linea alba with aponeurosis of internal oblique, pubic crest, and pecten pubis via conjoint tendon

- ❖ Between the internal oblique and the transversus abdominis muscles is a **neurovascular plane**, which corresponds with a similar plane in the intercostal spaces.



Rectus Abdominis Muscle

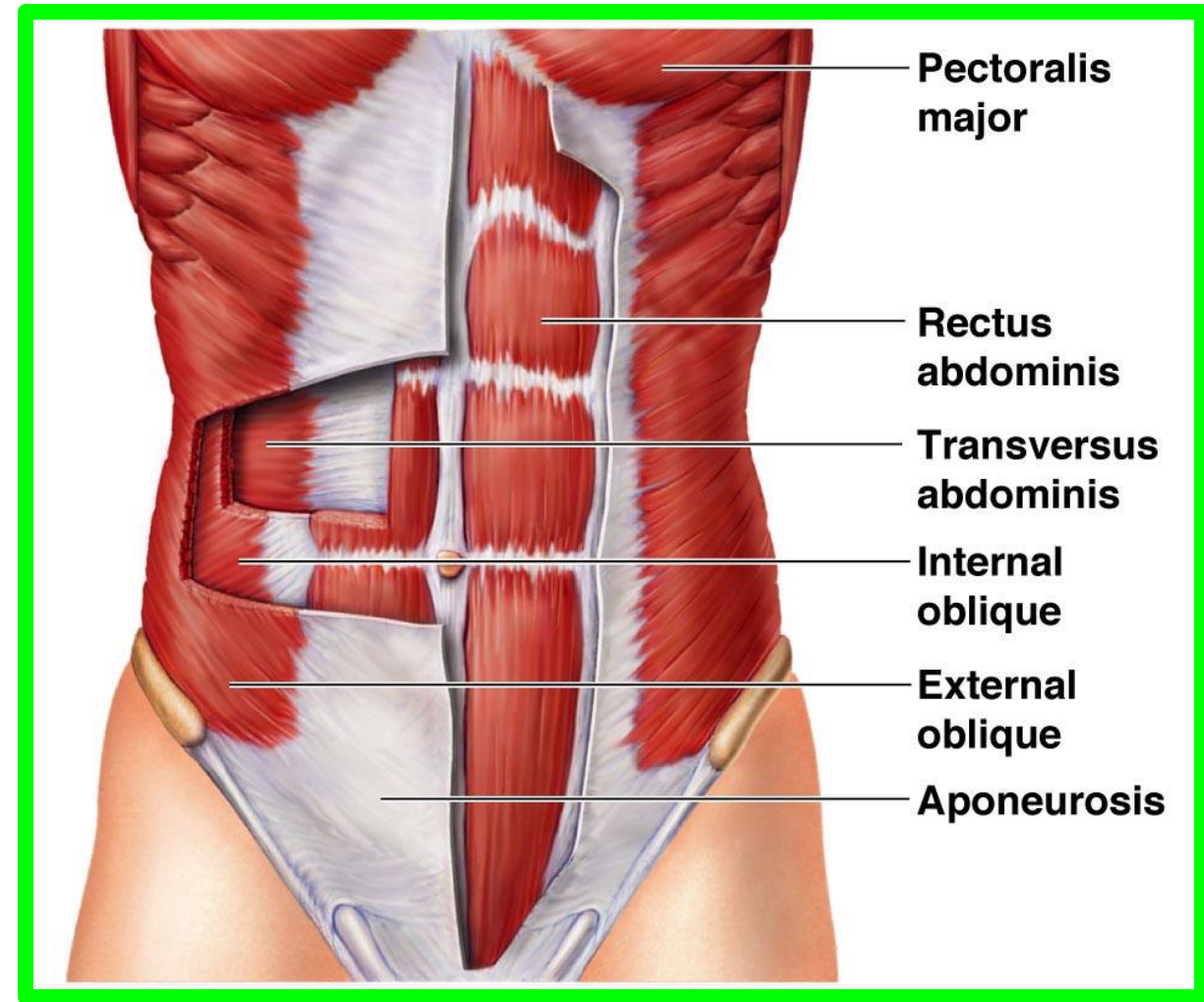
❑ Is the principal vertical muscle of the anterior abdominal wall

❑ long, broad, strap-like muscle

❑ The paired rectus muscles separated by **the linea alba**, lie close together inferiorly.

❑ The rectus abdominis is three times as wide superiorly as inferiorly

❑ The rectus muscle is anchored transversely by attachment **at three** or more **tendinous intersections**. These occur at the level of the **xiphoid process**, **umbilicus**, and **halfway between** these structures

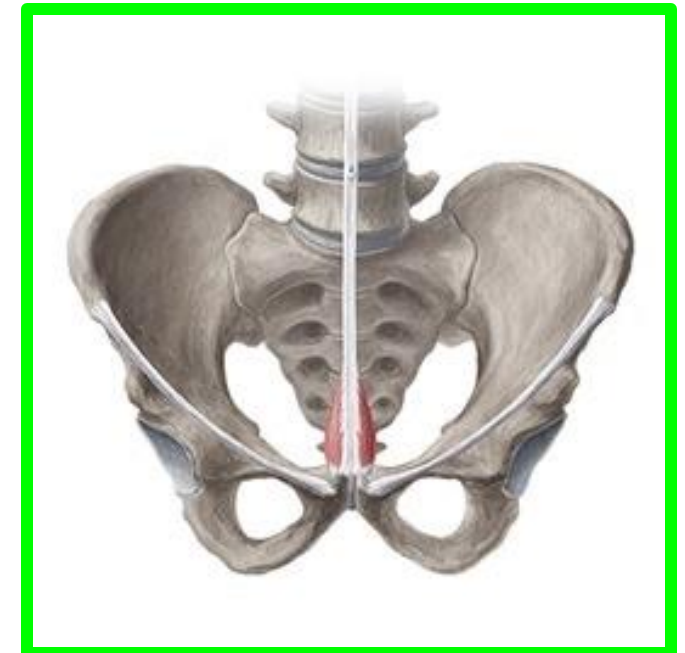
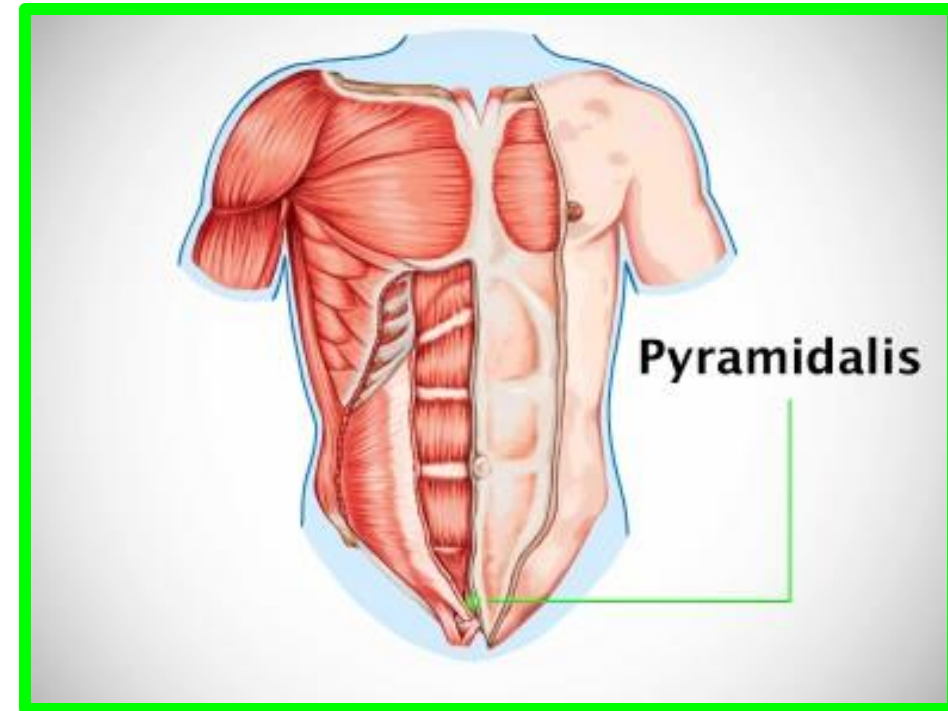


PYRAMIDALIS

The pyramidalis is a **small, insignificant triangular muscle** that is absent in approximately **20% of people**. It lies anterior to the inferior part of the rectus abdominis and attaches to the anterior surface of the pubis and the anterior pubic ligament.

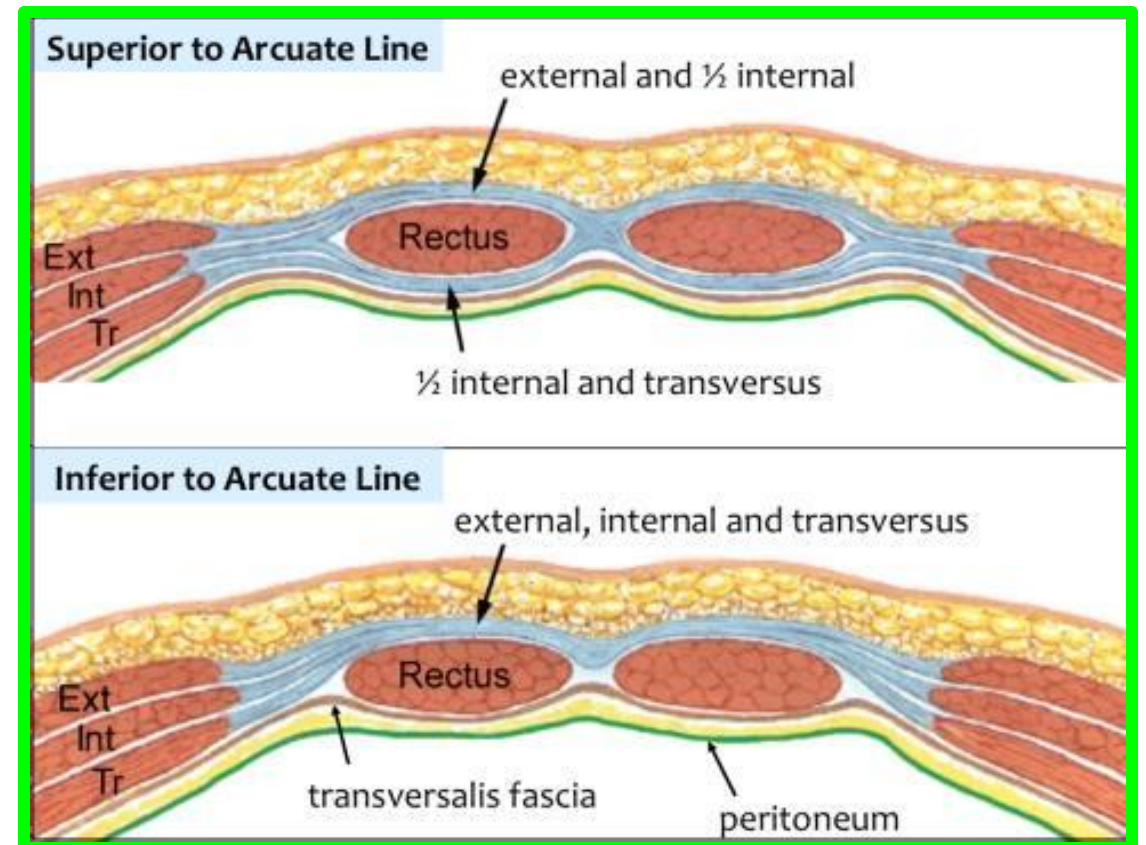
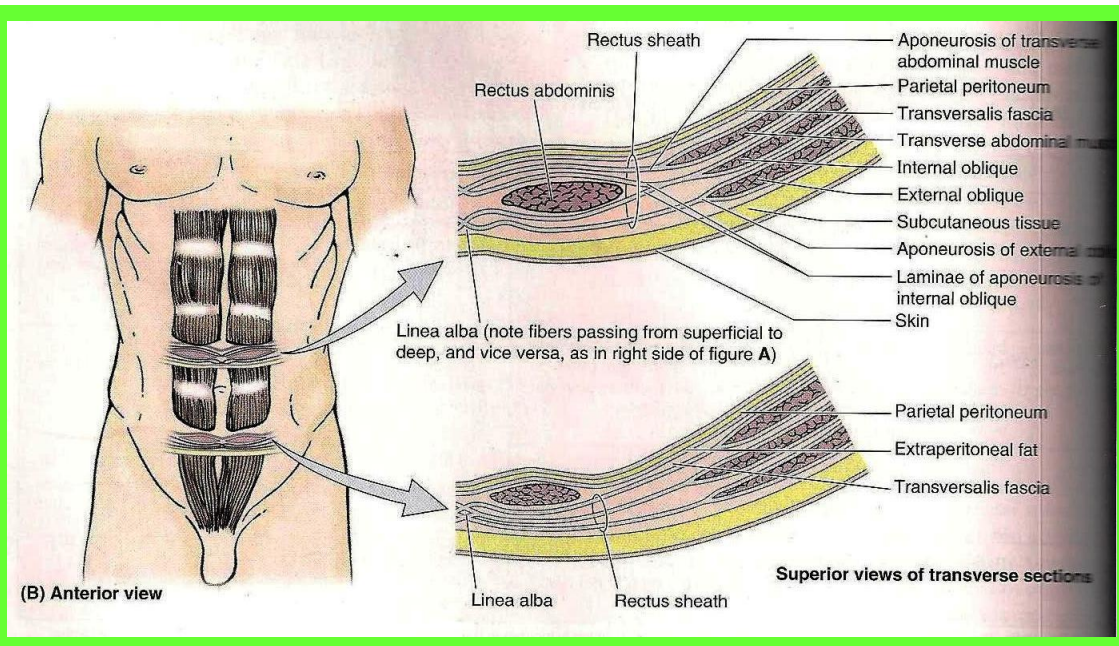
It ends in the linea alba, which is especially thickened for a variable distance superior to the pubic symphysis. The pyramidalis tenses the linea alba.

When present, surgeons use the attachment of the pyramidalis to the linea alba as a landmark for median abdominal incision



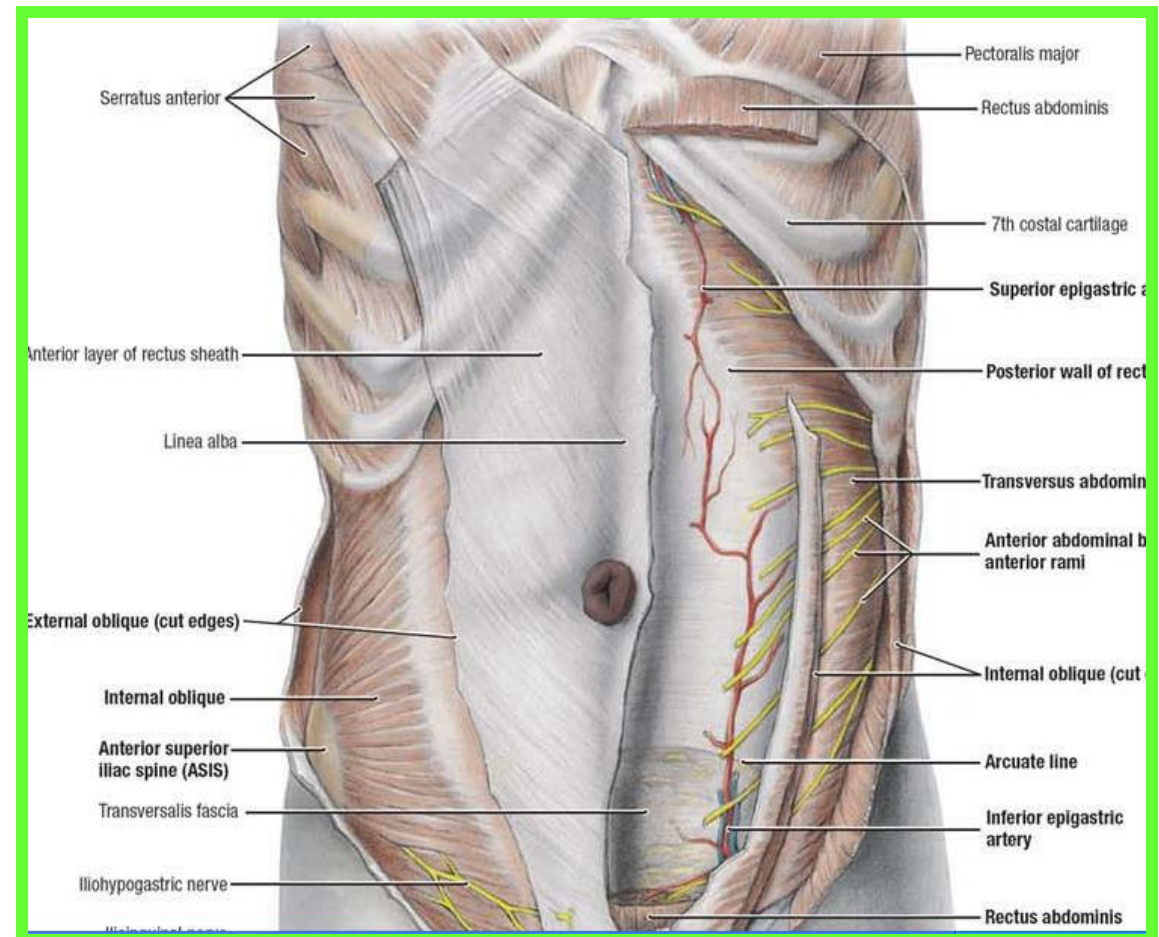
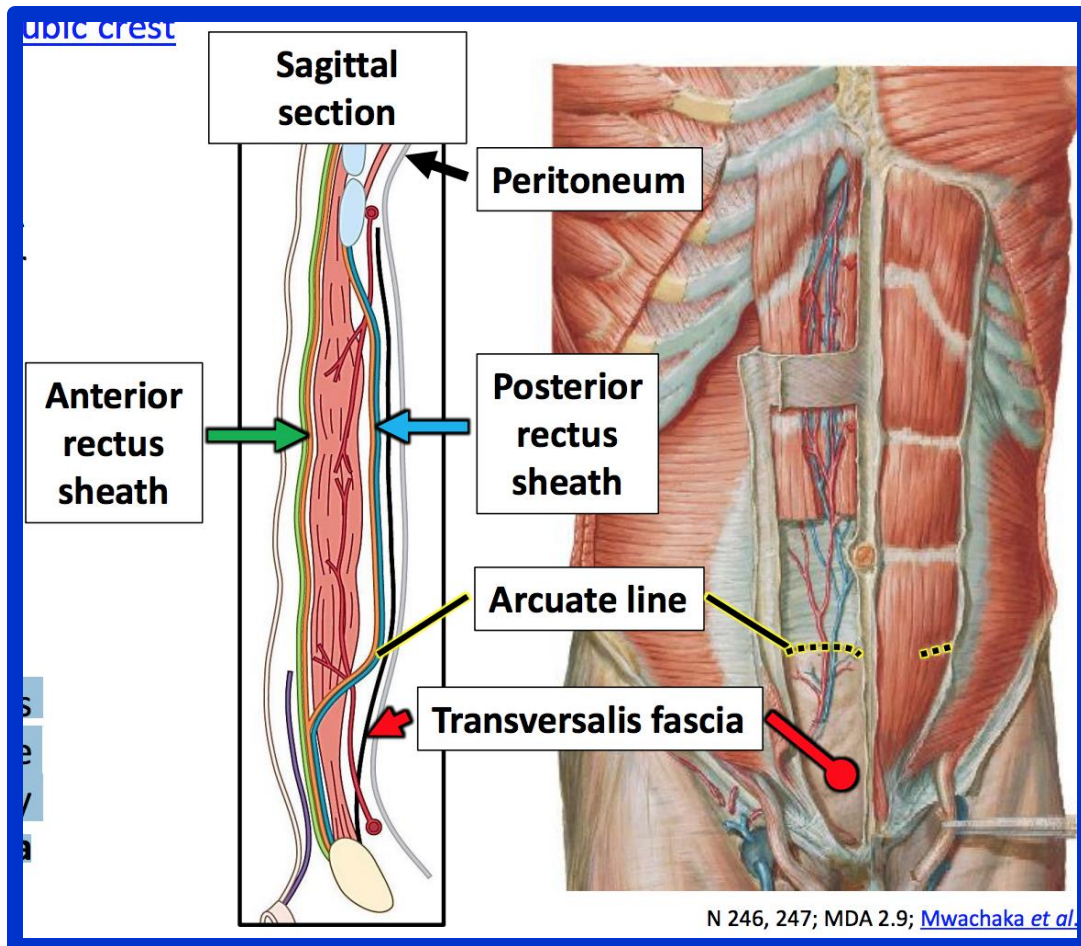
Rectus Sheath

- The aponeurosis of the internal abdominal m splits into anterior & posterior layers to enclose the rectus .
- The external oblique aponeurosis fuses with the anterior layer to form the anterior layer of the rectus sheath.
- The transverses aponeuroses fuses with the posterior layer to form the posterior layer of the rectus sheath



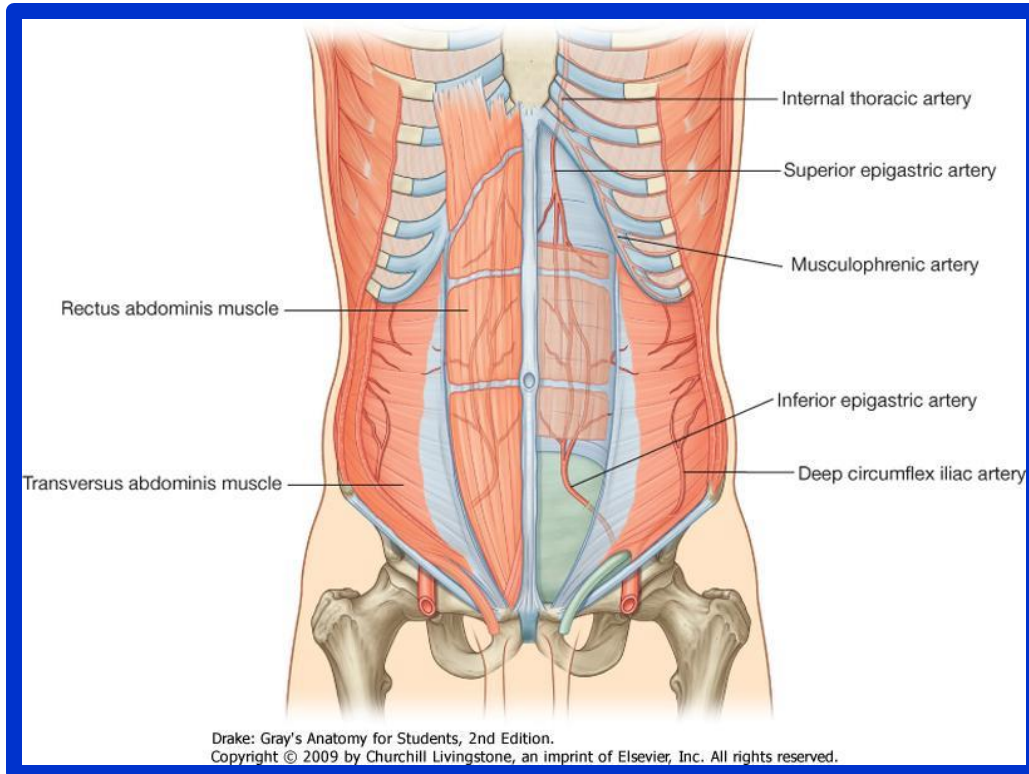
Dr. Aiman Qais Al -Maathidy
Monday 9 March 2026

From halfway between the umbilicus & pubic symphysis all three aponeuroses passes in front of the rectus m. leaving only relatively **thin transversalis fascia** to cover the **rectus abdominis posteriorly** demarcating **the arcuate line**.



Contents of the rectus sheath

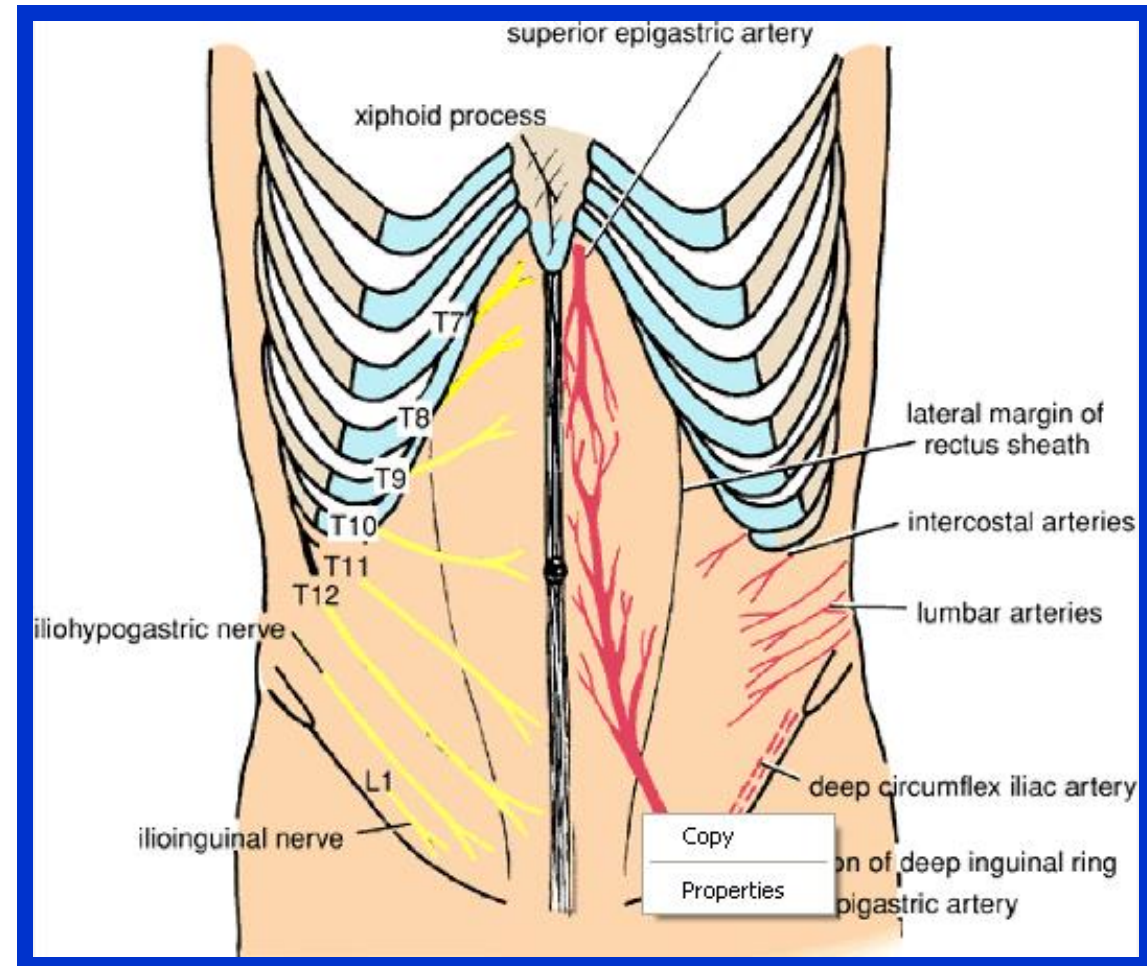
- ✓ The rectus muscle
- ✓ Pyramidalis muscle
- ✓ Intercostal nerves T 7 – T 11
- ✓ Superior & Inferior Epigastric vessels
- ✓ Lymphatic vessels



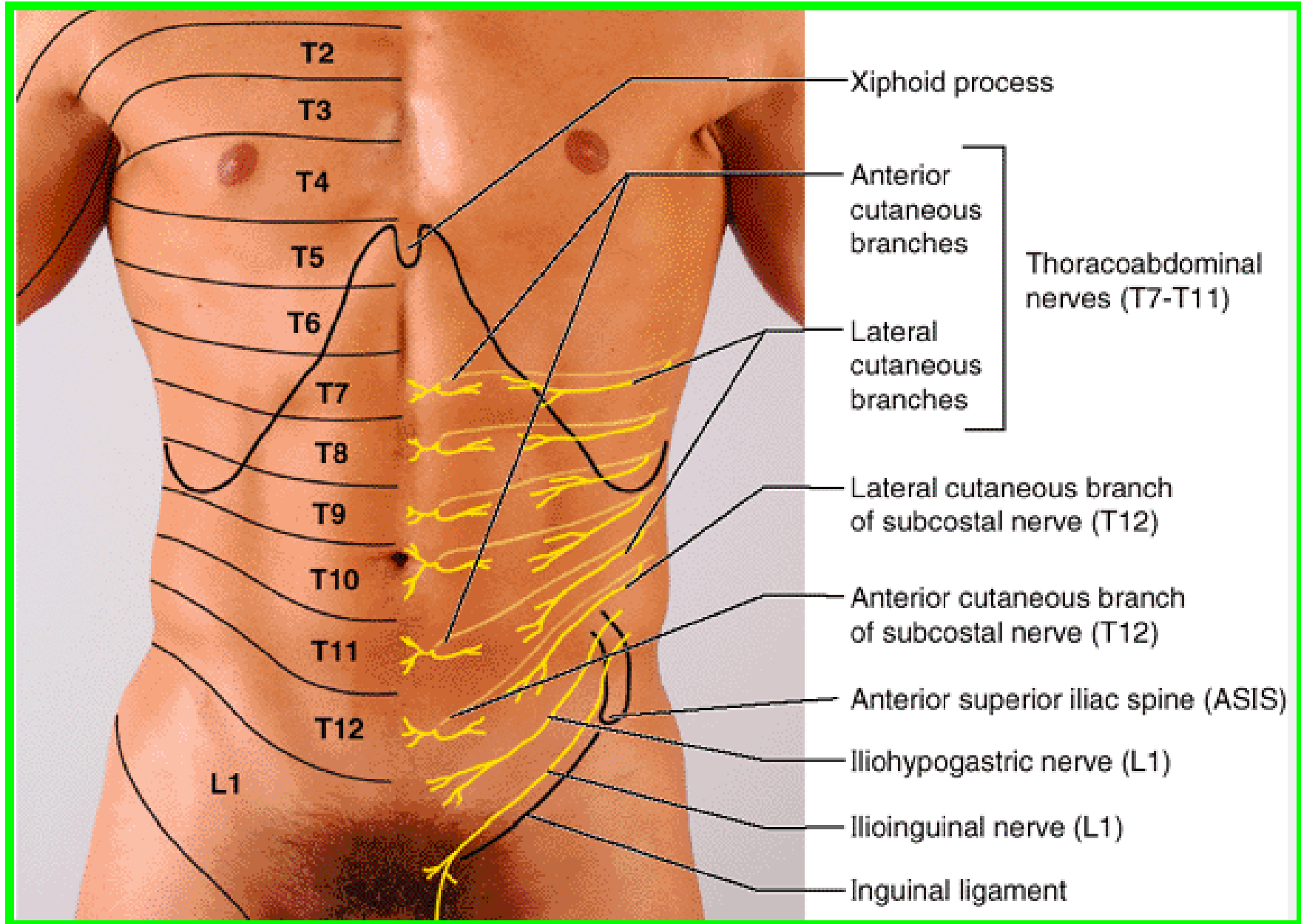
Dr. Aiman Qais Al-Maathidy

Monday 9 March 2026

15



Nerves of the Anterolateral Abdominal Wall



Dr. Aiman Qais Al -Maathidy

16

Monday 9 March 2026

Nerves of the Anterolateral Abdominal Wall

❖ **Thoracoabdominal nerves:** these are the distal, abdominal parts of the anterior rami of the inferior six thoracic spinal nerves (T7-T11); they are the former **inferior intercostal nerves** distal to the costal margin.

❖ **Lateral (thoracic) cutaneous branches:** of the thoracic spinal nerves T7-T9 or T10.

❖ **Subcostal nerve:** the large anterior ramus of spinal nerve T12.

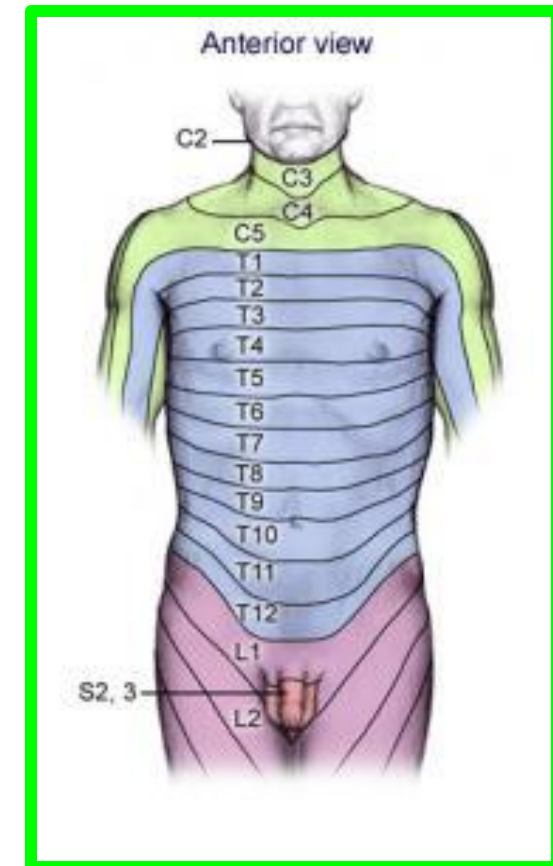
❖ **Iliohypogastric and ilioinguinal nerves:** terminal branches of the anterior ramus of spinal nerve L1.

Anterior abdominal cutaneous branches of thoracoabdominal nerves:

T7-T9 supply the skin superior to the umbilicus.

T10 supplies the skin around the umbilicus.

T11, plus the cutaneous branches of the subcostal (T12), iliohypogastric, and ilioinguinal (L1), supply the skin inferior to the umbilicus.



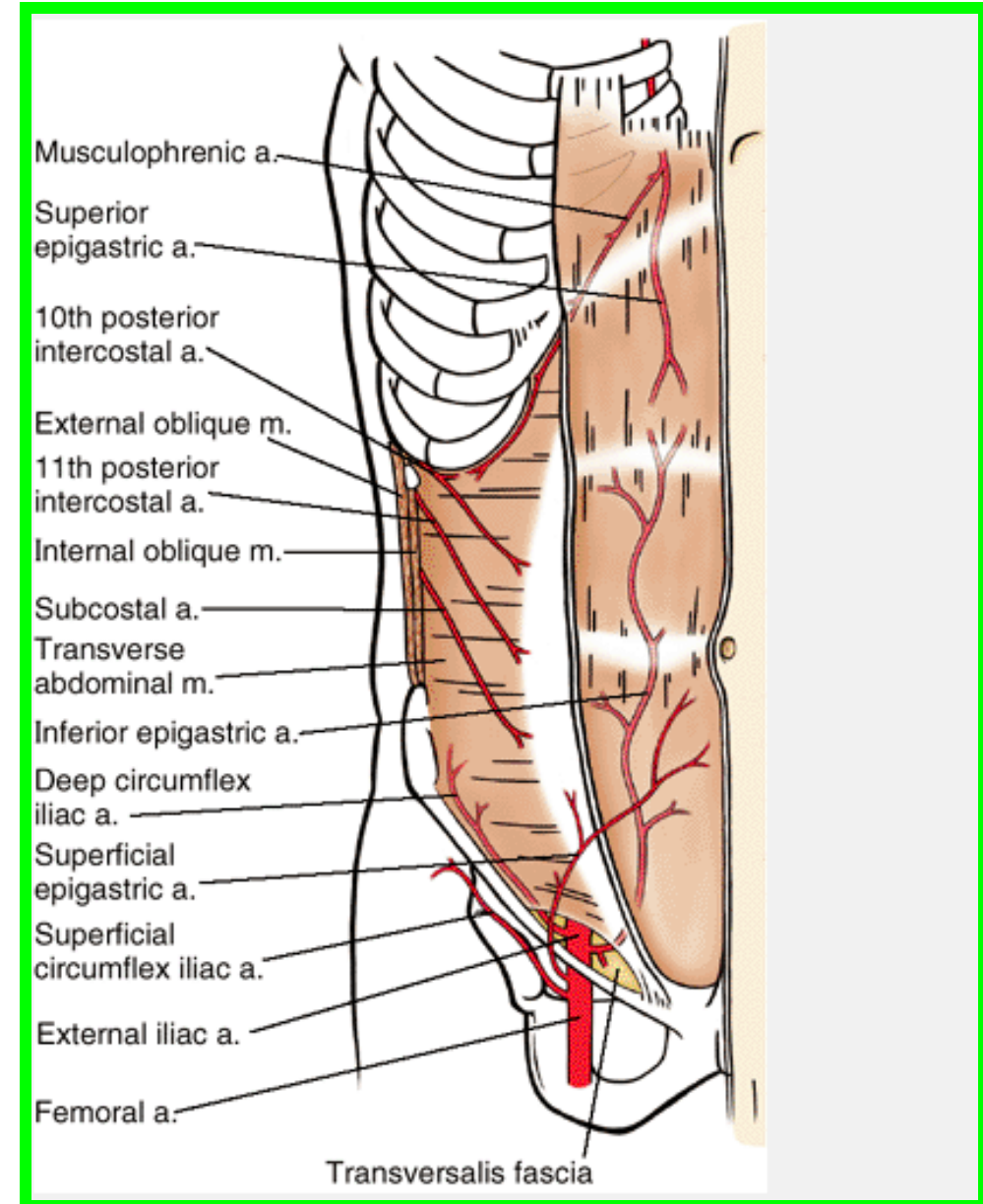
Arteries of the Anterolateral Abdominal Wall

- ❖ Superior epigastric artery
- ❖ Inferior epigastric artery

- ❖ Deep circumflex iliac
- ❖ Superficial circumflex iliac a.

- ❖ Superficial epigastric a.
- ❖ Subcostal artery a.

- ❖ Musculophrenic a.
- ❖ 10th and 11th posterior intercostal arteries



Veins of the Anterior Abdominal Wall

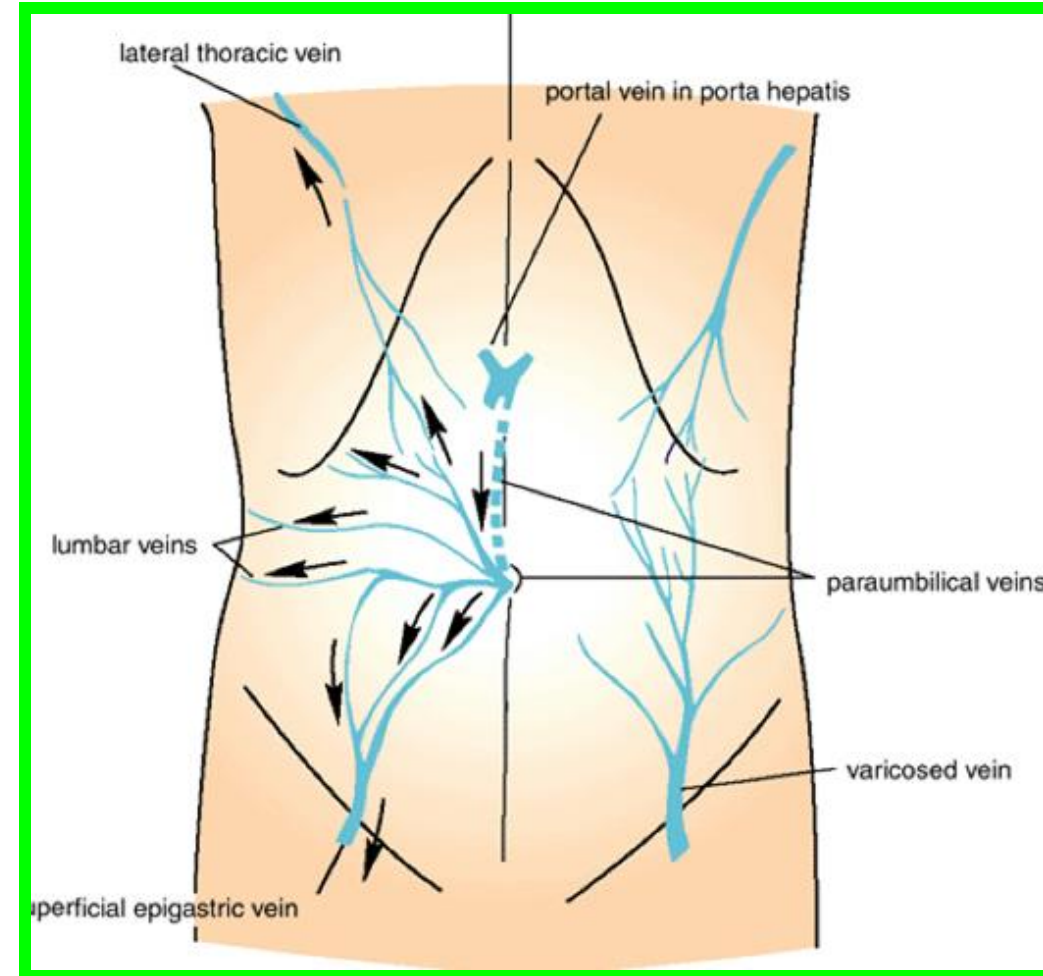
Dr. Aiman Qais Al -Maathidy
Monday 9 March 2026

Superficial Veins :

form a network that radiates out from the umbilicus

Above, the network is drained into the axillary vein via the lateral thoracic vein

below, into the femoral vein via the superficial epigastric and great saphenous veins



❖ The paraumbilical veins, connect the network through the umbilicus and along the ligamentum teres to the portal vein.

❖ This forms an important portal systemic venous anastomosis

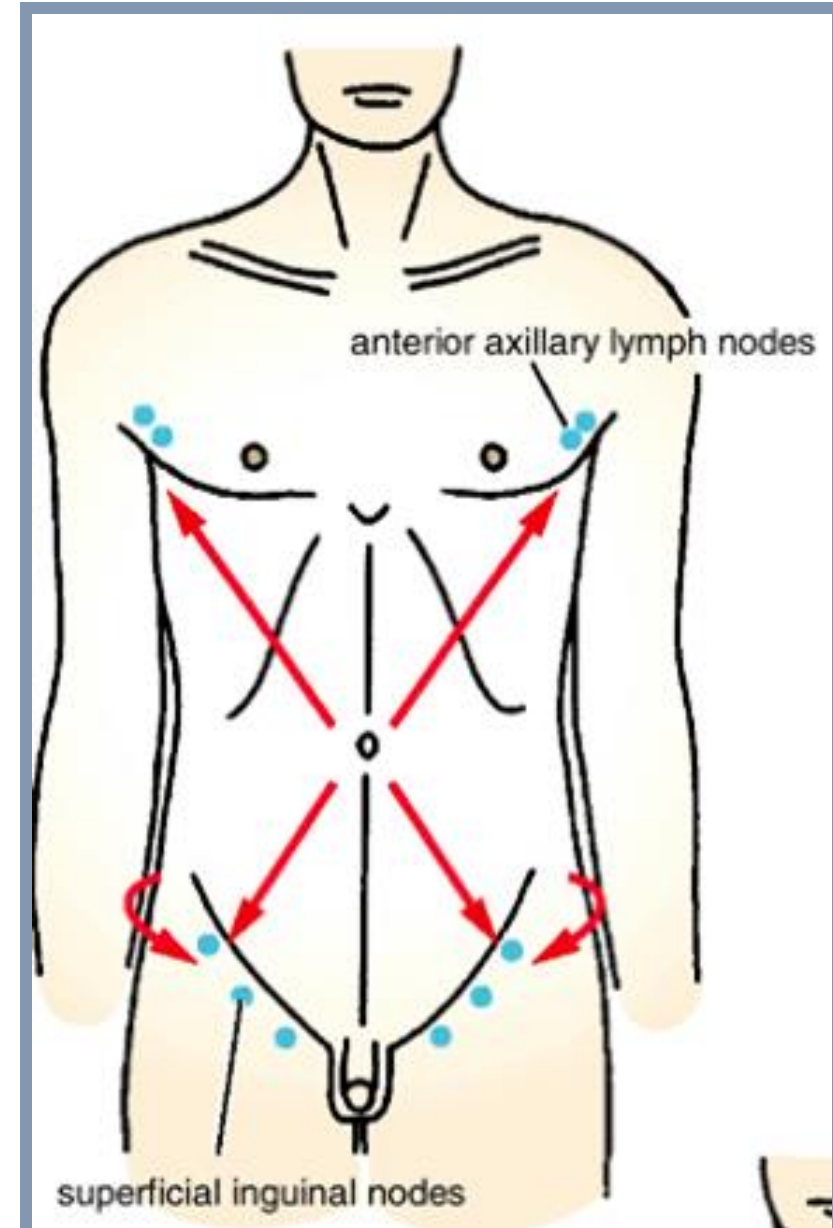
Lymph Drainage of the Anterior Abdominal Wall

Superficial Lymph Vessels

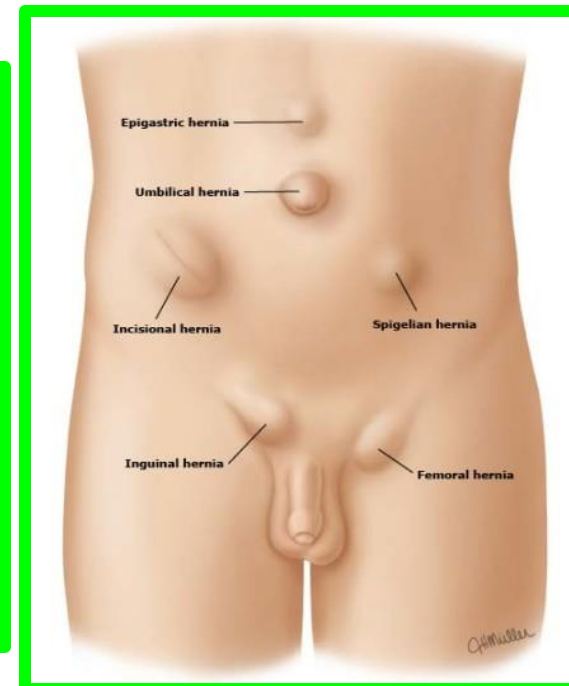
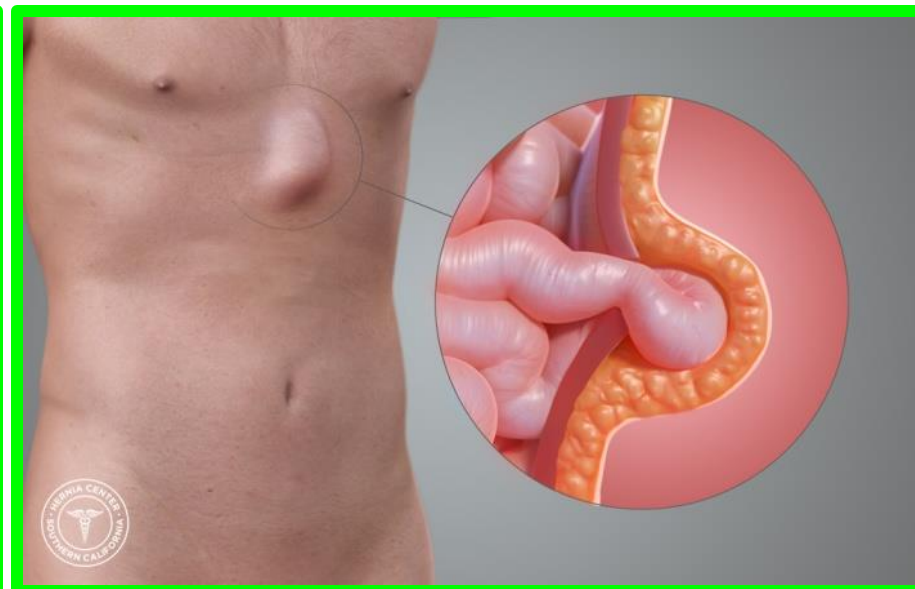
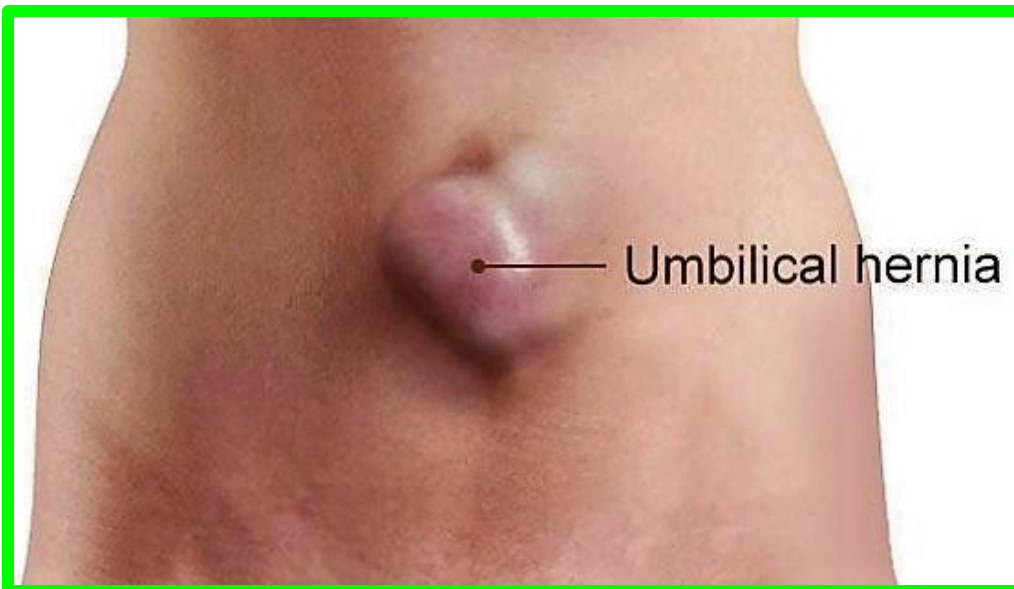- ❖ The lymph drainage of the skin of the anterior abdominal wall above the level of the umbilicus is upward to the anterior axillary (pectoral) group of nodes
- ❖ Below the level of the umbilicus, the lymph drains downward and laterally to the superficial inguinal nodes

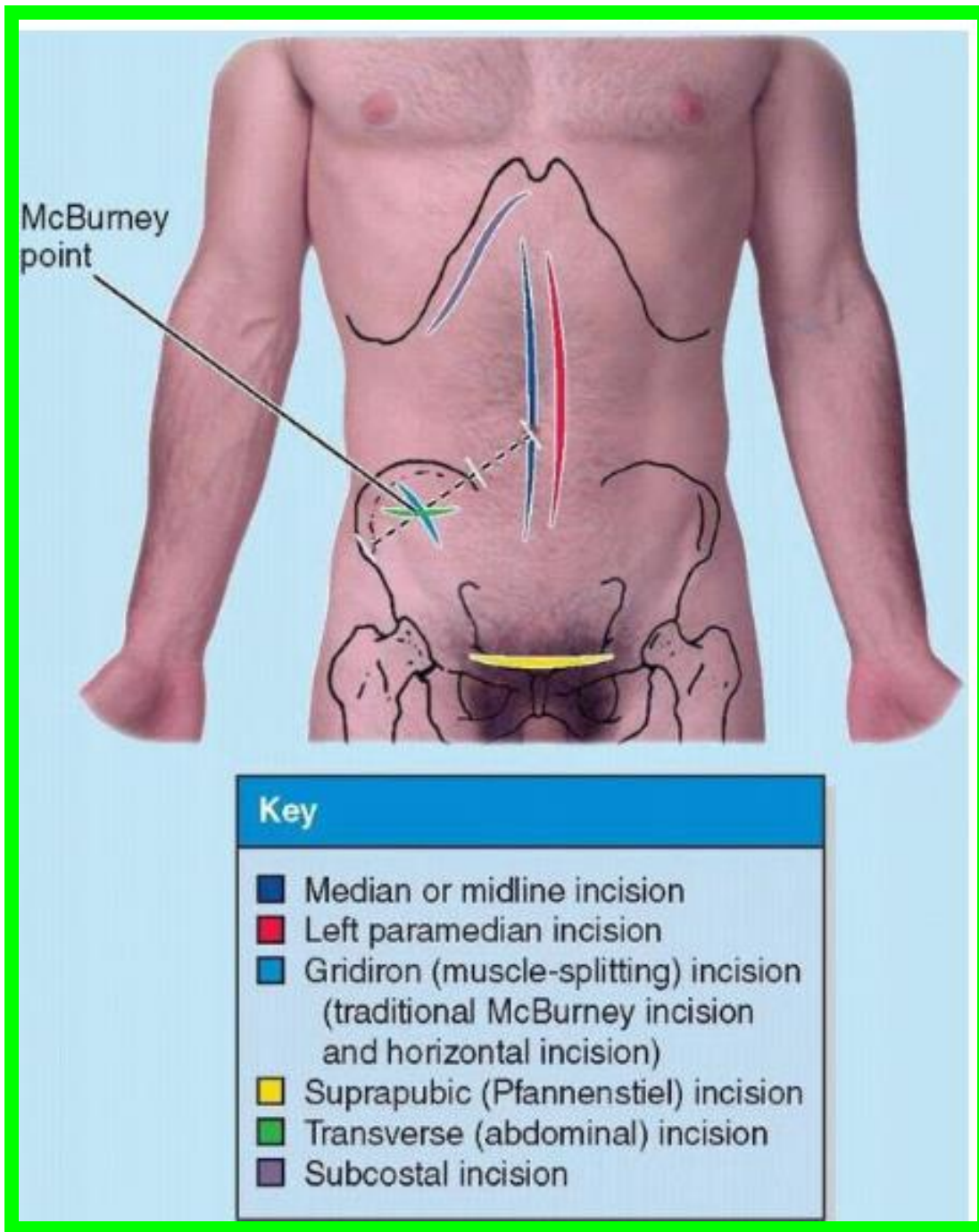
The deep lymph vessels

- ❖ They follow the arteries and drain into the internal thoracic, external iliac, posterior mediastinal, and para-aortic (lumbar) nodes



- ✓ Most hernias occur in the inguinal, umbilical, and epigastric regions
- ✓ **Umbilical hernias** are common in newborns because the anterior abdominal wall is relatively weak in the umbilical ring,
- ✓ **Acquired umbilical hernias** occur most commonly in women and obese people.
- ✓ **An epigastric hernia**, a hernia in the epigastric region through the linea alba, occurs in the midline between the xiphoid process and the umbilicus.
- ✓ **Spigelian hernias** are those occurring along the semilunar lines





Dr. Aiman Qais Al -Maathidy
Monday 9 March 2026

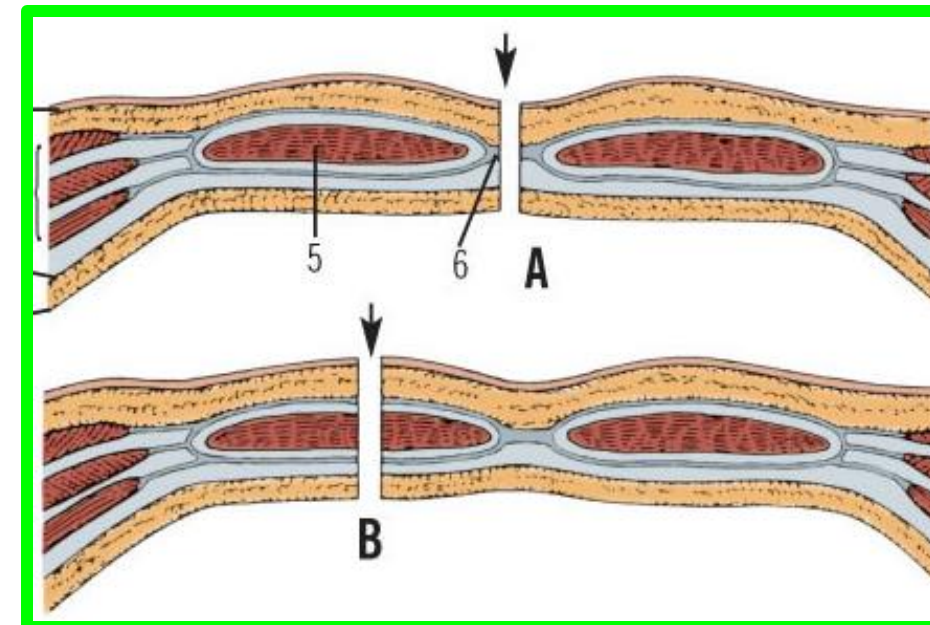
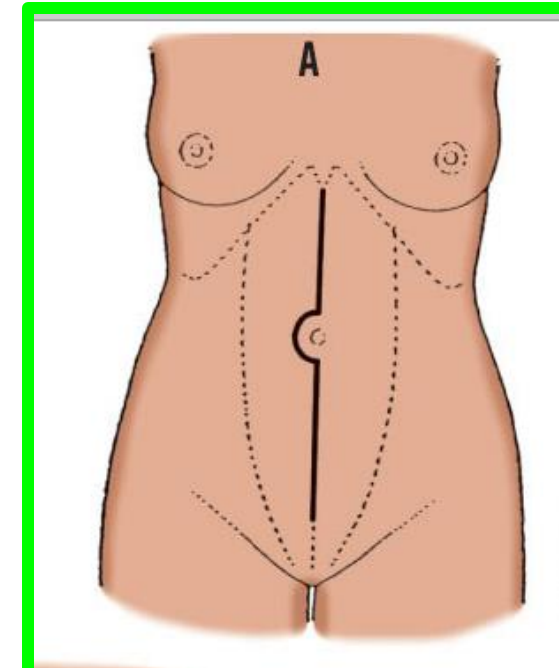
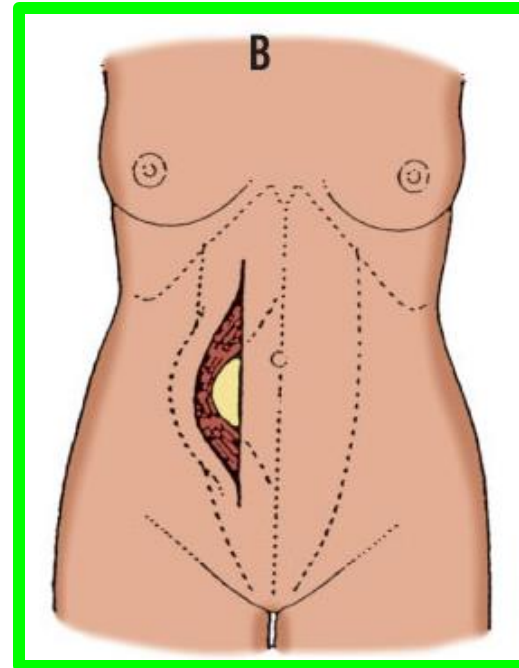
ABDOMINAL INCISIONS

MIDLINE INCISION

Is the simplest abdominal incision above or below the umbilicus passing through the **skin , subcutaneous tissue , the linea alba , transversalis fascia , extra peritoneal fat and the peritoneum** . No major blood vessels.

PARAMEDIAN INCISION

The anterior wall of the rectus sheath is incised vertically 2 cm from the midline and the rectus m. retracted laterally so that the posterior wall of the sheath is incised.



ABDOMINAL INCISIONS

Dr. Aiman Qais Al -Maathidy
Monday 9 March 2026

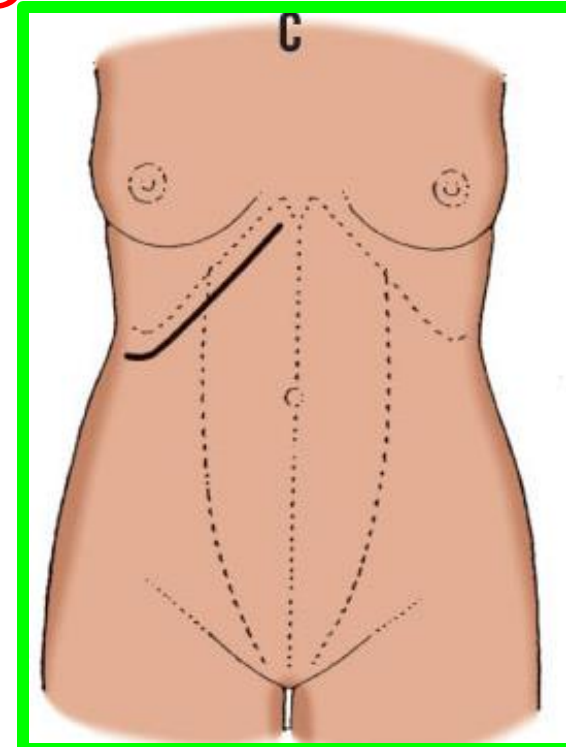
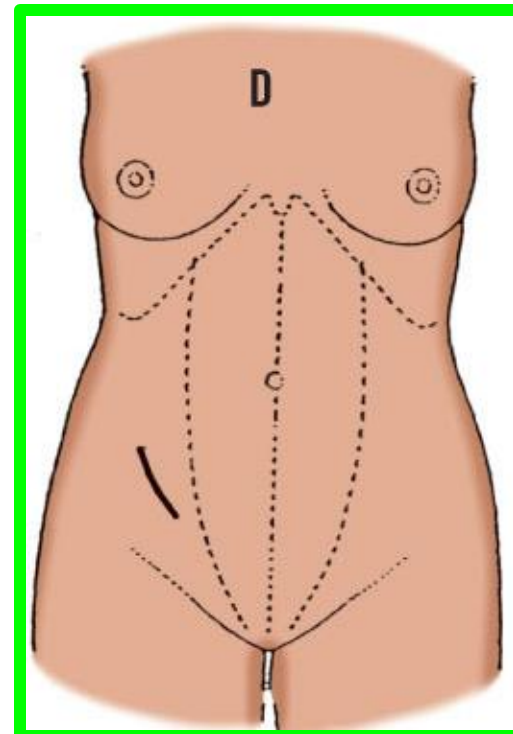
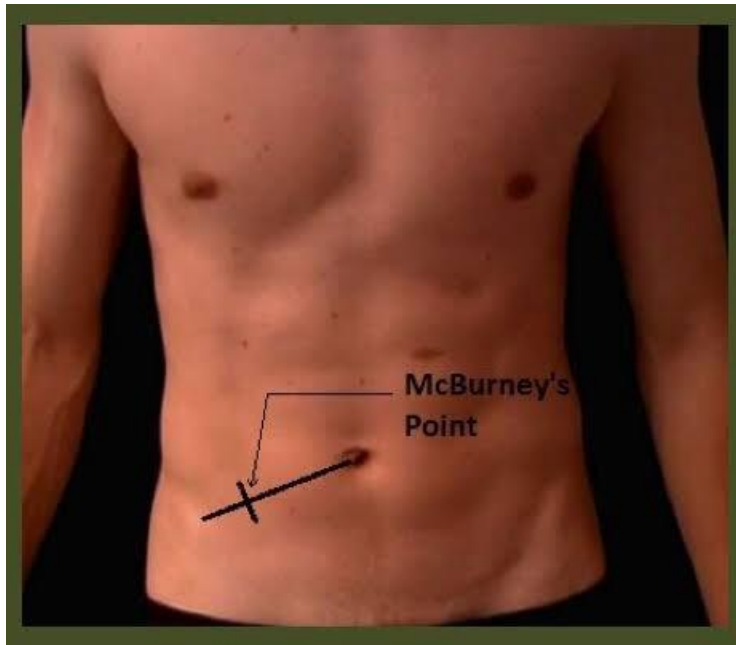
24

RIGHT SUBCOSTAL (KOCHER INCISION)

Is made 3 cm parallel to & below the right costal margin from midline to beyond the lateral border of the rectus sheath.

MCBURNNEY'S GRID IRON INCISION

Is lower oblique muscle splitting incision long used for **appendicectomy**. The skin incision runs downward medially through **the junction of the outer & middle 1/3** of line drawn from the anterior superior iliac spine to the umbilicus.

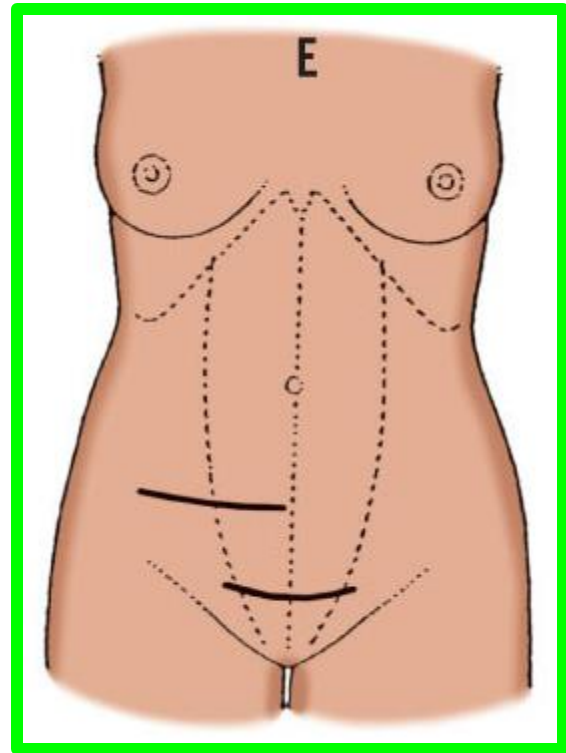


ABDOMINAL INCISIONS

PFANNENSTIEL'S INCISION

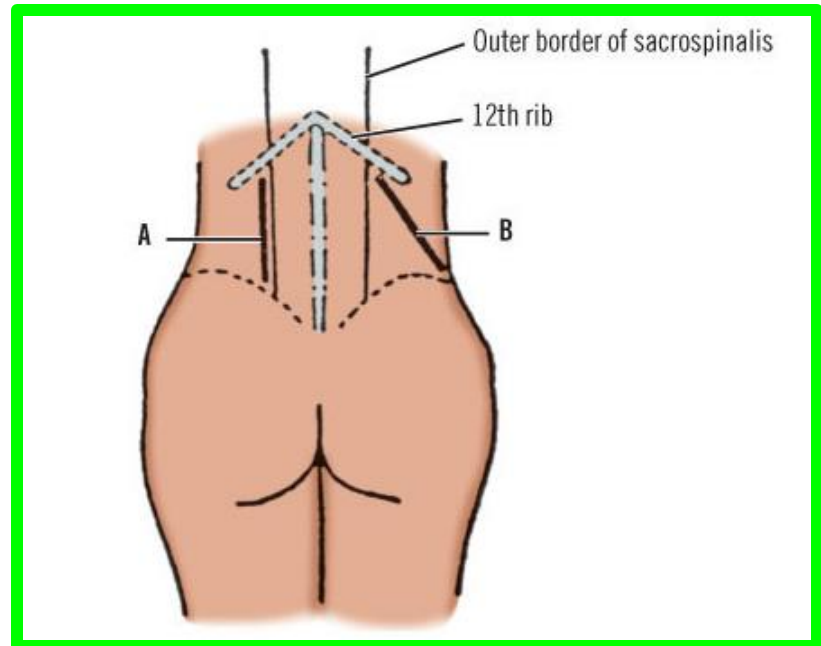
The lower transverse abdominal incisions commonly used for **approach to the pelvic organs**.

A skin crease incision is made above the symphysis pubis just below the hair line as far as the lateral border of the rectus sheath.



LUMBER INCISIONS :

used for **extra peritoneal approach** to the **kidney & upper ureter**. It extend below the 12 th rib from the lateral border of erector spinae toward the anterior superior iliac spine.



INCISIONAL HERNIA

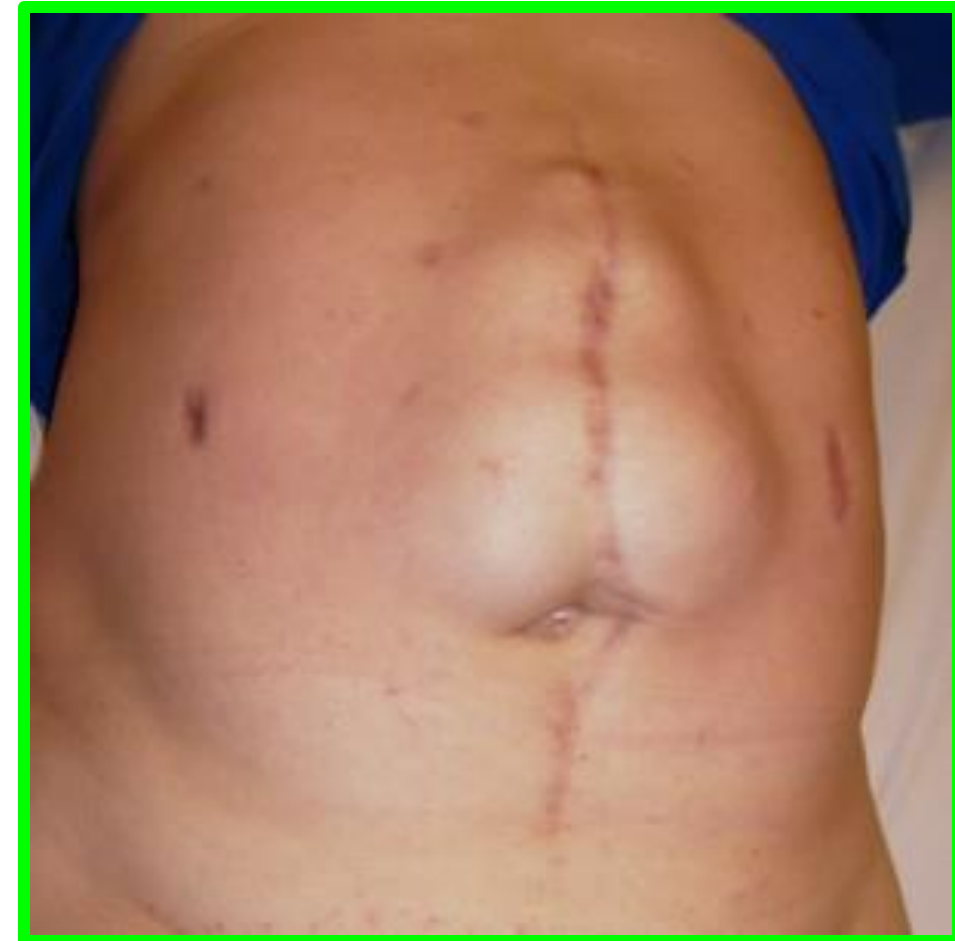An incisional hernia is a protrusion of omentum (a fold of peritoneum) or an organ **through a surgical incision**. If the muscular and aponeurotic layers of the abdomen do not heal properly, an incisional hernia can result.

HIGH-RISK INCISIONS

High-risk incisions include pararectus and inguinal incisions.

Pararectus incisions along the lateral border of the rectus sheath are undesirable because they **may cut the nerve supply to the rectus abdominis**.

Inguinal incisions for repairing hernias may injure **the ilioinguinal nerve**.



A lush green park with many large trees and people sitting on the grass. The scene is bright and sunny, with dappled light on the grass. In the foreground, there is a flower bed with red and pink flowers. A person is sitting on the grass near a large tree on the left. In the background, several other people are visible, some sitting on the grass and others walking. The trees are tall and have thick trunks, some with orange markings. The overall atmosphere is peaceful and pleasant.

Dr. Aiman Qais Afar
Surgical Anatomist
Monday 9 March 2026