

MSS-pathology

Archive

Lecture 2

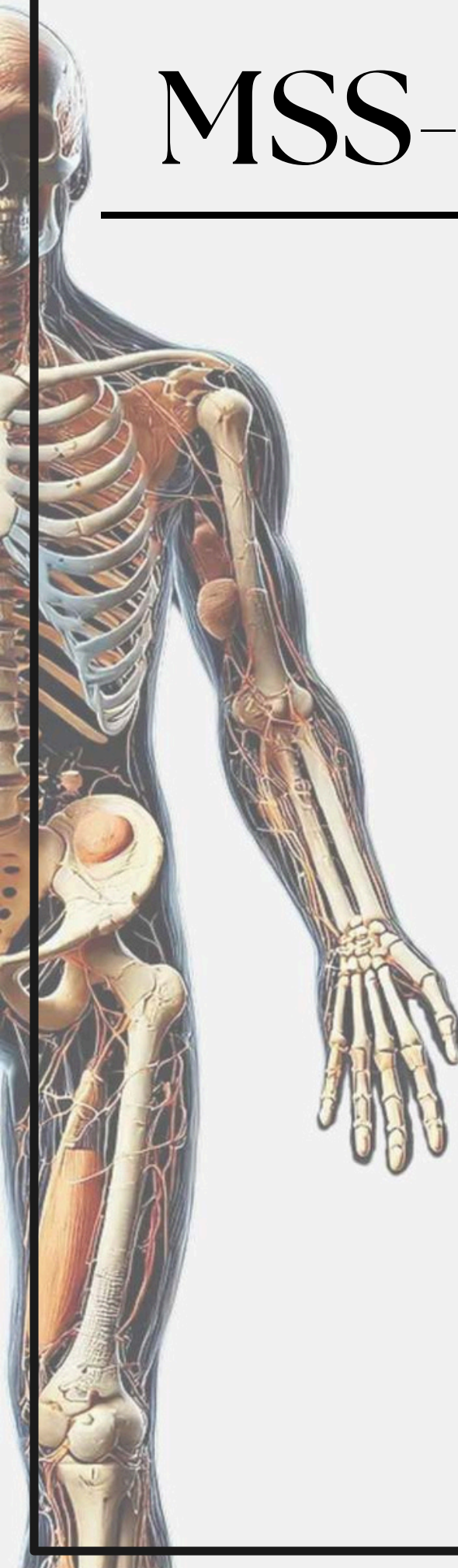
Chronic inflammatory
dermatoses and blistering
disease.

Done by :

Layan Riyadh

Corrected by :

Danea alabadi



pathology - lecture (2)

Nail changes due to :

- A) psoriasis
- B) rheumatoid arthritis

Answer:A

Civate body:

- A- necrotic basel cell
- B-necrotic detach of stratum corneum
- C-epidermal acantholysis

Answer:A

Lichen planus:

- A- CD8
- B- CD4
- C- both
- D- non of the following

Answer :A

-Which of the following pathological conditions of skin characterized by Wickhams' striae?

- A-Lichen simplex chronicus
- B-Atopic dermatitis
- C-Lichen planus
- D-Urticaria
- E-Eczema

Answer: C

-Which of the following statements about the morphology of psoriasis is incorrect?

- A-Acanthosis
- B-Extensive parakeratotic scale
- C-Loss of the stratum granulosum
- D-Increased epidermal cell turnover and maturation

Answer: D

pathology - lecture (2)

اللهم صل وسلم على سيدنا محمد صلى الله عليه وسلم

-The correct statement regarding psoriasis treatment is:

A-Administration Calcipotriol >100gm weekly can evoke hyperglycaemia

B-Tacrolimus can be applied in genitalia, face, and intertriginous areas

C-Tazarotene gel can be used during pregnancy in the treatment of psoriasis

D-Salicy acid is contraindicated in psoriasis

Answer: B

-All of the following are seen in psoriasis except:

A-Acanthosis

B-Loss of stratum granulosum

C-Mature Keratinocytes

D-Parakeratosis

Answer: C

-Keratohyalin granules are found in which layer of the epidermis? سؤال متعلق بمحاضرة 1+2

A-Stratum basale

B-Stratum Spinosum

C-Stratum granulosum

D-Stratum lucidum

E-Stratum corneum

Answer: C