

MSS - Anatomy

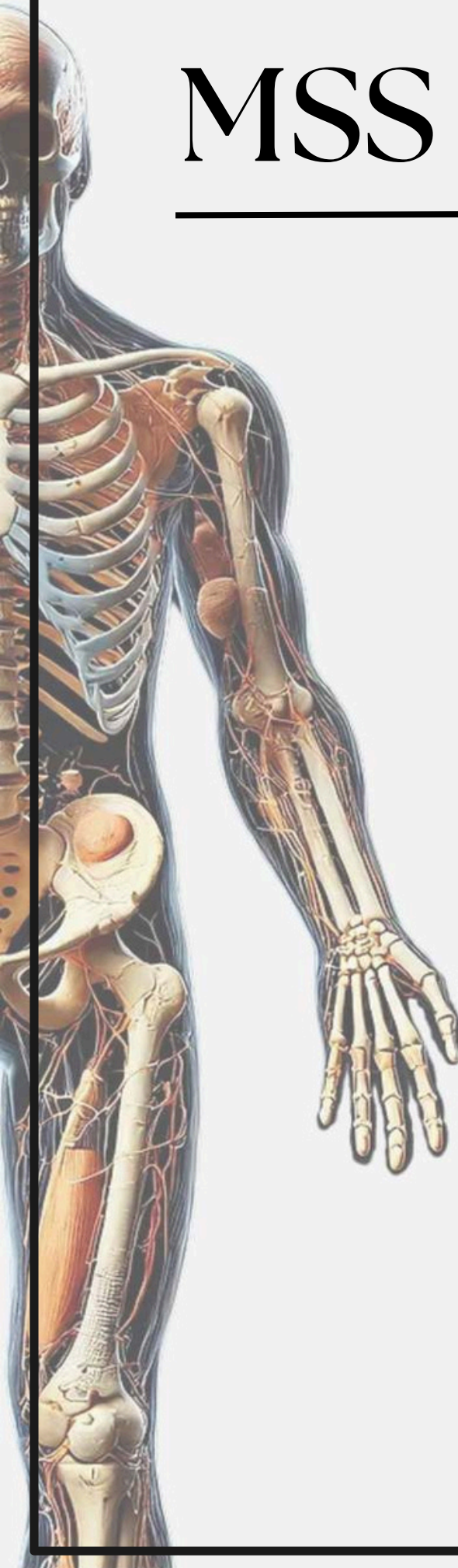
Archive

Lecture 2

Lecture's name

The Skull II

Corrected



Anatomy - lecture (2)

questions

1) Middle meningeal artery pass through :

- A. Foramen spinosum.
- B. Foramen lacerum.
- C. Foramen ovale.
- D. Carotid canal.
- E. Hypoglossal canal

Answer: A

2) Which nerve cross over sternomastiod:

- A. Great auricular nerve.
- B. Lesser occipital nerve.
- C. Transverse cervical nerve.
- D. Accessory nerve.
- E. Phrenic nerve.

Answer: C

3) The mandibular nerve pass through which foramen of the skull :

- A- Foramen spinosum.
- B- Foramen ovale.
- C- Stylomastoid foramen.
- D- Foramen lacerum.
- E- Jugular foramen.

Answer: B

Anatomy - lecture (2)

4) Which of the following is not part of the palatine bone?

- A. Greater palatine foramen
- B. Lesser palatine foramen
- C. Cribriform plate

Answer: C

5) Which of the following matches is incorrect?

- A. Middle Meningeal Artery >> Foramen Spinosum
- B. Maxillary Division of Trigeminal N >> Foramen Rotundum
- C. Facial N & Vestibulocochlear N >> Internal Acoustic
- D. Mandibular Division of the Trigeminal N >> Foramen lacerum
- E. Medulla oblongata >> Foramen magnum

Answer: D. Mandibular Division of the Trigeminal N >> Foramen lacerum

6) All of the following are components of hard plate except ?

- A. greater palatine n
- B. lesser palatine n
- C. horizontal plates of palatine bone
- D. palatal process of maxilla
- E. ethmoid bone