

Archive MSS

2025-2026

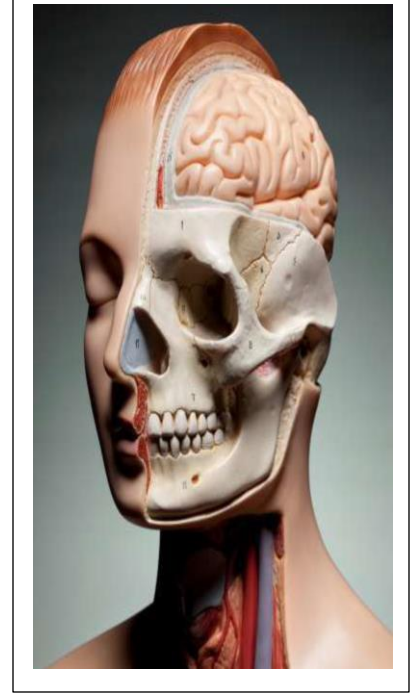
With EXPLANATION

Done by: Raghad Qasem

Medical student at MU

www.facebook.com/raghad.hqasem

<https://t.me/raghadqasem001>



أسلوب التدريب على المخرجات بطريقة فهم تفسيرات الخيارات المتعددة فعال جداً في استذكار المعلومات و هو الأسلوب المعتمد في التدريب على اسئلة امتحانات المعادلة الأمريكية يُنصح بالتدريب على المخرجات و أسلوب الاسئلة وتفسيرها يومياً بدلاً من تأجيلها لفترة ما قبل الاختبار ويرجى قراءة السؤال بتمعن مرتان وفهمه ثم التركيز على المطلوب عند اختيار الاجابة الدوسية لا تُغني عن دراسة المحاضرات وفهمها، لكنها مُكمّلة لها.. فمبدأ الدوسية هو إنقاذ ومراجعة محتوى المادة وهي مُدقّقة وشاملة لجميع اسئلة دفع السنوات السابقة / جامعة مؤتة خطوة التدريب على المخرجات مهمة جداً في العملية التعليمية، ليست الغاية بحفظ إجابات الاسئلة وقد لا تُكرر الاسئلة نفسها لكن تفيدك معلومة تم شرحها فيه وبهدف التدريب على طريقة التفكير بمحتوى منظومة الجهاز العضلي الهيكلي و التركيز على المواضيع المهمة التي تهتم دكاترة الكلية بمعرفتك لها كطبیب ومراجعتها وفهم تفسيرها والتدريب على الحالات العملية والتفاصيل الموجودة بالخيارات جميعها.. كل التوفيق يا رب

1) Which nerve cross over sternomastiod muscle?

- A. Great auricular nerve.
- B. Lesser occipital nerve.
- C. Transverse cervical nerve.
- D. Accessory nerve.
- E. Phrenic nerve.

➤ Explanation:

- A. *Great auricular nerve runs vertically across SCM but doesn't cross it horizontally like the transverse cervical nerve.*
- B. *Lesser occipital nerve runs along the posterior border of SCM, not across it.*
- C. *True/ Transverse cervical nerve (C2-C3) is a branch of the cervical plexus and provides sensory innervation to the anterior and lateral parts of the neck.*
- D. *Accessory nerve passes deep to SCM, not cross it superficially.*
- E. *Phrenic nerve runs deep along the anterior scalene muscle, far from the SCM.*

2) Middle meningeal artery pass through:

- A. Foramen spinosum.
- B. Foramen lacerum.
- C. Foramen ovale.
- D. Carotid canal.
- E. Hypoglossal canal.

➤ Explanation:

- A. *True, The middle meningeal artery, a branch of the maxillary artery, enters the cranial cavity through the foramen spinosum. It supplies the dura mater and the inner table of the skull, and it is clinically significant because it is commonly involved in epidural hematoma when injured.*
- B. *Foramen lacerum is largely filled with cartilage in life, and no major artery passes through it.*
- C. *Foramen ovale transmits the mandibular nerve (V3), accessory meningeal artery, lesser petrosal nerve, and emissary veins.*
- D. *Carotid canal transmits the internal carotid artery.*
- E. *Hypoglossal canal transmits the hypoglossal nerve (CN XII).*

3) Ullrich congenital muscular dystrophy gene mutation:

- A. COL6A4
- B. COL6A1
- C. COL4A1
- D. COL4A3
- E. COL2A1

➤ Explanation:

- A. *COL6A4 gene doesn't exist or isn't associated with UCMD.*
- B. *True, UCMD is caused by mutations in the COL6A1, COL6A2, and COL6A3 genes, which encode collagen type VI, which is crucial for maintaining the structural integrity of muscle cells and the extracellular matrix.*

C. COL4A3 gene encodes collagen type IV, which is involved in basement membranes, and is associated with small-vessel disease, porencephaly, and brain hemorrhages, not UCMD.

D. COL4A3 gene encodes collagen type IV, which is associated with Alport syndrome, not muscular dystrophy.

E. COL2A1 gene encodes collagen type II, which is involved in cartilage development and is associated with chondrodysplasias and Stickler syndrome, not UCMD.

4) One of the following is not true regards elastin and collagen:

A. Both are major components of skin tissue.

B. Both contain hydroxyapatite.

C. Both can be crosslinked covalently.

D. Both are glycosylated.

E. Both are rich in glycine and proline.

➤ Explanation:

A. Collagen provides tensile strength, but elastin provides elasticity.

B. True, Hydroxyapatite is a calcium phosphate mineral primarily found in bone and teeth, not in elastin or collagen.

C. Collagen is crosslinked by lysyl oxidase to form stable fibril, but elastin is crosslinked desmosine and isodesmosine to provide elasticity.

D. Collagen is heavily glycosylated (hydroxylysine residues). However, elastin has some glycosylation, but to a lesser extent.

E. Collagen has a repeating Gly-X-Y sequence (X/Y often proline or hydroxyproline). However, elastin is also rich in glycine, proline and valine which contribute to its elastic properties.

5) Enthesitis is:

A. Inflammation in tendon.

B. Inflammation in joint.

C. Inflammation in eye.

D. Inflammation in muscle.

E. Inflammation in skin.

➤ Explanation:

A. True. Enthesitis refers to inflammation at the enthesis, which is the site where tendons, ligaments or joint capsules that attached to bone.

B. Arthritis is the inflammation of joints.

C. Uveitis or conjunctivitis is the inflammation of eye.

D. Myositis is the inflammation of muscle.

E. Dermatitis is the inflammation of skin.

6) All of the following is treatment for RA except:

A. Methotrexate.

B. Cyclosporine.

C. Paracetamol.

D. Colchicine.

E. Hydroxychloroquine.

➤ Explanation:

- A. Methotrexate is a first-line treatment for rheumatoid arthritis.
- B. Cyclosporine is occasionally used in severe cases of RA.
- C. Paracetamol can provide pain relief in mild cases but it doesn't reduce inflammation in RA, it's not a primary treatment for RA.
- D. True, Colchicine is used for gout, not RA. Colchicine inhibits microtubule function and is effective for acute gout attacks.
- E. Hydroxychloroquine is used in mild cases or as a part of combination therapy.

7) A patient underwent an organ transplantation, and after operation he began taking azathioprine to prevent organ rejection. Shortly after, he was diagnosed with gout. Which of these gout medication is forbidden for him to take:

- A. Allopurinol.
- B. Probenecid.
- C. Colchicine.
- D. Pegloticase.
- E. Corticosteroids.

A. Correct, The patient is taking azathioprine, an immunosuppressant used to prevent organ rejection after transplantation.

- * Allopurinol is a xanthine oxidase inhibitor used to lower uric acid levels in gout.
- * Azathioprine is metabolized into its active form 6-mercaptopurine (6-MP), which is broken down by xanthine oxidase.
- * Allopurinol inhibits xanthine oxidase, leading to toxic accumulation of 6MP, which can cause severe bone marrow suppression and pancytopenia.

➤ Explanation:

- B. Probenecid is safe; increases uric acid excretion via kidneys.
- C. Colchicine is safe; used for acute gout attacks.
- D. Pegloticase is safe; breaks down uric acid into a more soluble form.
- E. Corticosteroids is safe; used for acute gout in patients with renal impairment or contraindications to NSAIDs.

8) Which type of collagen the pericardium consists of:

- A. Type I.
- B. Type II.
- C. Type III.
- D. Type IV.

A. True/ * The pericardium consists primarily of Type I collagen, which is the major structural collagen found in fibrous tissues.

- * Type I collagen is the most abundant collagen in the human body and provides strength and tensile resistance.
- * The fibrous pericardium (outer layer) is composed mainly of dense connective tissue, rich in Type I collagen.
- * Type III collagen (also known as reticular fibers) is found in association with Type I collagen, but it is not the dominant type in the pericardium.

➤ Explanation:

- B. Type II collagen is found in cartilage, not in the Pericardium.
- C. Type III collagen is found in blood vessels and reticular fibers, but not the main type in the pericardium.
- D. Type IV collagen found in basement membranes, not in the pericardium.

9) Which bacteria of the following is coagulase negative and has sexual activity:

- A. Staphylococcus epidermidis.
- B. Staphylococcus saprophyticus.
- C. Staphylococcus aureus.
- D. Streptococcus pyogenes.
- E. Propionibacterium acne.

B. True/ * Staphylococcus saprophyticus is a coagulase-negative Staphylococcus (CoNS).

- * It is associated with sexual activity, as it is a common cause of urinary tract infections (UTIs) in sexually active young women.
- * It has a strong ability to adhere to the uroepithelium, leading to cystitis (bladder infection).

➤ *Explanation:*

- A. *Staphylococcus epidermidis* is coagulase-negative but mainly causes hospital-acquired infections (eg. Prosthetic device infections).
- C. *Staphylococcus aureus* is a coagulase positive bacteria.
- D. *Streptococcus pyogenes* causes pharyngitis, cellulitis, and rheumatic fever, not linked to sexual activity.
- E. *Propionibacterium acne* causes acne, not related to UTIs or sexual activity.

10) All of the following is an insertion of temporalis muscle except:

- A. Tip of coronoid process.
- B. Anterior border of coronoid process.
- C. Posterior border of coronoid process.
- D. Inner surface of coronoid process.
- E. Outer surface of coronoid process.

➤ *Explanation:*

- A. The temporalis muscle inserts on the tip of the coronoid process.
- B. This is another point of insertion of temporalis muscle.
- C. The temporalis muscle also inserts on the posterior border of coronoid process.
- D. Correct, The temporalis muscle inserts on the coronoid process of the mandible, specifically the anterior and outer surfaces of the coronoid process, and the tip of the coronoid process. It plays a key role in elevating the mandible for chewing.
- E. The temporalis muscle attaches here too.

11) In which layer of muscle of the back is the spinalis muscle?

- A. Superficial extrinsic.
- B. Superficial intrinsic.
- C. Intermediate extrinsic.
- D. Deep intrinsic.

D. Correct, The spinalis muscle is part of the erector spinae group, which is a deep intrinsic muscle of the back. The erector spinae muscles are responsible for extending and laterally flexing the spine.

➤ *Explanation:*

- A. Extrinsic muscles of the back are involved in movements of the upper limbs and ribs, not intrinsic spinal movement.
- B. The superficial intrinsic muscles include muscles like the latissimus dorsi, but the spinalis is deeper.
- C. Extrinsic muscles are more superficial, and the spinalis is intrinsic.

12) One of the following structure is deeper than platysma:

- A. External jugular vein.
- B. Anterior jugular vein.
- C. Internal carotid artery.
- D. Internal jugular vein.
- E. External carotid artery.

The platysma is a superficial muscle of the neck, located just beneath the skin. Structures deeper than the platysma include those in the neck's deeper anatomical layers.

➤ *Explanation:*

- A. The external jugular vein is located more superficially, above the platysma.
- B. Anterior jugular vein is also superficial and located above the platysma.
- C. Correct, The internal carotid artery is located deeper in the neck, beneath the platysma.
- D. The internal jugular vein runs in a deeper plane than the external jugular vein but still lies superficial to structures like the carotid artery.

E. The external carotid artery is located more superficially compared to the internal carotid artery.

13) The thickest cutaneous nerve in the body is:

- A. Great auricular nerve.
- B. Lesser occipital nerve.
- C. Great occipital nerve.
- D. Posterior auricular nerve.
- E. Third occipital nerve.

➤ Explanation:

- A. Great auricular nerve arises from the cervical plexus (C2-C3) and supplies the ear and skin over the parotid gland but isn't the thickest cutaneous nerve.
- B. Lesser occipital nerve also arises from the cervical plexus (C2-C3) and supplies the skin behind the ear, it's thinner than great occipital nerve
- C. Correct, It's the thickest cutaneous nerve and provides sensation to the posterior scalp and upper neck.
- D. A branch of the facial nerve (CN VII); mainly motor, not cutaneous.
- E. Arises from C3 dorsal ramus, supplying the lower part of the occipital scalp, but it's thinner than the great occipital nerve

The great occipital nerve is the thickest cutaneous nerve in the body. It is a sensory nerve that originates from the dorsal ramus of the second cervical spinal nerve (C2) and provides sensation to the posterior scalp.

14) Which structure from the following related anteriorly to transverse sinus:

- A- Pterion.
- B- Infratemporal fossa.
- C- Suprameatal triangle.
- D- Asterion.
- E- Pterygomandibular fossa.

➤ Explanation:

- A. The junction of frontal, parietal, temporal, and sphenoid bones; related to the middle meningeal artery, not the transverse sinus.
- B. A space below the temporal fossa, containing muscles of mastication and maxillary artery, unrelated to the transverse sinus.
- C. A small triangular area above the external auditory meatus.
- E. Pterygomandibular fossa isn't an anatomical term; likely referring to the pterygomandibular space, which is between the medial pterygoid muscle and the mandible

D. True/ The transverse sinus is a major dural venous sinus that runs along the posterior part of the skull, draining venous blood from the brain into the sigmoid sinus.

* Asterion is an anatomical landmark located at the junction of three cranial sutures:

- * Lambdoid suture
- * Parietomastoid suture
- * Occipitomastoid suture
- * The transverse sinus is located deep to the asterion.

15) One of the following is a therapeutic use of topical steroids:

- A- Impetigo.
- B- Ulcers.
- C- Dermatophytes.
- D- Discoid lupus erythematosus.
- E- Herpes simplex

➤ Explanation:

D. Correct, Topical corticosteroids are commonly used to reduce inflammation and suppress immune responses. Discoid lupus erythematosus is a chronic autoimmune disorder affecting the skin, and topical steroids are a first-line treatment to reduce inflammation and lesions.

- A. Impetigo is a bacterial infection (caused by *staphylococcus aureus* or *Streptococcus pyogenes*), and steroids should not be used, as they can worsen the infection. Topical antibiotics (mupirocin) are the preferred treatment.
- B. Topical steroids should not be applied to ulcers, as they can delay healing and increase the risk of infection.
- C. Dermatophytes are fungal infections (eg. *Tinea corporis*, *tinea pedis*), and steroids worsen fungal infections by suppressing the immune response, Topical antifungal are the treatment of choice.
- E. Herpes simplex virus (HSV) infections should be treated with antiviral medication (e.g. acyclovir), not steroids, which can exacerbate viral infections.

16) Identify the INCORRECT statement, Select one:

- A. Osteocytes and chondrocytes are located in lacunae, i.e. small hollows in the matrix of bone and cartilage
- B. Collagen fibres are only present in fibrous cartilage
- C. During development, cartilage grows by interstitial and appositional mechanisms
- D. Cartilage is generally avascular
- E. In some locations hyaline cartilage is associated with perichondrium

➤ *Explanation:*

B. Incorrect statement, Collagen fibers are found in **all** types of cartilage (hyaline, elastic and fibrous).
 Lacunae are small spaces or cavities within the extracellular matrix of bone and cartilage that house cells. In bone, osteocytes (mature bone cells) reside in lacunae, which are connected by tiny channels called canaliculi to allow communication and nutrient exchange.
 In cartilage, chondrocytes (mature cartilage cells) are found in lacunae, embedded in the flexible extracellular matrix.
 Lacunae serve as protective spaces that maintain and support the cells within the rigid or semi-rigid matrix of bone and cartilage.

17) The following skeletal muscle relaxants match their side effects EXCEPT:

- A. Orphenadrine: Antimuscarinic side effects
- B. Succinylcholine: Post-operative muscle pain
- C. Baclofen: Seizures in epileptic patients
- D. Vecuronium: Histamine release from mast cells
- E. Dantrolene: Liver toxicity

Drug	Mechanism of Action	Side Effect
Orphenadrine	Central anticholinergic action: Blocks muscarinic receptors and inhibits excitatory pathways in the CNS.	Antimuscarinic side effects: (dry mouth, blurred vision, urinary retention, etc...)
Succinylcholine	Depolarizing neuromuscular blocker: Acts as an agonist at nicotinic acetylcholine (nACh) receptors, causing persistent depolarization and temporary paralysis.	Post-operative muscle pain due to initial fasciculations.
Baclofen	GABA-B receptor agonist: Inhibits excitatory neurotransmitter release in the spinal cord, reducing muscle spasticity.	Seizures in epileptic patients, as it can lower the seizure threshold.

Vecuronium	Non-depolarizing neuromuscular blocker: Competitively blocks nicotinic acetylcholine receptors (nAChRs) at the neuromuscular junction, preventing muscle contraction.	Does NOT cause significant histamine release (unlike tubocurarine or atracurium)
Dantrolene	Inhibits ryanodine receptors (RyR1) in skeletal muscle, reducing calcium release from the sarcoplasmic reticulum, leading to muscle relaxation.	Liver toxicity (risk of hepatotoxicity with prolonged use)

18) Regarding the muscles of pronation and supination, which is FALSE?

- A. Brachioradialis is supplied by radial nerve
- B. Supinator is supplied by posterior interosseous nerve
- C. Pronator teres is supplied by median nerve
- D. Biceps brachii is supplied by axillary nerve
- E. Pronator quadratus is supplied by anterior interosseous nerve

➤ *Explanation:*

- B. Correct statement, because of the posterior interosseous nerve is a branch of radial nerve.
- D. Incorrect statement, Biceps brachii is actually supplied by the musculocutaneous nerve (C5-C7), not the axillary nerve.
- The axillary nerve (C5-C6) mainly supplies the deltoid and teres minor muscles
- E. Correct statement, because of the anterior interosseous nerve is a branch of median nerve.

19) The maximum effective mechanism that help human body from temperature changes is, select ONE:

- A. Behavioral response
- B. Blood vessel response
- C. Sweat gland response
- D. Shivering response
- E. Pilo-erection

➤ *Explanation:*

- A. Correct, It's the most effective way like wearing appropriate clothing.
- B. It's not effective alone for large changes.
- C. It helps to cool the body down but it's not effective in cold environment.
- D. It helps to generate heat in cold environment, but it's not the most effective way.
- E. It doesn't really contribute in human body temperature.

20) Which of the following muscles is supplied by axillary nerve?

- A. Rhomboideus major
- B. Levator scapula
- C. Latissimus dorsi
- D. Trapezius muscle
- E. Deltoid muscle

➤ *Explanation:*

- A. Rhomboideus major → Supplied by the dorsal scapular nerve.

- B. *Levator scapula* → Supplied by the dorsal scapular nerve and cervical nerves.
- C. *Latissimus dorsi* → Supplied by the thoracodorsal nerve.
- D. *Trapezius muscle* → Supplied by the accessory nerve (cranial nerve XI) and cervical spinal nerves (C3-C4).
- E. Correct, The deltoid muscle is supplied by the axillary nerve (C5-C6).

21) A 6-year-old girl presents to the emergency department with a fever and a lacy body rash. Her mother says that yesterday the rash was only on her face, but by this morning, had spread to her trunk and extremities. Which of the following agents is most likely?

- A. Parvovirus B19.
- B. HHV-6.
- C. Measles.
- D. Rubella.
- E. Varicella zoster virus.

E. *Varicella zoster virus* → Causes chickenpox, which presents with vesicular lesions in different stages of development (papules, vesicles, and scabs), not a lacy rash

➤ Explanation:

- A. Correct, *Parvovirus B19* causes erythema infectiosum (also known as fifth disease), which is characterized by a "slapped cheek" rash on the face, followed by a lacy, reticular rash that spreads to the trunk and extremities. The rash usually starts on the face and then spreads to other parts of the body, just as described in the question.
- B. *HHV-6* → Causes roseola (sixth disease), which presents with a high fever followed by a rose-colored maculopapular rash that starts on the trunk and spreads to the extremities, but it does not have the lacy pattern seen in this case.
- C. *Measles* → Characterized by a morbilliform rash that starts on the face and spreads downward, along with other symptoms like cough, coryza, and conjunctivitis.
- D. *Rubella* → Causes a maculopapular rash that begins on the face and spreads downward, but it is not typically described as lacy.

22) The hardness of bone results from the presence of inorganic mineral salts, mainly?

- A. Lacunae
- B. Hydroxyapatite
- C. Endosteum
- D. Canaliculi
- E. Organic matrix

A. *Lacunae* → Small cavities in bone where osteocytes reside, but they don't contribute to hardness.

➤ Explanation:

- B. Correct, *Hydroxyapatite* is the main inorganic mineral salt that provides hardness and rigidity to bone. It is a crystalline structure composed mainly of calcium phosphate.
- C. *Endosteum* → A thin membrane lining the inner surface of the bone, not related to bone hardness.
- D. *Canaliculi* → Small channels that allow for communication between osteocytes, but they don't contribute to bone hardness.
- E. *Organic matrix* → Composed of collagen fibers and other proteins that provide flexibility, but not hardness.

23) Which muscle of mastication inserted in the capsule of TMJ?

- A. Medial pterygoid

A. *Medial pterygoid* → Inserts on the medial surface of the mandible, not the TMJ capsule.

- B. Lateral pterygoid
- C. Masseter
- D. Temporalis
- E. Platysma

➤ *Explanation:*

- B. Correct, *The lateral pterygoid muscle inserts into the capsule of the temporomandibular joint (TMJ) and the articular disc. It plays a crucial role in the movement of the jaw, particularly in opening the mouth and protruding the jaw.*
- C. Masseter → *Inserts on the angle and ramus of the mandible.*
- D. Temporalis → *Inserts on the coronoid process of the mandible.*
- E. Platysma → *A superficial muscle of the neck, not involved in mastication.*

24) The following match their treatment EXCEPT:

- A. Hyperhidrosis: Topical aluminum chloride hexahydrate 20% in ethanol
- B. Vitiligo: Topical cyclosporine ointment
- C. Melasma: Topical alclomethasonedipropionate cream
- D. Basalcell carcinoma: Intralesional 5-Fluorouracil 5%
- E. Alopecia areata: Intralesional triamcinolone acetonide hexahydrate

➤ *Explanation:*

- A. *Hyperhidrosis (excessive sweating) is treated with topical aluminum chloride hexahydrate 20% ethanol.*
- B. *Vitiligo → Topical cyclosporine ointment has been used for treating vitiligo, though topical corticosteroids are more common.*
- C. *Melasma → Topical alclomethasone dipropionate cream (a potent corticosteroid) is sometimes used, though hydroquinone is more commonly used for melisma.*
- D. *Correct answer, Basal cell carcinoma (BCC) is typically treated with surgical excision, electrodesiccation and curettage, or topical treatments like imiquimod or 5-fluorouracil (5-FU), but intralesional 5-FU is not a standard treatment for BCC. Intralesional 5-FU is more commonly used for keloids or certain types of warts.*
- E. *Alopecia areata → Intralesional triamcinolone acetonide hexahydrate is a standard treatment for it.*

25) All the following are characteristics for Fibromatoses, EXCEPT?

- A. Their tendency to grow in an infiltrative fashion.
- B. They recur after surgical removal.
- C. They can metastasize.
- D. They are composed of plump spindle cells arranged in broad sweeping fascicles
- E. They are locally aggressive.

➤ *Explanation:*

- A. *This is true; fibromatoses infiltrate surrounding tissues.*
- B. *This is true; due to their infiltrative nature, fibromatoses are prone to recurrence.*
- C. *Correct, Fibromatoses are benign tumors or lesions that are locally aggressive but do not metastasize. They grow in an infiltrative fashion and tend to recur after surgical removal, but they do not spread to other parts of the body like malignant tumors.*
- D. *This is true; histologically, fibromatoses typically show spindle-shaped cells arranged in fascicles.*
- E. *This is true; fibromatoses can cause significant local tissue destruction despite being benign.*

26) All the following are characteristics of Ewing sarcoma, EXCEPT?

- A. They are primary malignant small round cell tumors of bone.
- B. Most patients are 10 to 15 years of age, and 80% are younger than 20 years.
- C. These tumors have a translocation of t(2,13).
- D. It typically manifests as a painful enlarging mass in the diaphysis of long tubular bones.
- E. Boys are affected slightly more frequently than girls.

➤ Explanation:

- A. True; Ewing sarcoma is a primary malignancy that often arises
- B. True, Ewing sarcoma predominantly affects children and adolescents.
- C. Incorrect statement, Ewing sarcoma is characterized by a specific chromosomal translocation, t(11,22), not t(2,13). The t(11,22) translocation results in the fusion of the EWSR1 gene on chromosome 11 and the FLI1 gene on chromosome 22, which is a hallmark of Ewing sarcoma.
- D. True, Ewing sarcoma commonly affects the diaphysis (shaft) of long bones, leading to pain & swelling.
- E. True, there is a slight male predominance in Ewing sarcoma cases.

27) All the following are features of Chondrosarcomas, EXCEPT?

- A. Chondrosarcomas commonly involve the small bone of the distal extremities.
- B. They typically manifest as painful, progressively enlarging masses.
- C. Chondrosarcomas metastasize hematogenously, preferentially to the lungs and skeleton.
- D. Chondrosarcomas grade 1 tumors rarely metastasize.
- E. Conventional chondrosarcomas are treated with wide surgical excision and Chemotherapy is added for the mesenchymal variant.

➤ Explanation:

- A. Correct answer, Chondrosarcomas are malignant tumors that primarily affect the long bones (such as the femur, humerus, and pelvis), not the small bones of the distal extremities. They usually involve larger bones and tend to occur in the proximal parts of limbs rather than the small bones of the hands or feet.
- B. Chondrosarcomas often present as gradually enlarging painful masses.
- C. Chondrosarcomas tend to metastasize via the bloodstream, with common sites being the lungs and other skeletal bones.
- D. Low-grade (grade 1) chondrosarcomas are less likely to metastasize compared to higher-grade tumors.
- E. Conventional chondrosarcomas are typically treated with surgical excision, while the mesenchymal variant, which is more aggressive, may also require chemotherapy.

28) Bone building cells that synthesize and secrete collagen fibers and other organic components needed to build the extracellular matrix of bone tissue, and initiate calcification are?

- A. Osteogenic cells
- B. Osteoblasts
- C. Osteocytes
- D. Osteoclasts
- E. Fibroblasts

➤ Explanation:

- A. Osteogenic cells are stem cells that can differentiate into osteoblasts but do not directly synthesize bone matrix.

B. Correct answer, Osteoblasts are the bone-building cells responsible for synthesizing and secreting collagen fibers and other organic components needed to build the extracellular matrix of bone tissue. They also play a key role in the process of calcification, where they facilitate the deposition of minerals like calcium phosphate to form hard bone tissue.

C. Osteocytes are mature bone cells that maintain bone tissue and communicate with osteoblasts and osteoclasts but do not actively build bone matrix.

D. Osteoclasts are bone-resorbing cells that break down bone tissue, not build it.

E. Fibroblasts are cells that produce collagen and other fibers, primarily in connective tissue, not in bone.

29) The most anterior structures in the intercondylar area?

A. Anterior horn of the lateral meniscus

B. Anterior cruciate ligament

C. Anterior horn of the medial meniscus

D. Posterior horn of the lateral meniscus

E. Posterior cruciate ligament

➤ Explanation:

C. Correct answer, In the intercondylar area, the most anterior structures, from front to back, include:

- The anterior horn of the medial meniscus is the most anterior structure.
- The anterior cruciate ligament (ACL) lies behind it.
- The anterior horn of the lateral meniscus is positioned further posteriorly.
- The posterior cruciate ligament (PCL) and posterior horn of the lateral meniscus are positioned even further back in the knee joint.

30) According to Force-Velocity relationship, training causes all the following EXCEPT?

A. Heavy strength training will increase the maximum force

B. Heavy strength training will increase the maximum velocity

C. Heavy strength training increase the power of the muscle

D. Light, high velocity training shift the force velocity curve up

E. Light, high velocity training increase the power of the muscle

➤ Explanation:

B. Correct answer, The force-velocity relationship describes how the force a muscle can generate changes with the speed of contraction. In general:

- Heavy strength training focuses on increasing maximum force (option a) but does not typically increase the maximum velocity (option b). High-load, low-velocity training tends to improve strength but not speed.
- Light, high-velocity training (option e) increases the power of the muscle because power is the product of force and velocity.
- Heavy strength training will increase the power (option c) up to a certain point by enhancing the force aspect, but it is less effective at increasing velocity.
- Light, high-velocity training can shift the force-velocity curve up (option d) by increasing the velocity component of power generation.

31) The following are effects of coal tar applications on skin EXCEPT:

A. Stains skin and clothing

B. Antipruritic

C. Inhibition of parakeratosis

- D. Antiseptic
- E. Soothes acutely inflamed skin lesions

➤ *Explanation:*

- A. True, Coal tar can stain the skin and clothing.
- B. True, Coal tar has antipruritic properties, meaning it helps relieve itching.
- C. True, Coal tar helps reduce parakeratosis, which is the abnormal retention of nuclei in the epidermis, often seen in psoriasis.
- D. True, Coal tar has some antiseptic properties, helping to prevent infection.
- E. Correct answer, Coal tar does NOT soothe acutely inflamed skin lesions. It is more effective in chronic conditions like psoriasis, where the skin is thickened and scaling, rather than in acute inflammatory situations.

32) The petrotic capsule gives:

- A. Greater wing of the sphenoid
- B. Clivus
- C. Cribriform plate of the ethmoid bone
- D. Petrous part of the temporal bone
- E. Body of the sphenoid

➤ *Explanation:*

- A. This is part of the sphenoid bone.
- B. Clivus is part of the basilar part of the occipital bone.
- C. Cribriform plate of the ethmoid bone is part of the ethmoid bone.
- D. Correct answer, The petrotic capsule (also known as the otic capsule) is the part of the temporal bone that encases the inner ear structures. It gives rise to the petrous part of the temporal bone, which houses the structures of the inner ear, including the cochlea and the semicircular canals.
- E. Body of the sphenoid is the central portion of the sphenoid bone.

33) All the following are features of Giant cell tumor (GCT), EXCEPT?

- A. It has the synonym of osteoclastoma.
- B. GCT is a relatively common benign but locally aggressive bone tumor.
- C. A majority of GCTs arise in the diaphysis of long bones around the knee.
- D. Most are solitary tumors.
- E. About 2% of GCT spreads to the lungs.

➤ *Explanation:*

- A. GCT is also known as osteoclastoma due to the presence of multinucleated giant cells.
- B. This is correct. GCTs are benign but have aggressive
- C. Correct answer, GCT arise in Epiphysis of long bones often in knee region.
- D. GCTs are usually solitary, though they can rarely be multiple.

34) Sympathetic stimulation will cause all the following, EXCEPT?

- A. Increase the heart rate
- B. Increase the inotropic effect
- C. Increase the relaxation time
- D. Decrease the refractory period
- E. Activation of cyclic AMP

➤ *Explanation:*

- A. Sympathetic stimulation increases heart rate (positive chronotropic effect).
- B. Sympathetic stimulation increases the force of contraction of the heart (positive inotropic effect).
- C. Correct answer, Sympathetic stimulation actually decreases relaxation time (also known as lusitropy), facilitating faster relaxation of the heart muscle. This is beneficial for increasing the heart's efficiency and response during stress or physical activity.
- D. Sympathetic stimulation typically decreases the refractory period of cardiac cells, making the heart more responsive to subsequent stimuli.
- E. Sympathetic stimulation activates adenylyl cyclase, leading to an increase in cyclic AMP (cAMP), which mediates the effects of catecholamines like norepinephrine and epinephrine.

35) One of the following is CORRECT about epidermis:

- A. The epidermis is characterized by sloughing-off
- B. Keratinocytes are dendritic cells
- C. Granular keratin is present in stratum spinosum
- D. Melanocytes are migrating cells within epidermis layers
- E. Stratum lucidum has nucleated cells

➤ *Explanation:*

- A. True, The epidermis is constantly shedding dead cells from the surface, a process called desquamation, where old cells are sloughed off to make way for new ones.
- B. Keratinocytes are the main cell type in the epidermis responsible for forming the skin barrier. Dendritic cells are a type of immune cell, not keratinocytes.
- C. Granular keratin (keratohyalin) is found in the stratum granulosum, not the stratum spinosum.
- D. Melanocytes are present in the basal layer of the epidermis and do not migrate throughout the epidermis.
- E. Stratum lucidum composed of flattened, dead keratinocytes and typically doesn't have nucleated cells.

36) Which of the followings is INCORRECT regarding Trichinella infestation?

- A. Asymptomatic infection when less than 10 larvae per gram of muscle
- B. Heavy infections is life threatening when more than 25 larvae per gram of muscle.
- C. One of the most involved muscles is the extraocular muscles.
- D. Peaking about 3 weeks after infection.
- E. A presumptive clinical diagnosis can be based on fevers, eosinophilia, periorbital edema, and myalgias after a suspect meal

➤ *Explanation:*

- A. Mild infections with fewer larvae generally cause minimal or no symptoms.
- B. Correct answer, Heavy infections with a large number of larvae can be severe, life-threatening infections are typically associated with more than 1,000 larvae per gram of muscle, not 25.
- C. Extraocular muscles are often affected in Trichinella infestation, contributing to the characteristic periorbital edema.
- D. The symptoms typically peak 2-3 weeks after infection as the larvae migrate to muscle tissue.
- E. These symptoms, along with a history of consuming undercooked pork or wild game, can lead to a presumptive diagnosis of Trichinella infestation.

37) As regard osteocalcin, all of the following are true, EXCEPT?

- A. Osteocalcin is a small protein that is carboxylated on glutamic acid residues with the help of vitamin K
- B. Osteocalcin binds hydroxyapatite

- C. It is required for formation of hydroxyapatite
- D. Its synthesis is induced by activated vitamin D receptor
- E. It acts as a metabolic hormone enhancing insulin activity

➤ *Explanation:*

- A. Osteocalcin undergoes vitamin K-dependent carboxylation of glutamic acid residues, which is essential for its function.
- B. Osteocalcin has the ability to bind hydroxyapatite, a major component of bone mineral.
- C. Correct answer, Osteocalcin is involved in the regulation of bone mineralization but is not required for the formation of hydroxyapatite itself. Hydroxyapatite formation primarily depends on calcium and phosphate.
- D. Osteocalcin expression is regulated by vitamin D through its receptor (VDR).
- E. Osteocalcin is also known to have endocrine effects, including enhancing insulin secretion and sensitivity.

38) Paracetamol has all of the following effects, EXCEPT?

- A. It is a weak inhibitor of cyclooxygenases
- B. It is an aspirin substitute in patients with peptic ulcer
- C. It is capable of reducing inflammation in a patient with arthritis
- D. It may cause acute tubular necrosis
- E. It has no effect on platelet

➤ *Explanation:*

- A. Paracetamol (acetaminophen) is a weak inhibitor of cyclooxygenase (COX), particularly COX-1 and COX-2, and is more effective in the central nervous system.
- B. Paracetamol is often used as an alternative to aspirin in patients with peptic ulcers, as it is less likely to cause gastrointestinal irritation and bleeding.
- C. Correct answer, Paracetamol is generally not considered an anti-inflammatory drug while it provides analgesia as reduce fever, it has minimal anti-inflammatory effects compared to NSAIDs like aspirin or ibuprofen.
- D. In cases of overdose, Paracetamol can lead to liver toxicity, and severe overdose can result in acute tubular necrosis.
- E. Unlike aspirin, paracetamol does not significantly affect platelet function or cause bleeding disorders.

39) One of the following statements is true about the thermo-regulation

- A. Venous-plexus always supplied by capillaries
- B. Most of the heat loss is via sweating and insensible evaporation
- C. Posterior hypothalamus receives impulses from warm more than cold receptors
- D. NaCl re-absorption by sweat duct is reduced with increased sweating
- E. Urea in the sweat is not reduced by increase sweating

➤ *Explanation:*

- A. This is incorrect. Venous plexuses are not always directly supplied by capillaries in the context of thermoregulation; they can receive blood from arterioles or venules.
- B. Correct answer, Sweating (evaporation of sweat) and insensible evaporation (from the skin and respiratory tract) are the primary mechanisms of heat loss.
- C. The posterior hypothalamus is involved in heat conservation and heat production, but it receives input from both cold and warm receptors. Cold receptors are more abundant in the skin, and the anterior hypothalamus primarily controls heat loss mechanisms.

D. As sweating increases, the reabsorption of NaCl in the sweat ducts typically increases to conserve electrolytes, leading to less salty sweat at higher sweat rates.

E. As the rate of sweating increases, the concentration of urea in sweat decreases, since urea is filtered out of sweat at a constant rate, and more water is lost with higher sweat rates.

40) All of the followings are contents of digastric triangle EXCEPT?

- A. Facial artery
- B. Lingual nerve
- C. Submandibular ganglion
- D. Facial nerve
- E. Hypoglossal nerve

➤ *Explanation:*

A. The facial artery is a content of the digastric triangle. It runs across the triangle to supply the face.

B. The lingual nerve, which provides sensory innervation to the tongue, is also found in the digastric triangle.

C. Correct answer, The submandibular ganglion is located near the submandibular gland but is not a primary structure within the digastric triangle itself.

D. The facial nerve passes through the digastric triangle as it innervates the muscles of facial expression.

E. The hypoglossal nerve also runs through the digastric triangle to innervate the tongue muscles.

41) Thyrohyoid muscle supplied by which cranial nerve?

- A. C1.
- B. C2.
- C. C3.
- D. C4.
- E. C5.

➤ *Explanation:*

A. True, The thyrohyoid muscle is a small muscle in the anterior neck that elevates the larynx and depresses the hyoid bone, It is supplied by C1 fibers that travel with the hypoglossal nerve (CN XII) but originate from the C1 ventral ramus.

These C1 fibers branch off from CN XII to form the nerve to thyrohyoid, which innervates the muscle.

B. C2 contributes to the ansa cervicalis but the thyrohyoid muscle is not innervated by ansa cervicalis.

Option (C/D) : C3, C4 nerves contribute to the ansa cervicalis, which supplies other infrahyoid muscles (sternohyoid, sternothyroid, and omohyoid), but not thyrohyoid.

E. C5 is part of the brachial plexus and has no role in thyrohyoid muscle innervation.

42) All of the following are drugs induce pigmentation EXCEPT:

- A- Hydroxychloroquine.
- B- Ampicillin.
- C- Bleomycin.
- D- Amiodarone.
- E- Doxycycline.

➤ *Explanation:*

Certain drugs can cause hyperpigmentation as a side effect by depositing in tissues, stimulating melanin production or causing post-inflammatory pigmentation.

- A. Hydroxychloroquine causes blue-gray pigmentation on the skin, especially in sun-exposed areas.
- B. correct answer, Ampicillin does NOT cause pigmentation as a side effect at all.
- C. Bleomycin causes flagellate hyperpigmentation due to its effect on melanocytes.
- D. Amiodarone leads to bluish-gray pigmentation, especially on the face and sun-exposed areas.
- E. Doxycycline causes photosensitivity and post-inflammatory hyperpigmentation.

43) Which topical steroids from the following are safe for face and skin folds?

- A. Hydrocortisone.
- B. Flucinonide.
- C. Diprolene.
- D. Colbetasol propionate.
- E. Amcinonide.

➤ *Explanation:*

When using topical steroids on the face and skin folds (intertriginous areas), low-potency steroids are preferred to minimize the risk of skin atrophy, telangiectasia.

Steroid	Potency	Safe for skin and skin folds?
Hydrocortisone	Low	Yes (safe)
Flucinonide	High	No (too strong)
Betamethasone dipropionate (Diprolene)	Very high	No (too strong)
Colbetasol propionate	Ultra high	No (too strong)
Amcinonide	High	No (too strong)

A. the correct answer, Hydrocortisone has mild potency, so reduces inflammation with minimal side effects. It is safe for delicate areas (face, skin folds, groin)/ lower risk of atrophy, striae and thinning of the skin.

The other options (B/C/D/E) :

Flucinonide, Diprolene, Colbetasol propionate, Amcinonide are too strong for thin skin areas, They can cause skin thinning, telangiectasia and hypopigmentation.

44) Which of the following adverse effects is associated with isotretinoin?

- A. Hypotension.
- B. Increased appetite.
- C. Bradycardia.
- D. Fatal anomaly.
- E. Renal effects.

➤ *Explanation:*

Adverse effects of Isotretinoin:

1- Teratogenicity (most serious)

Fetal congenital anomalies: Craniofacial, cardiac and CNS defects.

Contraindicated in pregnancy (requires iPLEDGE program for women of childbearing age)

So, option (D) is the correct answer.

2- Mucocutaneous effects

Dry skin and lips (cheilitis) is the most common side effect.

Dry eyes and nose (epistaxis, conjunctivitis).

3- Systemic effects

- Hyperlipidemia (increased triglycerides and cholesterol)
- Hepatotoxicity: elevates liver enzymes (AST/ALT)
- Pseudotumor cerebri: increased intracranial pressure (headache, papilledema)
- Skeletal effects: premature epiphyseal closure, osteoporosis, myalgia.

Option	Effect	Reason
A. Hypotension	No	Not a known side effect. Isotretinoin doesn't affect BP.
B. Increased appetite	No	It can cause weight loss due to mucosal dryness and GI upset.
C. Bradycardia	No	No direct effects on heart rate.
E. Renal effects	No	Isotretinoin doesn't cause nephrotoxicity.

45) A 5-year old girl, is brought to the paediatrician by her parents due to recurrent skin rashes. She has a history of atopic dermatitis since infancy, characterised by dry, itch patches on her skin. From the following, what is also finding in the girl with atopic dermatitis:

- A. Erythema multiforme.
- B. Asthma.
- C. Psoriasis.
- D. Urticaria.

➤ Explanation:

Atopic dermatitis (AD) is a chronic inflammatory skin disease often associated with other atopic conditions like asthma and allergic rhinitis. This is known as atopic march, where children with AD have an increased risk of developing asthma and allergic rhinitis later in life.

➤ Atopic dermatitis, asthma, and allergic rhinitis form the atopic triad.

* 80% of children with severe atopic dermatitis develop asthma.

* Th2-mediated immune response → Increased IgE, eosinophils, and histamine release contribute to both AD and asthma. So, the correct option is (B).

Other options (A/C/D) are not associated with atopic dermatitis.

46) If the hernia pass lateral to inferior epigastric artery, reach scrotum and effect on young patient, it will be:

- A. Direct inguinal hernia.
- B. Epigastric hernia.

- C. Oblique inguinal hernia.
- D. Femoral hernia.
- E. Umbilical hernia.

➤ *Explanation:*

An inguinal hernia is classified as direct or indirect based on its relationship to the inferior epigastric artery.

* *Direct inguinal hernia:*

- Passes medial to the inferior epigastric artery.
- Protrudes through Hesselbach’s triangle.
- Does not reach the scrotum.
- Common in older men due to weak abdominal muscles.

* *Indirect (oblique) inguinal hernia:*

- Passes lateral to the inferior epigastric artery.
- Enters the deep inguinal ring, follows the inguinal canal, and may extend into the scrotum.
- More common in young males (congenital due to patent processus vaginalis).

So, the option (C) is the correct answer.

47) One of the following is incorrect according to ligaments of temporomandibular joint:

- A. Stylomandibular ligament separates parotid gland from submandibular gland.
- B. Temporomandibular ligament originated from root of zygomatic arch.
- C. Pterygomandibular ligament inserted into posterior end of mylohyoid line.
- D. Stylomandibular ligament originated from styloid process of angle of the mandible.
- E. Sphenomandibular ligament gives origin to buccinator and superior constrictor muscle of the pharynx.

➤ *Explanation:*

The stylomandibular ligament is a key ligament of the temporomandibular joint (TMJ), but its insertion is incorrect in option D.

Stylomandibular Ligament:

Origin: Styloid process of the temporal bone.

Insertion: Angle of the mandible (just below the styloid process itself).

Function: Separates the parotid gland from the submandibular gland.

Thus, the statement in option D is incorrect because it wrongly states that the ligament originates from the styloid process of the angle of the mandible, which is not anatomically correct.

Option	Correct explanation
A. Stylomandibular ligament separates parotid gland from submandibular gland.	True, the stylomandibular ligament lies between these two glands.
B. Temporomandibular ligament originated from root of zygomatic arch.	True, The tempromandibular ligament originates from the zygomatic arch and attaches to the neck of mandible.
C. Pterygomandibular ligament inserted into posterior end	True, The ptergomandibular raphe is attached to

of mylohyoid line.	the posterior mylohyoid line of the mandible.
E. Sphenomandibular ligament gives origin to buccinators and superior constrictor muscle of the pharynx.	True, The sphenomandibular ligament provides an attachment for these muscles

48) All of the following is true about facial artery EXCEPT:

- A. Enter the face by hooking around lower border of the mandible.
- B. Ends as superior labial artery.
- C. Has inferior labial branch.
- D. Supply the side of the nose.
- E Runs a tortuous course crossing the mandible.

➤ *Explanation:*

The facial artery is a major branch of the external carotid artery and supplies the face, lips, and nose. However, it does not end as the superior labial artery – this statement is incorrect.

➤ *Course of the Facial Artery:*

- 1- Origin: Arises from the external carotid artery.
 - 2- Course: Runs tortuous (wavy) and crosses the lower border of the mandible near the anterior edge of the masseter muscle.
 - 3- Branches:
 - Inferior labial artery (supplies the lower lip).
 - Superior labial artery (supplies the upper lip).
 - Lateral nasal artery (supplies the side of the nose).
 - 4- Termination: The facial artery ends as the angular artery, which supplies the medial canthus of the eye.
- So, Option (B) is the the correct answer.

49) We can identify axis by:

- A. Facet on the side of the body.
- B. No body.
- C. Odontoid process.
- D. No foramen transversarium.

➤ *Explanation:*

- A. While the axis does have superior articular facets, these are not unique to the axis. Other vertebrae also have similar facets for articulation with adjacent vertebrae.
- B. This is a feature of the atlas (C1), not the axis (C2). The axis does have a body, which is important for supporting the odontoid process.
- C. True, The axis (C2 vertebra) is unique because of its odontoid process (dens), which extends upward and articulates with the atlas (C1). This structure allows the rotation of the head, making it a definitive feature of the axis.

D. The axis (C2) does have foramina transversaria, just like all cervical vertebrae. These openings allow the passage of the vertebral arteries, which supply blood to the brain.

50) One of the following drug of rheumatoid arthritis has not associated with T.B :

- A. Rituximab.
- B. Abatacept.
- C. Infliximab.
- D. Anakinra.
- E. Sarilumab.

➤ Explanation:

Drug	Mechanism of action	TB risk
A. Rituximab	Anti-CD20 monoclonal antibody (targets B cells)	Low risk, but screening is still recommended
B. Abatacept	CTLA-4 fusion protein (T-cell costimulation inhibitor)	Can increase TB risk.
C. Infliximab	TNF- α inhibitor	High risk of TB reactivation.
E. Sarilumab	IL-6 receptor antagonist	Low risk, but still requires screening.

D. Anakinra is an IL-1 receptor antagonist used in rheumatoid arthritis (RA) treatment. Unlike TNF- α inhibitors (e.g., Infliximab, Adalimumab, Etanercept), Anakinra is not associated with an increased risk of tuberculosis (TB) reactivation. So, the option (D) is the correct answer.

51) All of the following structure form pterion EXCEPT:

- A. Frontal bone.
- B. Squamous part of temporal bone.
- C. Greater wing of sphenoid.
- D. Parietal bone.
- E. Lesser wing of sphenoid.

➤ Explanation:

The pterion is the region where four skull bones meet:

1. Frontal bone
2. Parietal bone
3. Squamous part of the temporal bone
4. Greater wing of the sphenoid

However, the lesser wing of the sphenoid does not contribute to the pterion. Instead, it is located deeper and more superiorly, forming part of the anterior cranial fossa. So, option (E) is the correct answer.

52) One of the following is incorrect regarding aortic opening:

- A. Opposite T10.

- B. Part of major opening of the diaphragm.
- C. It's site is in medial plane.
- D. Azygos vein pass through it.
- E. Thoracic duct pass from it.

➤ *Explanation:*

- A. The aortic opening (aortic hiatus) is one of the three major openings of the diaphragm and is located at the level of T12, not T10. So, option (A) is the correct answer.
- B. The aortic hiatus is one of the three main diaphragm openings, along with the esophageal hiatus (T10) and caval opening (T8).
- C. The aortic hiatus is located in the midline (medial plane) of the diaphragm.
- D. The azygos vein and hemiazygos vein pass through the aortic opening along with the aorta.
- E. The thoracic duct, the largest lymphatic vessel in the body, also passes through the aortic hiatus.

53) If the skull is elongated anterioposterior, it is called:

- A. Acrocephaly.
- B. Scaphocephaly.
- C. Anencephaly.
- D. Meningocele.
- E. Plagiocephaly.

➤ *Explanation:*

- A. Acrocephaly (also known as oxycephaly or turriccephaly) occurs due to premature fusion of the coronal sutures, leading to a tower-shaped skull.
- B. Scaphocephaly (also called dolichocephaly) is a condition where the skull is elongated anterioposteriorly due to premature closure of the sagittal suture. This results in a long and narrow head shape. So, option (B) is the correct answer.
- C. Anencephaly is a severe neural tube defect where the brain and skull fail to develop, leading to the absence of a major part of the brain.
- D. Meningocele is a type of spina bifida where meninges protrude through a defect in the skull or spine, forming a sac filled with cerebrospinal fluid (CSF).
- E. Plagiocephaly is a flattening of one side of the skull, often due to external pressure or positional factors.

54) Baby born with absence of philtrum because incomplete fusion of:

- A. Medial nasal processes.
- B. Maxillary process and median nasal process.
- C. Maxillary processes.
- D. Maxillary process and mandibular process.
- E. Mandibular processes.

➤ *Explanation:*

- A. The median nasal processes fuse to form the intermaxillary segment, which contributes to the primary palate and the philtrum, but failure of fusion alone does not cause complete philtrum absence.
- B. The philtrum is the vertical groove in the midline of the upper lip, formed during facial development by the fusion of the maxillary process and the medial nasal process. If this fusion fails partially or completely, it can result in midline facial defects such as cleft lip or absence of the philtrum. So, option (B) is the correct answer.
- C. The maxillary processes fuse with the medial nasal processes, but they do not form the philtrum alone. Instead, they form the upper lip, cheeks, and lateral parts of the maxilla.
- D. These two processes contribute to jaw formation, but they are not involved in philtrum development.
- E. The mandibular processes fuse to form the lower jaw (mandible) and lower lip, which has no role in the philtrum's development.

55) All of the following is related to increase in AFP, EXCEPT:

- A. Meningocele.
- B. Myelocele.
- C. Spinal bifida occulta.
- D. Omphalocele.
- E. Meningomyelocele.

➤ *Explanation:*

- A. Meningocele is a type of spina bifida where the meninges protrude through a defect in the vertebral column. Since it is an open NTD, AFP leaks into the amniotic fluid, increasing maternal AFP levels.
- B. Myelocele is a severe form of spina bifida where the spinal cord is exposed without skin or meninges covering it. This direct exposure leads to significant AFP leakage.
- C. Alpha-fetoprotein (AFP) is a fetal glycoprotein produced by the yolk sac, fetal liver, and gastrointestinal tract. Elevated AFP levels in maternal serum and amniotic fluid are associated with neural tube defects (NTDs) and certain abdominal wall defects. Spinal bifida occulta is a closed NTD and does not cause significant AFP elevation. So, option (C) is the correct answer.
- D. Omphalocele is an anterior abdominal wall defect where the intestines and other organs protrude into the umbilical cord. Since the abdominal contents are not enclosed within the body, AFP levels rise.
- E. Meningomyelocele is the most severe form of spina bifida, where both the spinal cord and meninges protrude through a vertebral defect. It is an open NTD, leading to increased AFP levels.

56) Rectus abdominus muscle of anterior abdominal wall inserted into:

- A. 5,6,7 costal cartilage and xiphoid process.
- B. Lower part of linea alba.
- C. Anterior half of outer lip of iliac crest.
- D. Lower 6 ribs.
- E. Lumbar fascia.

➤ *Explanation:*

A. The *rectus abdominis* muscle is a long, paired muscle that runs vertically along the anterior abdominal wall. It is enclosed within the *rectus sheath* and plays a key role in trunk flexion, posture, and forced expiration.

Attachments of Rectus Abdominis:

* *Origin (Inferior Attachment):* Pubic symphysis and pubic crest

* *Insertion (Superior Attachment):*

5th, 6th, and 7th costal cartilages

Xiphoid process of the sternum

These insertions allow the muscle to pull the chest towards the pelvis during movements like sit-ups.

B. The *linea alba* is a midline fibrous structure, but *rectus abdominis* does not insert into it directly. Instead, the *rectus sheath* contributes to the *linea alba*.

C. This is the insertion of the *external oblique* muscle, not *rectus abdominis*.

D. The *rectus abdominis* inserts into only the upper 3 costal cartilages (5,6,7), not the lower ribs.

E. The *lumbar fascia* is related to the *lattissimus dorsi* and *erector spinae* muscles, not *rectus abdominis*.

57) Which muscle from the following is responsible for lateral flexion of the head:

A. *Rectus capitis anterior*.

B. *Rectus capitis posterior minor*.

C. *Rectus capitis lateralis*.

D. *Rectus capitis posterior major*.

E. *Longus coli*.

➤ *Explanation:*

A. *Rectus capitis anterior* mainly causes flexion of the head, not lateral flexion.

B. *Rectus capitis posterior minor* contributes to head extension, not lateral flexion.

C. True, *Rectus capitis lateralis* is a small muscle of the neck responsible for lateral flexion of the head (tilting the head to the same side). It helps stabilize the atlanto-occipital joint.

➤ *Attachments of Rectus Capitis Lateralis:*

Origin: Transverse process of atlas (C1).

Insertion: Jugular process of occipital bone.

Function:

* *Lateral flexion of the head.*

* *Helps stabilize the atlanto-occipital joint.*

D. *Rectus capitis posterior major* muscle mainly extends and rotates the head, but doesn't primarily cause lateral flexion.

E. *Longus coli* is responsible for neck flexion and rotation, not lateral flexion of the head.

58) One of the following is true regarding furuncle:

A. Contains only one draining point.

- B. Can progress to septicemia.
- C. *Candida albicans* may lead to it in immunocompromised patients.
- D. Called red gem.
- E. Self limiting.

➤ *Explanation:*

- A. A furuncle can have multiple draining points, especially if it coalesces with other furuncles to form a carbuncle (a more severe infection)
- B. True, A furuncle (boil) is a deep infection of a hair follicle caused by *Staphylococcus aureus*. It is a painful, pus-filled nodule that can enlarge and rupture. If the infection spreads into the bloodstream, it may cause septicemia (blood infection), which is a serious complication.
- C. Furuncles are bacterial infections, not fungal. *Candida albicans* causes cutaneous candidiasis, but it does not lead to furuncles.
- D. There is no known medical term "red gem" associated with furuncles.
- E. While some mild furuncles may resolve without treatment, many require drainage and antibiotics, especially if they are large, recurrent, or associated with systemic symptoms.

59) All of the following is correct regarding baricitinib, EXCEPT:

- A. Tyrosine receptor inhibitors.
- B. It is not a true biologic drug.
- C. Marketed as a biologic drug.
- D. Inhibit monophosphate dehydrogenase.
- E. All type of baricitinib increased risk of venous thrombotic events.

➤ *Explanation:*

- A. Baricitinib inhibits JAK1/JAK2, which are tyrosine kinase receptors involved in immune signaling.
- B. Unlike monoclonal antibodies, baricitinib is a small-molecule drug taken orally rather than being a true biologic (which are usually injectable).
- C. Although not a true biologic, it is often marketed alongside biologic drugs for rheumatoid arthritis treatment.
- D. Baricitinib is a Janus kinase (JAK) inhibitor, primarily JAK1 and JAK2, used for rheumatoid arthritis and COVID-19 treatment. It does NOT inhibit monophosphate dehydrogenase, which is the mechanism of mycophenolate mofetil. So, option (D) is the correct answer.
- E. JAK inhibitors, including baricitinib, have been linked to an increased risk of venous thromboembolism (VTE), including deep vein thrombosis (DVT) and pulmonary embolism.

60) A 55 year old man with history of coronary artery disease present to the emergency department with chest pain. He has a known history of hypertension and diabetes mellitus. An ECG shows ST-segment elevation and a diagnosis of MI is made. Which of the following medications should be administered immediately to help reduce mortality by preventing thrombus formation:

- A- Ibuprofen.
- B- Naproxen.
- C- Acetaminophen.
- D- Aspirin.
- E- Diclofenac.

➤ *Explanation:*

(A) *Ibuprofen: A nonsteroidal anti-inflammatory drug (NSAID) that does not prevent thrombus formation and can actually increase cardiovascular risk.*

(B) *Naproxen: Another NSAID that lacks antiplatelet effects and can also increase the risk of cardiovascular events.*

(C) *Acetaminophen: Lacks anti-inflammatory and antiplatelet effects, only used for pain/fever relief.*

(D) *Aspirin (Answer): In the setting of an ST-elevation myocardial infarction (STEMI), immediate treatment aims to reduce thrombus progression. Aspirin is a key medication because it inhibits platelet aggregation, thereby reducing clot formation. Mechanism: Aspirin irreversibly inhibits cyclooxygenase-1 (COX-1), blocking the production of thromboxane A2 (TXA2), a potent platelet aggregator and vasoconstrictor. Benefit in MI: Reduces thrombus formation at the site of ruptured atherosclerotic plaque, improving survival. Administration: Chewing 160-325 mg of non-enteric coated aspirin provides rapid absorption and immediate antiplatelet effect.*

(E) *Diclofenac: NSAID with a high cardiovascular risk, not recommended in MI.*

61) Which of these covers the active site of actin:

- A- Troponin C.
- B- Troponin I.
- C- Tropomyosin.
- D- Troponin T.
- E- Calmodulin.

➤ *Explanation:*

(A) *Troponin C: Binds calcium to initiate the movement of tropomyosin, but does not directly cover the active site.*

(B) *Troponin I: Inhibits actin-myosin interaction by helping hold tropomyosin in place, but it does not physically cover the binding site itself.*

(C) *Tropomyosin (Answer): In skeletal and cardiac muscle contraction, the active sites on actin filaments are regulated by tropomyosin and the troponin complex. Tropomyosin is a long, filamentous protein that lies along the actin filaments and covers the myosin-binding sites, preventing contraction in a relaxed state. When calcium binds to troponin C, it triggers a conformational change in the troponin complex, which moves tropomyosin away, exposing the active site and allowing myosin to bind to actin, leading to muscle contraction*

(D) *Troponin T: Attaches the troponin complex to tropomyosin but does not cover the active site.*

(E) *Calmodulin: A calcium-binding protein involved in smooth muscle contraction, but not in skeletal or cardiac muscle regulation.*

62) One of the following is the function of troponin C:

- A- Binding with calcium ions for contraction.
- B- Inhibit binding of actin and myosin.
- C- Binds troponin to tropomyosin to close active sites.

➤ *Explanation:*

A. (Answer): Troponin C (TnC) is a key regulatory protein in skeletal and cardiac muscle contraction. Its primary function is to bind calcium ions (Ca^{2+}) to initiate muscle contraction.

- 1) At rest, tropomyosin blocks the myosin-binding sites on actin, preventing contraction.
- 2) When Ca^{2+} is released from the sarcoplasmic reticulum, it binds to troponin C, triggering a conformational change in the troponin complex.
- 3) This causes tropomyosin to shift, exposing the myosin-binding sites on actin.

B. *Inhibit binding of actin and myosin: This is the function of Troponin I (TnI), which prevents myosin from binding to actin in a relaxed state.*

C. *Binds troponin to tropomyosin to close active sites: This describes Troponin T (TnT), which attaches the troponin complex to tropomyosin but does not bind calcium or initiate contraction.*

63) One of these methods is used in heat production:

- A- Conduction.
- B- Insensible sweating.
- C- Brown fat.
- D- Radiation.
- E- Convection.

➤ *Explanation:*

(A) *Conduction is a heat transfer method, not a production mechanism. It refers to direct transfer between objects in contact (e.g. touching a cold surface).*

(B) *Insensible sweating: evaporation of water from the skin and respiratory tract which cools the body. Sweating leads to heat loss through evaporation, not production.*

(C) *Brown fat (Answer): Brown fat (BAT) plays a crucial role in heat production (thermogenesis), especially in newborns. It contains many mitochondria that generate heat through non-shivering thermogenesis, mediated by uncoupling protein-1 (UCP1), which allows mitochondria to produce heat instead of ATP by uncoupling oxidative phosphorylation.*

(D) *Radiation is a heat loss mechanism where the body emits infrared radiation.*

(E) *Convection involves heat loss through the movement of air or liquid over the skin.*

64) Which method of these lead to increase body temperature:

- A- Eat more protein.
- B- Using fans to make air currents.

- C- Sweat evaporation.
- D- Direct contact with objects.
- E- Increase the cutaneous blood flow.

➤ *Explanation:*

- (A) *Eat more protein (Answer): Eating protein increases body temperature due to the thermic effect of food (TEF). The body works harder to digest and metabolize protein, which generates heat.*
- (B) *Using fans: This increases air circulation and enhances heat loss via evaporation and convection.*
- (C) *Sweat evaporation: A primary mechanism for heat loss to cool the body as sweat evaporates from the skin, it cools the body, reducing temperature.*
- (D) *Direct contact with objects: Usually results in heat loss if the object is cooler than the body.*
- (E) *Increase the cutaneous blood flow is a heat loss mechanism used when the body needs to cool down (e.g. during exercise or in hot environment)*

65) Allergic contact dermatitis caused by all of these, EXCEPT:

- A- Poison ivy.
- B- Chemical substance.
- C- Fungi.
- D- Latex.
- E- Radiation.

➤ *Explanation:*

- (A) *Poison ivy: A common cause of allergic contact dermatitis (ACD) due to urushiol oil that triggers an allergic response upon skin contact.*
- (B) *Chemical substance like fragrances or preservatives are classic causes of ACD upon skin contact.*
- (C) *Fungi: Certain fungi can trigger allergic reactions leading to dermatitis.*
- (D) *Latex: A very common allergen that causes ACD in sensitized individuals.*
- (E) *Radiation (Answer): Radiation does not cause immune-mediated allergic contact dermatitis.*

66) All of these muscles attached to axis except:

- A- Inferior oblique.
- B- Superior oblique.
- C- Rectus capitis posterior major.
- D- Scalenus medius.
- E- Longus colli.

➤ *Explanation:*

- (A) *Inferior oblique: Originates from the spinous process of C2 (axis) and inserts into transverse process of C1, helping with head rotation.*
- (B) *Superior oblique (Answer): This muscle does not attach to the axis (C2). It is part of the suboccipital group but attaches to the atlas and occipital bone.*

The axis (C2 vertebra) is the second cervical vertebra and serves as the pivot for the atlas (C1), allowing head rotation.

Several muscles attach to the axis, mainly involved in head and neck movement.

(C) *Rectus capitis posterior major*: Originates from the spinous process of C2 and inserts on the inferior nuchal line of occipital bone, assisting in head extension and rotation.

(D) *Scalenus medius*: Has attachments to the transverse processes of cervical vertebrae including C2, making it partially attached to axis.

(E) *Longus colli*: Has an attachment point on the body of C2 and extends down the cervical and upper thoracic spine, playing a role in neck flexion.

67) Which one of the following protein responsible for connect thick filament to Z disk:

A- Titin.

B- Nebulin.

C- Myomesin.

D- α -Actinin.

E- Troponin.

➤ *Explanation:*

In skeletal and cardiac muscle, the Z line serves as the anchoring point for the thin filaments (actin) and helps maintain structural integrity of sarcomere.

(A) *Titin (Answer)*: Titin is a massive elastic protein that anchors the thick filament (myosin) to the Z disk.

It provides structural stability and elasticity to the sarcomere and prevents overstretching of the muscle.

(B) *Nebulin*: Associates with thin filaments (actin) to regulate their length.

(C) *Myomesin*: Found in the M line to stabilize thick filaments.

(D) *α -Actinin*: Primarily anchors thin filaments (actin) to the Z disk.

(E) *Troponin*: Part of the thin filament complex involved in regulation of contraction & Ca^{2+} binding.

68) The distance between z-lines is equivalent to the length of the:

A- M line.

B- A band.

C- Sarcomere.

D- H band.

➤ *Explanation:*

(A) *M line*: The center of sarcomere, it serves as an attachment site for thick filaments (myosin).

(B) *A band*: The dark region containing thick filaments (myosin); its length stays constant during contraction.

(C) *Sarcomere (Answer)*: The sarcomere is defined as the segment between two consecutive Z-lines; it is the functional unit of muscle contraction in striated muscle, when the muscle contracts, sarcomere shortens.

(D) *H band*: The region within the A band with only thick filament, it shortens during contraction.

69) Why does stair-case phenomenon occur?

A- High K, low Ca.

B- High temperature, high Ca, low K and high Na.

C- High K, low Na.

D- Low temperature, high Ca, low K and high Na.

➤ *Explanation:*

(A) *High K, low Ca*: This combination typically reduces muscle excitability and contractility.

(B) High temperature, high Ca, low K and high Na (Answer): The Treppe effect occurs because:

1. Ca^{2+} builds up in the cytosol with rapid stimuli, enhancing binding, leading to contraction.
2. Higher temperature increases ATPase activity and speed of contraction.
3. Ionic balance (low K, high Na) optimizes membrane excitability, making muscle fibers more responsive to stimuli.

(C) High K, low Na: Reduces the ability to generate action potentials by affects depolarization of the membrane

(D) Low temperature slows down the enzymatic processes needed for strong contraction, by reducing the efficiency of ATPase.

70) Melanocytes are located in:

- A- Stratum corneum.
- B- Stratum granulosa.
- C- Stratum lucidum.
- D- Stratum spinosum.
- E- Stratum basale.

➤ Explanation:

(A) Stratum corneum: Top layer of dead, keratinized cells.

(B) Stratum granulosa: Layer where keratohyaline granule and filaggrin.

(C) Stratum lucidum: Found only in thick skin (palms/soles), made of flattened keratinocytes.

(D) Stratum spinosum: Layer where cells start to flatten; contains Langerhans cells.

(E) Stratum basale (Answer): The deepest layer of the epidermis where melanocytes sit and produce melanin to protect against UV. Melanocytes synthesize melanin in melanosomes and transfer it to keratinocytes.

71) Most common complication of open fracture is:

- A- Infection.
- B- Compartment syndrome.
- C- Avascular necrosis.
- D- Fat embolism syndrome.
- E- Non-union.

➤ Explanation:

(A) Infection (Answer): 1. In open fractures, the skin barrier is broken, exposing bone to bacteria.

2. Most common pathogen is staphylococcus aureus.

3. Risk factor: Delay in wound management, inadequate debridement and poor blood supply.

(B) Compartment syndrome: More typical in closed high-energy injuries.

(C) Avascular necrosis: more common in closed fractures results from loss of blood supply to the bone.

(e.g. femoral head, scaphoid)

(D) Fat embolism: Associated with long bone fractures (e.g. femur/tibia) but less frequent than infection.

(E) Non-union: A long-term healing complication.

Open fracture is a fracture in which the bone breaks through the skin, exposing bone to external environment. Osteomyelitis is the most frequent and serious immediate complication.

72) The carbohydrate metabolism error that affect mainly on ATP is:

- A- Debrancher enzyme deficiency.
- B- Phosphofructokinase deficiency.
- C- Myo-adenylate deaminase deficiency.
- D- Lactate dehydrogenase deficiency.
- E- Acid maltase deficiency.

➤ *Explanation:*

- (A) *Debrancher enzyme deficiency: Affects glycogen breakdown but allows some ATP production.*
- (B) *Phosphofructokinase deficiency (Answer): PFK is the rate-limiting step of glycolysis. Deficiency severely impairs the production of ATP from glucose, especially during exercise. Affected individuals experience exercise intolerance, muscle cramps, myoglobinuria due to poor energy supply.*
- (C) *Myo-adenylate deaminase deficiency: Affects the purine nucleotide cycle, causing fatigue but not through the glycolysis-ATP pathway directly.*
- (D) *Lactate dehydrogenase deficiency: Impairs anaerobic glycolysis but ATP can still be produced.*
- (E) *Acid maltase deficiency: A lysosomal storage disease (Pompe disease) affecting muscle structure more than direct ATP flux, leadind to muscle weakness.*

73) All of the following hormones decrease calcium, EXCEPT:

- A- Calcitonin.
- B- Thyroid hormone.
- C- Cortisol.
- D- Parathyroid hormone.

➤ *Explanation:*

- (A) *Calcitonin: Directly lowers blood calcium by inhibiting bone resorption (osteoclasts) and increasing calcium excretion by the kidneys.*
- (B) *Thyroid hormone: High levels can cause calcium loss from bone.*
- (C) *Cortisol: Reduces intestinal absorption of calcium.*
- (D) *Parathyroid hormone (Answer): PTH increases blood calcium levels by stimulating bone breakdown, renal reabsorption and vitamin D activation that enhances intestinal calcium absorption.*

74) Treatment of trichenilosis is:

- A- Pentostam.
- B- Mebendazole.
- C- Ivermectin.
- D- Ketoconazole.
- E- Fluconazole.

Trichinellosis (Trichinosis) is a parasitic infection caused by Trichinella spiralis, typically acquired from consuming undercooked or raw meat (especially pork or wild game) containing larvae.

➤ *Explanation:*

- (A) *Pentostam: Used for Leishmaniasis.*

(B) Mebendazole (Answer): An anti-helminthic drug that kills the *Trichinella* larvae by inhibiting their microtubule formation, killing the larvae.

(C) Ivermectin: Used for treatment of other parasites like river blindness, stryngiloidiasis and scabies.

(D/E) Ketoconazole/Fluconazole: Antifungal agents.

75) Regarding injuries all the following statements are correct except:

A- Accidents are an unexpected events, implies a random and uncontrollable event.

B- Interpersonal violence are the leading cause of injury-related deaths worldwide.

C- Both unintentional and intentional injuries are viewed as largely preventable events.

D- Injuries may be blunt or penetrating.

E- Disability-Adjusted Life Year (DALY) is the indicator used to quantify the loss of healthy life.

➤ Explanation:

A. The term "accident" suggests an unintended and unforeseen event. However, in injury prevention, we recognize that most injuries are predictable and preventable rather than purely "random."

B. (Answer) While interpersonal violence (homicide, assaults, etc.) is a significant cause of injury-related deaths, it is not the leading cause worldwide. Instead, road traffic accidents (RTAs) are the primary cause of injury-related deaths globally, followed by falls and self-harm (suicide attempts).

C. Unintentional injuries (e.g., RTAs, falls, burns) and intentional injuries (e.g., violence, self-harm) can often be prevented through safety measures, policies, and interventions.

D. Blunt trauma (e.g., from falls, motor vehicle crashes) vs. penetrating trauma (e.g., gunshot wounds, stab injuries).

E. $DALY = \text{Years of Life Lost (YLL)} + \text{Years Lived with Disability (YLD)}$. It is widely used to measure the burden of diseases, including injuries.

76) Regarding Musculo-skeletal injury; which one of the following statements is wrong:

A- Death rates due to injury tend to be higher in those in the higher income groups.

B- Injuries, unintentional or intentional, constitute a major public health problem.

C- Injuries killing many people worldwide and causing many more cases of disability.

D- People from all economic groups suffer fatal injuries.

E- The poor are also less likely to make a full recovery following an injury.

➤ Explanation:

A. (Answer) In fact, death rates due to injury are generally higher in lower-income groups rather than in higher income groups. The reasons for this are multifactorial, including lack of access to quality healthcare, poorer living conditions, and higher-risk occupations in lower-income populations. Higher income groups often have better access to medical care, safer living conditions, and the resources to prevent or manage injuries.

B. Injuries are a leading cause of death and disability worldwide. Unintentional injuries (e.g., road traffic accidents) and intentional injuries (e.g., violence, self-harm) are significant public health challenges.

C. Injuries account for millions of deaths annually and result in significant disability, making them a major cause of morbidity worldwide.

D. Injuries affect people from all economic backgrounds, but certain groups may be at higher risk due to factors like occupation, access to healthcare, and living conditions.

E. Economic status plays a role in recovery. Lower-income individuals often have less access to healthcare, rehabilitation, and support services, which can hinder their recovery.

77) Desmoid fibromatosis percentage of B-catenin mutation is:

- A- 5%
- B- 10%
- C- 20%
- D- 30%
- E- 90%

** β -catenin mutations are a key feature in the pathogenesis of desmoid tumors, leading to abnormal signaling and cell growth.*

➤ *Explanation:*

(E) 90% (Answer): Desmoid fibromatosis is a type of soft tissue tumor that is characterized by the overgrowth of fibrous tissue. It is often associated with mutations in the CTNNB1 gene, which encodes β -catenin. The majority of desmoid fibromatosis cases show a β -catenin mutation in the Wnt signaling pathway, with estimates suggesting that about 90% of cases have this mutation.

78) One of the following rules must not be taken into consideration when adapting the job to the worker:

- A- Flexibility all begin to diminish upon reaching the age of 45.
- B- Weight and mass tend to increase throughout the age of the early fifties (50).
- C- Height begins to slowly diminish from the age of 30.
- D- Lower back pain is more common in people 25 years of age and older.
- E- Visual acuity at close range diminishes with age.

➤ *Explanation:*

A. As people age, flexibility decreases, so this should be considered when designing jobs that involve physical tasks.

B. With age, weight often increases due to changes in metabolism, so it's important to consider this when adapting work environments.

C. Height decreases gradually with aging due to changes in the bones and cartilage, which should be taken into account when designing ergonomic tools or workspaces.

D. When adapting a job to a worker, it is important to consider factors such as age-related changes in flexibility, height, weight, and visual acuity. However, lower back pain tends to become more common in individuals as they age, but it is typically not more prevalent in people as young as 25 years of age. Lower back pain tends to be more common in older adults due to degenerative changes in the spine, muscle weakness, and other factors associated with aging. Thus, 25 years of age is generally too young for lower back pain to be considered a primary concern when adapting jobs to the worker.

E. As people age, near vision often declines (presbyopia), which is crucial when designing workstations, particularly those that require close-up vision.

79) A 3 boy patient has fever and cough with coryza and conjunctivitis, after while a rash begins from hair line spreading through out the trunk and body, the best diagnosis is:

- A- Rubella.
- B- German Measles.
- C- Roseola.
- D- Slapped cheek.
- E- Chicken pox.

➤ Explanation:

The clinical features described in the question (fever, cough, coryza (runny nose), and conjunctivitis, and a rash that starts from the hairline and spreads to the trunk and body) are highly suggestive of Rubeola (German Measles).

A. (Answer) Rubella typically presents with a prodrome of fever, cough, coryza (runny nose), and conjunctivitis. Following this, a maculopapular rash usually appears, starting at the hairline and then spreading downwards to the trunk and extremities. The rash is often lighter in color compared to the measles rash. Rubella is generally a milder disease than measles, but it is still important to diagnose it early because it can cause congenital rubella syndrome in pregnant women.

B. This is another name for Rubella, so it's actually the same condition as option A. The answer is misleading.

C. Typically presents with high fever followed by a maculopapular rash, but the rash usually appears after the fever subsides and the rash starts on the trunk, not the hairline.

D. Refers to erythema infectiosum (Fifth disease), caused by parvovirus B19, and presents with a "slapped cheek" rash followed by a lacy, erythematous rash on the body, typically without the associated symptoms of fever, cough, coryza, and conjunctivitis.

E. Caused by the varicella virus, chickenpox usually begins with a generalized itchy rash with lesions at different stages (papules, vesicles, scabs), not starting from the hairline and spreading as described in the question.

80) Which of the following is incorrect regarding osteoarthritis diagnosis by X-ray image?

- A- Osteophytes.
- B- Narrowing between joint bone.
- C- Bone necrosis.
- D- Bone cyst.
- E- Cartilage sclerosis.

➤ Explanation:

A. These are bone spurs that form at the edges of joints and are a hallmark of osteoarthritis. They develop as a result of joint degeneration and are commonly seen on X-rays.

B. This is another classic sign of osteoarthritis, indicating the loss of articular cartilage between the bones, which leads to reduced joint space on an X-ray.

C. (Answer) Bone necrosis (or osteonecrosis) is not a typical feature of osteoarthritis. It is a condition where bone tissue dies due to a lack of blood supply, and it is more commonly associated with conditions like avascular necrosis rather than osteoarthritis. OA is more characterized by degenerative changes in the joint structures, but not by the death of bone tissue.

D. Subchondral bone cysts are often seen in osteoarthritis. These are fluid-filled sacs that form in the bone near the joint and appear on X-rays as well-defined areas of decreased density.

E. This refers to an increase in bone density under the cartilage, also known as subchondral sclerosis, which is another common finding in osteoarthritis and appears as areas of increased opacity on X-rays.

81) Inhibition of P53 gene and retinoblastoma gene is associated with:

A- HSV.

B- HHV.

C- B19.

D- HPV.

➤ Explanation:

The p53 gene and the retinoblastoma (Rb) gene are critical tumor suppressor genes involved in regulating the cell cycle and preventing uncontrolled cell division, which can lead to cancer. Inhibition or mutation of these genes can contribute to cancer development.

A. While HSV can cause infections like cold sores and genital herpes, it does not typically inhibit p53 or Rb genes. It primarily uses other mechanisms to evade the immune response.

B. This refers to a family of viruses, including Epstein-Barr Virus (EBV), which can cause cancers like Burkitt's lymphoma, but not all HHV types are associated with inhibition of p53 or Rb. Specifically, EBV does influence cell cycle regulation but not through the same mechanism as HPV.

C. This virus is primarily associated with conditions like erythema infectiosum ("fifth disease") and aplastic crisis in immunocompromised individuals but is not directly linked to the inhibition of p53 or Rb genes.

D. (Answer) Human Papillomavirus (HPV) is known to inhibit both p53 and Rb tumor suppressor genes. Specifically, the high-risk types of HPV (such as HPV-16 and HPV-18) produce proteins (E6 and E7) that bind to and inactivate p53 and Rb proteins, respectively, leading to cell cycle dysregulation and increased cancer risk, particularly in the development of cervical cancer and other HPV-associated cancers.

82) A 2 year old child has generalised rash affect on his trunk then to the face and extremities.

The causative virus of his state is:

A- Rubeola.

B- B19.

C- Roseola.

D- HPV.

E- Rubella.

➤ Explanation:

A. Measles causes a maculopapular rash that typically starts on the face (behind the ears and along the hairline) and spreads downward to the trunk and extremities. It is often preceded by Koplik spots and can be accompanied by cough, coryza, and conjunctivitis, unlike roseola.

B. Parvovirus B19 is associated with erythema infectiosum (fifth disease), which presents as a "slapped cheek" rash followed by a lace-like rash on the body. It does not present with the same rash progression as roseola.

C. (Answer) Roseola, also known as exanthem subitum, is a viral infection that typically affects children between the ages of 6 months and 2 years. The sequence of symptoms usually begins with a high fever that lasts for 3-5 days, followed by the sudden appearance of a rash once the fever subsides. The rash usually starts

on the trunk and then spreads to the face and extremities. Causative agent: The virus responsible for roseola is the Human Herpesvirus 6 (HHV-6), and occasionally HHV-7.

D. HPV typically causes warts and is not associated with a generalized viral rash like the one described here.

E. Rubella, also known as German measles, causes a maculopapular rash that usually starts on the face and spreads downward, but it is not typically associated with the fever pattern seen in roseola.

83) One of the following is short acting non-depolarizing NMB:

A- Succinylcholine.

B- Mivacurium.

C- Atracurium.

D- Pancuronium.

E- Rocuronium.

➤ *Explanation:*

A. Succinylcholine is a depolarizing NMB, not a non-depolarizing one. It causes prolonged depolarization of the muscle membrane, resulting in muscle paralysis.

B. (Answer) Mivacurium is a short-acting non-depolarizing neuromuscular blocker (NMB). Non-depolarizing NMBs work by blocking the acetylcholine receptors at the neuromuscular junction, preventing depolarization of the muscle and muscle contraction. Mivacurium has a short duration of action due to its rapid metabolism by plasma cholinesterase.

C. Atracurium is an intermediate-acting non-depolarizing NMB. It has a longer duration of action compared to mivacurium.

D. Pancuronium is a long-acting non-depolarizing NMB. It has a much longer duration of action compared to mivacurium.

E. Rocuronium is an intermediate-acting non-depolarizing NMB. While it has a shorter duration than pancuronium, it is still longer acting than mivacurium.

84) All of the following are therapeutic use of acetaminophen except:

A- Anti-platelet effect.

B- Mild to moderate pain.

C- Anti-pyretic effect.

D- Substitute for analgesic and anti-pyretic effect of aspirin.

E- Patient with peptic ulcer.

➤ *Explanation:*

A. (Answer) Acetaminophen (Paracetamol) is a commonly used analgesic and antipyretic medication. It works by inhibiting cyclooxygenase enzymes, particularly in the brain, to relieve pain and reduce fever. However, it does not have a significant anti-platelet effect, which is typically associated with aspirin.

B. Acetaminophen is effective for relieving mild to moderate pain, such as headaches, musculoskeletal pain, or pain associated with conditions like osteoarthritis.

C. Acetaminophen is widely used as a fever reducer (antipyretic) by acting on the hypothalamic heat regulating center.

D. Acetaminophen can be used as a substitute for aspirin in patients who cannot tolerate aspirin, especially those with conditions like peptic ulcers or those at risk for gastrointestinal bleeding.

E. Acetaminophen is preferred over aspirin or nonsteroidal anti-inflammatory drugs (NSAIDs) in patients with peptic ulcers because it has a lower risk of causing gastric irritation or bleeding.

85) The pro collagen - α chains undergo hydroxylation reactions in the lumen of the RER while the polypeptides are still being synthesized, these reactions require all of the following, EXCEPT?

A- Molecular oxygen

B- Fe^{2+}

C- The reducing agent vitamin C (ascorbic acid)

D- Prolyl hydroxylase and lysyl hydroxylase

E- Lysyl oxidase

➤ Explanation:

A. Molecular oxygen is required for hydroxylation reactions in collagen synthesis, as it is used by prolyl hydroxylase and lysyl hydroxylase to hydroxylate proline and lysine residues.

B. Iron (Fe^{2+}) is a cofactor for the prolyl hydroxylase and lysyl hydroxylase enzymes, enabling the hydroxylation of proline and lysine in collagen chains.

C. Vitamin C is essential for maintaining the activity of prolyl hydroxylase and lysyl hydroxylase by keeping the iron in its reduced state (Fe^{2+}), facilitating the hydroxylation process.

D. These enzymes catalyze the hydroxylation of proline and lysine residues, respectively, in the collagen chains.

E. Correct answer: Lysyl oxidase is not involved in the hydroxylation process. It is responsible for the cross-linking of collagen fibers by oxidizing lysine residues after hydroxylation, but it is not required for the hydroxylation of collagen itself.

86) Which one of the following injuries resulted from an insufficiency of a vital element?

Select one:

A- Chemical

B- Thermal

C- Mechanical

D- Strangulation

E- Electrical

➤ Explanation:

A. Chemical: This type of injury results from exposure to toxic chemicals or substances, not from an insufficiency of a vital element.

B. Thermal injuries are caused by extreme temperatures (heat or cold), not from a lack of any vital element.

C. Mechanical injuries involve physical force or trauma, such as cuts, bruises, or fractures, not related to an insufficiency of a vital element.

D. Correct answer: Strangulation causes a lack of oxygen to vital organs, particularly the brain, due to the obstruction of blood vessels or airways. This injury directly results from the insufficiency of oxygen, a vital element.

E. Electrical injuries are caused by exposure to electric current, not from an insufficiency of a vital element.

87) One of the following statement is true about the skeletal muscle contraction:

A- Phosphorylation is activated during contraction to get binding of actin to myosin

B- Muscle contraction never continue after death of the subject

C- Calcium ion should bind tropomyosin to get contraction of the muscle

D- Tension in the muscle is proportional to the number of cross bridges

E- Treppe indicate rapid fatigue in the muscle

➤ Explanation:

A. Phosphorylation (such as of myosin light chain in smooth muscle) is not required for binding of actin to myosin in skeletal muscle. In skeletal muscle, binding is regulated by calcium ions, which allow tropomyosin to expose the binding sites on actin for myosin.

B. After death, rigor mortis occurs, which is a state where muscles contract due to the lack of ATP, leading to muscle stiffness. So contraction can continue temporarily after death.

C. Calcium binds to troponin, not tropomyosin. When calcium binds to troponin, it causes a conformational change that moves tropomyosin away from the binding sites on actin, allowing myosin to bind to actin and cause contraction.

D. Correct answer: The force generated during muscle contraction is directly related to the number of cross-bridges formed between actin and myosin. More cross-bridges lead to greater tension.

E. Treppe, also known as the "staircase effect," refers to a phenomenon where muscle contractions become stronger with each successive stimulus when a muscle is stimulated at a low frequency. It does not indicate rapid fatigue; in fact, it suggests increasing efficiency of muscle contraction at that particular frequency.

88) All of the following are anterior relations of the ankle joint except?

A- Extensor hallucis longus

B- Peroneus longus

C- Tibialis anterior

D- Extensor digitorum longus

E- Anterior tibial Nerve

➤ Explanation:

A. Extensor hallucis longus: This muscle is an anterior relation of the ankle joint. It runs along the anterior aspect of the ankle and is responsible for extending the big toe.

B. Correct answer (b): This muscle is not an anterior relation of the ankle joint. It is located on the lateral side of the lower leg and passes behind the lateral malleolus to insert into the foot. It is not in the anterior region.

C. Tibialis anterior: This is an anterior relation of the ankle joint. It is located in the front of the lower leg and is responsible for dorsiflexing the foot.

D. Extensor digitorum longus: This muscle is also an anterior relation of the ankle joint. It lies in front of the ankle and helps in extending the toes.

E. Anterior tibial Nerve: This nerve is an anterior relation of the ankle joint, running in front of the ankle and providing sensation to the foot and toes.

89) Which of the followings called red gem?

A- Furuncles

B- Carbuncles

C- Cellulitis

D- Folliculitis

E- Impetigo

➤ Explanation:

A. Furuncles: Also known as boils, are deep infections of hair follicles.

B. Correct answer (b): A carbuncle is a collection of boils (furuncles) that are connected under the skin. They are sometimes called "red gems" due to their appearance as inflamed, red, and swollen masses on the skin.

C. Cellulitis is a bacterial skin infection that affects the deeper layers of the skin.

D. Folliculitis: Inflammation of hair follicles.

E. Impetigo: A superficial bacterial skin infection, usually caused by staphylococci or streptococci.

90) All the following are true about Celecoxib except?

A- It is prescribed for patients who are at high risk of NSAIDs-induced ulcer

B- It blocks prostaglandins synthesis by preferential inhibition of Cox-2 isoform

C- It may cause urticaria and angioedema in sulphonamide hypersensitive patients

D- It may increase the risk of cardiovascular events

E- It has less to none gastrointestinal effects

➤ Explanation:

* Celecoxib is a selective COX-2 inhibitor, meaning it reduces inflammation and pain while minimizing gastrointestinal (GI) side effects compared to non-selective NSAIDs. However, it does not completely eliminate GI effects, especially with long-term use.

*Correct answer (E): While Celecoxib has fewer gastrointestinal effects compared to traditional NSAIDs, it still poses a risk of gastric irritation, ulceration, and bleeding, especially in high doses or long-term use.

91) All the following are disease modifying antirheumatic drugs, EXCEPT?

A- Methotrexate

B- Leflunomide

- C- Infliximab
- D- Anakinra
- E- Celecoxib

➤ *Explanation:*

A. Methotrexate – DMARD (First-line for RA)

B. Leflunomide – DMARD (Inhibits pyrimidine synthesis, reducing T-cell proliferation)

C. Infliximab – DMARD (Anti-TNF biologic used in autoimmune diseases)

D. Anakinra – DMARD (IL-1 receptor antagonist used in RA)

E. Correct answer : Celecoxib is an NSAID (specifically a COX-2 inhibitor), not a DMARD. It treats pain and inflammation but does not modify the long-term course of the disease.

Disease-Modifying Antirheumatic Drugs (DMARDs) are a group of medications that slow the progression of rheumatoid arthritis (RA) and other autoimmune diseases by modifying the underlying disease process, rather than just treating symptoms.

92) Which of the followings is INCORRECT?

A- In erysipelas, blistering is common associated with hemorrhage into the blister or in intact skin.

B- Sever cellulitis may show bullae and can progress to dermal necrosis.

C- Both cellulitis and erysipelas can progress without treatment into fasciitis, myositis, subcutaneous abscesses, and septicemia.

D- The redness spreads 3 inches in 6 hours in confirmed necrotizing fasciitis.

E- Ecthyma is a localized scalded skin syndrome.

➤ *Explanation:*

A. In erysipelas, blistering is common associated with hemorrhage into the blister or in intact skin. True (Blisters and hemorrhagic lesions can occur in severe cases of erysipelas.)

B. Bullae formation and necrosis indicate severe infection

C. Untreated cases can lead to life-threatening complications.

D. Necrotizing fasciitis is rapidly progressing, spreading inches within hours.

E. Correct answer : Ecthyma is a deep form of impetigo, typically caused by *Streptococcus pyogenes*, leading to ulcerative lesions with thick, adherent crusts. It is not related to scalded skin syndrome. Staphylococcal scalded skin syndrome (SSSS) is caused by exfoliative toxins of *Staphylococcus aureus*, leading to widespread skin peeling, not ecthyma.

93) Which of the following ligaments of TMJ attached to the lingula of mandible?

A- Stylomandibular ligament

B- Pterygomandibular ligament

C- Tempromandibular ligament

D- Sternomandubalr ligament

E- Sphenomandibular ligament

➤ *Explanation:*

A. Stylomandibular ligament: Attaches from the styloid process of the temporal bone to the angle of the mandible, not the lingula.

B. Pterygomandibular ligament: Located between the pterygoid process and the mandible, but does not attach to the lingula.

C. Tempromandibular ligament: Connects the zygomatic arch to the mandible but does not attach to the lingula.

D. Sternomandibular ligament: Not associated with the TMJ; it connects the sternum to the mandible.

E. Correct answer : The sphenomandibular ligament attaches to the lingula of the mandible. It is one of the ligaments associated with the temporomandibular joint (TMJ) and plays a role in stabilizing the mandible.

94) Which of the followings is INCORRECT regarding Ecthyma?

A- Ecthyma is a skin infection similar to impetigo but more deeply invasive.

B- The crust in ecthyma is much darker and thicker than impetigo.

C- Ulceration occurs.

D- Healing occurs with scars.

E- The crust is loosely adherent.

➤ Explanation:

Ecthyma is a deep skin infection that is similar to impetigo but more invasive, affecting the epidermis and dermis. It is most commonly caused by *Streptococcus pyogenes* (group A *Streptococcus*) and sometimes *Staphylococcus aureus*.

A. Unlike impetigo, which is superficial, ecthyma extends into the dermis, leading to ulceration.

B. Ecthyma forms thick, dark, and adherent crusts, unlike the honey-colored crusts of impetigo.

C. The deeper invasion leads to ulcers beneath the crust.

D. Due to dermal involvement, ecthyma often heals with scarring.

E. Correct answer : Ecthyma is a deeply invasive form of impetigo, typically caused by *S. pyogenes*.

It is characterized by:

* Vesicles or pustules that evolve into shallow ulcers covered by a thick, adherent crust (not loosely adherent crust as impetigo).

* The crust is dark and thick, often described as "punched out" sores.

* Healing occurs with scarring due to deep dermal involvement.

95) Which of the following is FALSE regarding cellulitis and erysipelas?

A- Cellulitis and erysipelas are caused by *S. pyogenes* and less commonly *S. aureus*.

B- Borders are not clear in the case of cellulitis.

C- Erysipelas has more superficial involvement.


D- Complications without treatment.

E- Cellulitis affect only the epidermis.

➤ Explanation:

* Correct answer (E): Cellulitis affects the deeper layers of the skin, including the dermis and subcutaneous tissue, not just the epidermis.

Common skin infections			
Diagnosis	Erysipelas	Cellulitis	Abscess
Microbiology	<ul style="list-style-type: none">• <i>Streptococcus pyogenes</i>	<ul style="list-style-type: none">• <i>S. pyogenes</i>• MSSA	<ul style="list-style-type: none">• MSSA• MRSA
Clinical manifestation	<ul style="list-style-type: none">• Superficial dermis & lymphatics• Raised with sharply demarcated borders• Rapid onset & spread• Fever, chills common	<ul style="list-style-type: none">• Deep dermis & subcutaneous fat• Ill-defined with flat borders• Indolent course (over days)• ± Fever later in course	<ul style="list-style-type: none">• Dermis or subcutaneous space• Fluctuant, tender nodule• Purulent drainage• ± Fever & surrounding cellulitis

 = methicillin-resistant *Staphylococcus aureus*; MSSA = methicillin-sensitive *S. aureus*.

96) Autoantibodies against tRNA synthetases are found in what disease process?

A- Dermatomyositis.

B- Polymyositis.

C- Inclusion body myositis.

D- Myasthenia gravis.

E- SLE.

➤ *Explanation:*

A. More commonly associated with anti-Mi-2, anti-NXP-2 and anti-TIF-1γ antibodies, not anti-tRNA synthetases.

B. (Answer) *Autoantibodies against tRNA synthetases are characteristic of polymyositis (PM) and anti-synthetase syndrome, which is a subset of idiopathic inflammatory myopathies (IIMs).

* The most well-known anti-tRNA synthetase antibody is anti-Jo-1, which targets histidyl-tRNA synthetase.

* Other anti-synthetase antibodies include PL-7, PL-12, EJ, and OJ, each targeting different aminoacyl-tRNA synthetases.

* Anti-synthetase syndrome is associated with myositis, interstitial lung disease (ILD), arthritis, Raynaud's phenomenon, and mechanic's hands.

C. Has no strong association with autoantibodies.

D. Associated with anti-AChR or anti-MuSK antibodies, not tRNA synthetase antibodies.

E. Characterized by ANA, anti-dsDNA, anti-Sm, and antiphospholipid antibodies, not anti-tRNA synthetases.

97) Carpal tunnel syndrome is characterized by the following symptoms except?

A- Wasting of the muscles moved the thumb

B- Night time symptoms is very common

C- Weakness of thumb adduction

D- Difficult to button the clothes

E- Numbness and tingling sensation in the nail bed of lateral three and half fingers

➤ *Explanation:*

* Carpal tunnel syndrome (CTS) results from compression of the median nerve as it passes through the carpal tunnel. This leads to sensory and motor dysfunctions in the distribution of the median nerve.

* The median nerve primarily controls thumb apposition, flexion and abduction, but not adduction

* Correct answer (C): Thumb adduction is controlled by the adductor pollicis muscle, which is innervated by the ulnar nerve, not the median nerve.

* The median nerve supplies sensory sensation to the thumb, index, middle, and lateral half of the ring finger.

98) A patient came to skin and venereal department complaining from greying of hair and localized white skin patches, the most probable diagnosis is?

A- Xeroderma pigmentosum

B- Leukoderma

C- Albinism

D- Malignant melanoma

E- Marfan syndrome

➤ *Explanation:*

A. *This is a rare genetic disorder that leads to extreme sensitivity to UV light, causing freckling, skin cancers, and pigmentation abnormalities, but not isolated white patches and greying of hair.*

B. *Correct answer: Also called (vitiligo) is a condition characterized by localized depigmented patches of skin due to the destruction of melanocytes. Poliosis (localized whitening of hair) is commonly associated with leukoderma.*

C. *Albinism is a genetic disorder causing a complete or generalized loss of melanin from birth, affecting the entire body, not just localized patches.*

D. *Malignant melanoma is a skin cancer that typically presents as a changing pigmented lesion, not white patches or grey hair.*

99) The following enhance the therapeutic potency of topical steroids except:

A- Fluorination

B- Esterification

C- Lotion vehicle

D- Concentration

E- Occlusive dressing

➤ *Explanation:*

A. *Fluorination: Fluorination enhances the potency of topical steroids by increasing their ability to penetrate the skin and bind to glucocorticoid receptors.*

B. *Correct answer (B): While esterification can influence the solubility and absorption of steroids, it is not a common strategy for increasing potency in topical formulations, it's not a factor directly enhances the therapeutic potency of topical steroids.*

C. *Lotion vehicle: The formulation of the steroid (whether cream, ointment, or lotion) affects how well the medication is absorbed and how effective it is. Lotions can be less potent compared to more occlusive formulations like ointments, but they still contribute to efficacy.*

D. *Concentration: Higher concentrations of steroids lead to more potent effects because more active medication is available for absorption.*

E. *Occlusive dressing: Applying an occlusive dressing over topical steroids can enhance their absorption by preventing evaporation, making them more effective.*

100) Which of the following is INCORRECTLY paired?

A- White muscle fibres--- more mitochondria

B- White muscle fibres--- found in extraocular muscles

C- Red muscle fibres---thin

D- White muscle fibre--- contract fast

E- Red muscle fibres--- tire slowly

➤ *Explanation:*

A. Correct answer: * White muscle fibers (Type II fibers) have fewer mitochondria and are adapted for rapid, powerful contractions but fatigue quickly. They primarily rely on anaerobic metabolism.

* Red muscle fibers (Type I fibers) are rich in mitochondria and are suited for endurance activities. They use aerobic metabolism and can sustain contraction for longer periods without tiring.

B. White muscle fibers are found in muscles involved in quick, powerful movements (such as in the extraocular muscles), hence the pairing in option b is correct.

C. Red muscle fibers are generally thinner than white muscle fibers.

E. Red muscle fibers tire slowly, as they are more resistant to fatigue.

101) Which fused in the midline during formation of the palate?

A- The palatal processes arise from maxillary processes with the median nasal process

B- The palatal processes arise from maxillary processes with each other and the nasal septum

C- The palatal processes arise from maxillary processes with the primary palate

D- The palatal processes arise from maxillary processes with each other

E- The palatal processes arise from maxillary processes with the premaxilla

➤ Explanation:

A. This is incorrect because the fusion involves the palatal processes from both maxillary processes and the nasal septum, not the median nasal process.

B. Correct answer: *The palatal processes are part of the maxillary processes and they grow towards each other during fetal development. These processes fuse in the midline to form the secondary palate.

* In the process, the palatal processes fuse not only with each other but also with the nasal septum, which helps to separate the oral and nasal cavities.

C. This is incorrect because the fusion involves the maxillary processes and the palatal processes, but not directly the primary palate.

D. This is incomplete because it doesn't mention the involvement of the nasal septum.

E. This option is incorrect as the premaxilla (which forms part of the primary palate) is not directly involved in the fusion of the palatal processes.

102) Complications of Paget's disease include all of the following except?

A- Osteosarcoma

B- Deafness and heart failure.

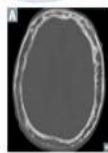
C- Nerve root compression.

D- Fractures and bony deformity.

E- Liver failure.

➤ Explanation:

Osteitis deformans



Also called Paget disease of bone. Common, localized disorder of bone remodeling caused by ↑ osteoclastic activity followed by ↑ osteoblastic activity that forms poor-quality bone. Serum Ca^{2+} , phosphorus, and PTH levels are normal. ↑ ALP. Mosaic pattern of woven and lamellar bone (osteocytes within lacunae in chaotic juxtapositions); long bone chalk-stick fractures. ↑ blood flow from ↑ arteriovenous shunts may cause high-output heart failure. ↑ risk of osteosarcoma.

Hat size can be increased due to skull thickening

☒ hearing loss is common due to skull deformity.

Stages of Paget disease:

- * Early destructive (lytic): osteoclasts
- * Intermediate (mixed): osteoclasts + osteoblasts
- * Late (sclerotic/blastic): osteoblasts

May enter quiescent phase.

Treatment: bisphosphonates.

* Correct answer (E): Liver failure is not a complication of Paget's disease.

103) The normal passage of the oblique inguinal hernia is?

- A- Inguinal triangle to inguinal canal to superficial ring
- B- Behind the spermatic cord
- C- Inguinal triangle to inguinal canal to deep ring
- D- Deep inguinal ring to inguinal canal to superficial ring
- E- Downward, forward and medially through inguinal triangle

➤ Explanation:

- A. The passage of an oblique inguinal hernia is not from the inguinal triangle to the superficial ring.
- B. The hernia does not pass behind the spermatic cord.
- D. Correct answer: * The oblique inguinal hernia passes through the deep inguinal ring, then through the inguinal canal, and finally exits through the superficial inguinal ring. This path follows the normal course of the inguinal canal.

* Oblique inguinal hernias are typically lateral to the inferior epigastric vessels and follow this route.

104) Tacrolimus and pimecrolimus are both used for treatment of the following disease?

- A- Acne vulgaris
- B- Psoriasis
- C- Eczema responding to usual treatment
- D- Refractory eczema
- E- Hair falling diseases

➤ Explanation:

- A. These drugs are not used for acne.
- B. They are not the primary treatment for psoriasis.
- C. They are typically used for refractory cases, not when eczema is responding to usual treatment.
- D. Correct answer: * Tacrolimus and pimecrolimus are topical calcineurin inhibitors used for the treatment of eczema, particularly in cases that are refractory to conventional treatments such as corticosteroids.

* They work by inhibiting the activation of T-cells and reducing inflammation in the skin.

* These medications are typically used when steroid treatments are not effective or when long-term steroid use is not ideal.

105) Suspicion of a torn or ruptured muscle is seen in?

- A- Folliculitis.
- B- Impetigo.

C- Necrotizing fasciitis.

D- Cellulitis.

E- Erysipelas.

➤ *Explanation:*

A. Infection of hair follicles, usually does not involve muscle damage.

B. Superficial skin infection, often affecting children, not involving muscle.

C. Correct answer: Necrotizing fasciitis is a severe, rapidly progressing soft tissue infection that often involves muscle tissue and can result in muscle necrosis. It can cause the tearing or rupturing of muscles due to the rapid tissue destruction.

D. Infection of deeper layers of the skin, but muscle rupture is not a typical feature.

E. A superficial skin infection with raised borders, usually does not affect muscles.

106) The three major functional classes of articulations are:

A- Symphysis, syndesmosis, epiphyseal growth plate

B- Synarthrosis, amphiarthrosis, diarthrosis

C- Gomphosis, synchondrosis, synostosis

D- Syndesmosis, symphysis, amphiarthrosis

E- Monaxial, biaxial, triaxial

➤ *Explanation:* *Correct answer (B).

* These are the three major functional classes of articulations based on the amount of movement allowed:

1- Synarthrosis: An immovable joint (e.g., sutures in the skull).

2- Amphiarthrosis: A slightly movable joint (e.g., intervertebral joints).

3- Diarthrosis: A freely movable joint (e.g., shoulder, knee).

107) All the following determines the pharmacologic response of topical drugs, Except?

A- Lipophilicity of drug

B- Slowest absorption occurs from palms than in face.

C- Drug diffusion is high through dry skin than wet skin.

D- Concentration of active ingredient

E- Type of skin disease

➤ *Explanation:*

A. Lipophilic drugs are more easily absorbed through the skin as the skin is lipophilic, so this determines the pharmacologic response.

B. The skin on the palms and soles is thicker, making drug absorption slower compared to thinner skin, such as on the face.

C. Correct answer: Drug diffusion is higher through wet skin than dry skin because moisture can facilitate the passage of the drug through the stratum corneum, which is less efficient when the skin is dry. Therefore, option c is the incorrect statement.

D. A higher concentration of the active ingredient typically leads to a stronger pharmacologic response.

E. The condition of the skin (e.g., inflammation, intactness) affects drug absorption and its therapeutic response.

108) Paralysis of each muscles leading to patient climbs on himself?

- A- Paralysis of the gluteus maximus
- B- Paralysis of the hamstring muscles
- C- Paralysis of the gluteus minimus
- D- Paralysis of the quadratus femoris
- E- Paralysis of the gluteus medius

➤ *Explanation:*

* The gluteus medius muscle is responsible for stabilizing the pelvis during walking and running. If it is paralyzed, a condition called Trendelenburg gait can occur, where the pelvis drops on the opposite side when the patient stands or walks. This leads to a compensatory movement, where the patient may have to lean or "climb" over the affected side to maintain balance, which is often referred to as "climbing on themselves." So, (E) is the correct answer.

109) All following matches about biological agents and side effects are true, EXCEPT?

- A- Etanercept - Local site reactions
- B- Infliximab - Pancytopenia
- C- Anakinra - Neutropenia
- D- Rituximab - Liver toxicity
- E- Infliximab - Increase risk of infections

➤ *Explanation:*

Biological agent	Mechanism of action	Common side effects
Etanercept	Tumor necrosis factor (TNF) inhibitor, binds to TNF-alpha and blocks its interaction with receptors.	Local injection site reactions, Increased risk of infections.
Infliximab	Monoclonal antibody that binds to TNF-alpha, preventing it from binding to its receptors.	Pancytopenia, infusion reactions, Increased risk of infections.
Anakinra	Interleukin-1 receptor antagonist, Blocks IL-1 from binding to its receptor.	Neutropenia, injection site reactions, Increased risk of infections.
Rituximab	Monoclonal antibody that targets CD20 on B- cells, leading to B- cell depletion.	Infusion reactions, increased risk of infections, rare cases of progressive multifocal leukoencephalopathy (PML)

* Correct answer (D): Rituximab is a monoclonal antibody that targets CD20 on B-cells, leading to B-cell depletion. Common side effects include infusion reactions, increased risk of infections, and rarely progressive multifocal leukoencephalopathy (PML). It is not typically associated with liver toxicity.

110) A bodily lesion at the organic level, resulting from acute exposure to energy in amounts that exceed the threshold of physiological tolerance called?

- A- Mortality
- B- Disaster
- C- Distress
- D- Morbidity
- E- Injury

➤ *Explanation:*

- A. The occurrence of death within a population; often expressed as a mortality rate, which measures the number of deaths in a given population over a specified time.
- B. A sudden event, such as a natural catastrophe, accident, or conflict, that causes significant damage, destruction, and loss of life, overwhelming the capacity of the affected community to cope.
- C. A state of extreme anxiety, pain, or suffering, which can be physical, emotional, or psychological. In a medical context, distress may refer to conditions such as respiratory distress or emotional distress due to trauma or illness.
- D. The state of having a disease or medical condition; it refers to the incidence or prevalence of a disease within a population. It can also indicate complications or disability resulting from an illness or injury.
- E. Correct answer (E): An injury is defined as a bodily lesion at the organic level caused by acute exposure to energy (such as mechanical, thermal, electrical, chemical, or radiation energy) in amounts that exceed the body's physiological tolerance. Injuries can also result from the lack of vital elements, such as oxygen deprivation.

111) The basement membrane lies between:

- A- stratum basale and stratum spinosum
- B- stratum spinosum and stratum granulosum
- C- stratum granulosum and stratum corneum
- D- epidermis and dermis
- E- papillary and reticular layers of the dermis

➤ *Explanation:*

- A. Both are epidermal layers; the basement membrane is below them.
- B. Both are in the epidermis; no basement membrane between them.
- C. Both are epidermal layers; no basement membrane.
- D. Correct answer (D): The basement membrane separates the epidermis from the dermis, providing structural support and regulating cell behavior.
- E. Both are dermal layers; the basement membrane separates epidermis from dermis, not within the dermis.

112) Ring worm is caused by:

- A- Malassezia furfur
- B- Dermatophytes
- C- Candida Albican

D- *Madurella mycetomatis*

E- *Candida*

➤ *Explanation:*

A. Causes *tinea versicolor* (pityriasis versicolor), not ringworm.

B. Correct answer (B): Ringworm (also called *tinea*) is a fungal infection caused by dermatophytes, a group of fungi that infect keratinized tissues like skin, hair, and nails.

C. Cause candidiasis, not dermatophytosis.

D. Causes mycetoma (*Madura foot*), a deep fungal infection, not ringworm.

113) What are the mean of unlocking the knee joint?

A- Medial rotation of the femur on the tibia when the foot is fixed on the ground

B- It occurs at the end of the flexion by popliteus muscle

C- Lateral rotation of the femur on the tibia when the foot is raised from the ground

D- Medial rotation of the femur on the tibia when the foot is raised from the ground

E- Lateral rotation of the femur on the tibia when the foot is fixed on the ground

➤ *Explanation:*

A. Medial rotation of the femur on the tibia when the foot is fixed on the ground → This is the locking mechanism, not unlocking.

B. Correct answer: * The knee joint locks in full extension due to lateral rotation of the tibia (or medial rotation of the femur when weight-bearing).

* To unlock the knee for flexion, the popliteus muscle contracts, causing medial rotation of the tibia (or lateral rotation of the femur in a weight-bearing position).

C. Lateral rotation of the femur on the tibia when the foot is raised from the ground → The popliteus acts mainly when weight-bearing.

D. Medial rotation of the femur on the tibia when the foot is raised from the ground → The femur rotates laterally, not medially, when unlocking.

E. Lateral rotation of the femur on the tibia when the foot is fixed on the ground → This is part of the locking, not unlocking process.

114) Concerning GOUT, all the following are risk factors, EXCEPT?

A- Alcohol

B- Meat consumption

C- Sea food

D- Obesity

E- Salt Consumption

➤ *Explanation:*

A. Gout is caused by elevated uric acid levels, leading to crystal deposition in joints.

B. Alcohol (especially beer and spirits) increases uric acid production and decreases renal excretion.

C. Meat consumption—Rich in purines, which break down into uric acid.

D. Sea food—High purine content contributes to hyperuricemia.

E. Obesity—Increases uric acid production and decreases renal excretion.

* Correct answer (E): Salt intake is not directly linked to gout. High sodium levels may contribute to hypertension and kidney disease, but they do not directly raise uric acid levels like purine-rich foods do.

115) Regarding the inguinal canal, which is false?

A- It contains ilioinguinal nerve in female

B- It contains spermatic cord in male

C- It contains iliohypogastric nerve in male

D- It contains round ligament of the uterus in female

E- It passes with the direction of external abdominal oblique muscle

➤ Explanation:

* The inguinal canal is a passage in the lower anterior abdominal wall, containing different structures in males and females.

* Structures in the Inguinal Canal:

In males: Spermatic cord & ilioinguinal nerve

In females: Round ligament of the uterus & ilioinguinal nerve

In both sexes: Ilioinguinal nerve (but NOT the iliohypogastric nerve)

* Correct answer (C): The iliohypogastric nerve runs above the inguinal canal, not through it. Instead, the ilioinguinal nerve passes through the canal and supplies sensation to the groin and genital area.

116) What is the most important factor responsible for stability of the shoulder joint?

A- Long head of triceps

B- Glenoid labrum

C- Coracoacromial arch

D- Rotator cuff of muscles

E- Long head of biceps

➤ Explanation:

A. Provides some stability, but its role is minimal compared to the rotator cuff.

B. Deepens the socket but does not provide the primary stability.

C. Prevents superior dislocation but does not stabilize the joint in all directions.

D. Correct answer: The shoulder joint (glenohumeral joint) is highly mobile but relatively unstable due to its shallow socket (glenoid cavity). The most important stabilizing factor is the rotator cuff muscles, which dynamically support the joint by holding the head of the humerus within the glenoid cavity.

E. Helps stabilize the humeral head, but its role is secondary to the rotator cuff.

117) Vitamin D is activated in the kidney by?

A- Parathyroid hormone

B- Calcitonin

C- 7- Dehydrocholesterol

D- 25-Hydroxylase

E- 1- α Hydroxylase

➤ *Explanation:*

A. Parathyroid hormone: Stimulates the activity of 1- α hydroxylase, but it is not directly involved in the activation.

B. Calcitonin: Lowers blood calcium levels and has no direct role in vitamin D activation.

C. 7-Dehydrocholesterol: It is the precursor to vitamin D in the skin, not involved in its activation in the kidneys.

D. 25-Hydroxylase: Converts vitamin D into 25-hydroxyvitamin D in the liver, but not the final step of activation in the kidney.

E. Correct answer: Vitamin D is activated in the kidneys by the enzyme 1- α hydroxylase. This enzyme converts 25-hydroxyvitamin D (the inactive form of vitamin D) into 1,25-dihydroxyvitamin D, the active form of vitamin D, which is crucial for calcium and phosphate regulation in the body.

118) Which muscles of mastication arises from maxillary tuberosity?

A- Superficial head of masseter

B- Lower head of lateral pterygoid

C- Deep head of medial pterygoid

D- Upper head of lateral pterygoid

E- Superficial head of the medial pterygoid

➤ *Explanation:*

A. Superficial head of masseter- Originates from the "zygomatic arch", not the maxillary tuberosity.

B. Lower head of lateral pterygoid - Arises from the "lateral pterygoid plate" of the sphenoid bone, not the maxillary tuberosity.

C. Deep head of medial pterygoid - Originates from the "medial surface of the lateral pterygoid plate" (sphenoid bone), not the maxillary tuberosity.

D. Upper head of lateral pterygoid - Arises from the "greater wing of the sphenoid bone", not the maxillary tuberosity.

E. Correct answer: The superficial head of the medial pterygoid originates from the "maxillary tuberosity" and the pyramidal process of the palatine bone.

119) The dangerous position of the ulnar nerve?

A- Deep to the flexor retinaculum

B- In front of the medial epicondyle of the humerus

C- Back of the medial epicondyle of the humerus

D- In the cubital fossa

E- Back of the lateral epicondyle of the humerus

➤ *Explanation:*

- A. Deep to the flexor retinaculum: The ulnar nerve passes beneath the flexor retinaculum (in the wrist), but this position is not as dangerous as its location around the medial epicondyle.
- B. In front of the medial epicondyle of the humerus: The ulnar nerve does not pass in front of the medial epicondyle. It is located behind the medial epicondyle.
- C. Correct answer: The ulnar nerve is most vulnerable to injury when it passes posteriorly (back) to the medial epicondyle of the humerus, where it is superficial and exposed to trauma. This area is commonly known as the "funny bone" and can lead to a tingling sensation if bumped.
- D. In the cubital fossa: The ulnar nerve does not pass through the cubital fossa. It passes posterior to the medial epicondyle, while the median nerve passes through the cubital fossa.
- E. Back of the lateral epicondyle of the humerus: The ulnar nerve does not pass near the lateral epicondyle; this is where the radial nerve runs.

120) In the visceral smooth muscle?

- A. Stretch cannot induce a contraction
- B. Contain myosin kinase and phosphatase enzymes
- C. Its function is not affected by the autonomic nervous system
- D. The fibers show high electric resistance in-between them
- E. Contain troponin-T

➤ *Explanations:*

- A. Stretch cannot induce a contraction → False. In visceral (single-unit) smooth muscle, stretch can induce contraction due to the myogenic response. This is important in organs like the intestines and blood vessels.
- B. (Correct) Smooth muscle contraction is regulated by myosin light chain kinase (MLCK), which phosphorylates myosin for contraction, and myosin phosphatase, which dephosphorylates myosin to induce relaxation.
- C. Visceral smooth muscle is strongly influenced by the autonomic nervous system (ANS), specifically by sympathetic and parasympathetic inputs.
- D. Visceral smooth muscle cells are connected by gap junctions, allowing low electrical resistance and coordinated contraction.
- E. Smooth muscle lacks troponin; instead, it uses calmodulin to regulate contraction.

121) Which one of the following is an indication for topical use of potent steroids?

- A. Pemphigoid
- B. Seborrheic dermatitis
- C. Alopecia areata
- D. Generalized urticaria
- E. Exfoliative dermatitis

➤ *Explanations:*

- A. (Correct) Potent topical corticosteroids are indicated for autoimmune blistering diseases like bullous pemphigoid, especially in localized cases. They help reduce inflammation and immune activity.

B. Mild to moderate topical steroids (low-potency) can be used, but potent steroids are not necessary. Antifungals like ketoconazole are preferred.

C. Intralesional steroids (triamcinolone injection) are used, but potent topical steroids are not the primary treatment.

D. Urticaria is treated with antihistamines, not steroids. Systemic steroids are only used in severe cases (e.g., angioedema).

E. Systemic steroids are used, not potent topical steroids, because the condition is widespread.

122) A 70-year-old woman has a lesion on the right side of her face. On examination, the 1.5-cm lesion has regular borders, regular brown to black pigmentation. The lesion is resected and microscopically shows nests of melanocytic cells without prominent red nucleoli. Which of the following mutated genes is most likely to be present in the skin lesion of this man?

A. Melanocytic nevi

B. Squamous cell carcinoma

C. Lichen planus

D. Melanoma

E. Basal cell carcinoma

➤ Explanations:

A. (Correct) Microscopically, it shows nests of melanocytic cells without prominent nucleoli, which is characteristic of melanocytic nevi (benign moles).

B. SCC presents as a scaly, ulcerated, or keratotic lesion, often in sun-exposed areas. It does not typically appear as a brown to black pigmented lesion.

C. Lichen planus is an inflammatory disorder that presents as violaceous, itchy, polygonal papules, not a pigmented lesion.

D. Melanomas often have irregular borders, asymmetry, color variegation, and rapid growth. The absence of red nucleoli and the presence of regular pigmentation suggest a benign lesion rather than melanoma.

E. BCC usually presents as a pearly, translucent nodule with telangiectasia, not a pigmented lesion.

123) The most common soft tissue tumor in children is?

A. Pleomorphic fibroblastic sarcoma

B. Liposarcoma

C. Dermatofibroma

D. Rhabdomyosarcoma

E. Synovial sarcoma

➤ Explanations:

A. This is a rare high-grade tumor that occurs mainly in adults. It is not the most common soft tissue tumor in children.

B. Liposarcomas are rare in children and are more commonly found in adults.

C. Dermatofibromas are benign fibrohistiocytic tumors and are not classified as soft tissue sarcomas.

D. Correct, Rhabdomyosarcoma (RMS) is the most common soft tissue tumor in children, accounting for more than 50% of pediatric soft tissue sarcomas. It arises from immature skeletal muscle cells and typically affects the head and neck, genitourinary tract, and extremities.

E. While synovial sarcoma can occur in children and young adults, it is less common than rhabdomyosarcoma.

124) Pseudohyphae and germ tube structures can be found in?

A. Epidermophyton

B. Candida albicans

C. Microsporum

D. Malassezia

E. Trichophyton

➤ Explanations:

* *Candida albicans* is a dimorphic fungus that can exist in both yeast and filamentous forms. It is characterized by:

* Pseudohyphae → elongated yeast cells that remain attached in chains.

* Germ tubes → outgrowths formed when *Candida albicans* is incubated in serum at 37°C, distinguishing it from other *Candida* species.

A. A dermatophyte that causes skin and nail infections but does not form pseudohyphae or germ tubes.

C. A dermatophyte responsible for tinea (ringworm) infections, but it does not exhibit germ tubes or pseudohyphae.

D. A yeast associated with pityriasis versicolor, but it does not form pseudohyphae or germ tubes.

E. Another dermatophyte that affects hair, skin, and nails, but it does not produce germ tubes or pseudohyphae.

125) Which muscles of mastication move the TM from right to left and back?

A. Temporalis and medial pterygoid

B. Buccinator and medial pterygoid

C. Medial pterygoid and lateral pterygoid

D. Masseter and temporalis

E. Lateral pterygoid and temporalis

➤ Explanations:

A. Temporalis mainly retracts the mandible, not responsible for lateral movement.

B. Buccinator is not a muscle of mastication; it helps in cheek compression.

C. (Correct) The movement of the temporomandibular joint (TMJ) from right to left and back (lateral excursion) involves muscles that create side-to-side motion of the mandible.

* Lateral pterygoid – Pulls the mandible to the opposite side.

* The right lateral pterygoid moves the mandible to the left.

* The left lateral pterygoid moves the mandible to the right.

- * Medial pterygoid – Assists in side-to-side movement.
- * Works in coordination with the lateral pterygoid for grinding and chewing motions.

D. These muscles are involved in elevation and retraction, not lateral movement.

E. Temporalis does not contribute significantly to side-to-side motion

126) All of the following are posteromedial relations of the ankle joint, except?

- A. Flexor hallucis longus
- B. Posterior tibial Vessels
- C. Extensor digitorum longus
- D. Tibialis posterior
- E. Posterior tibial Nerve

➤ Explanations:

- A. Flexor hallucis longus – Passes posteriorly and medially to flex the big toe.
- B. Posterior tibial Vessels – Supply blood to the posterior compartment and foot.
- C. (Correct Answer) The posteromedial structures of the ankle joint are located behind and towards the inner (medial) side of the ankle. These structures pass through the tarsal tunnel, which is found posterior to the medial malleolus. Extensor digitorum longus is an anterior structure and does not belong here.
- D. Tibialis posterior – Main tendon helping in foot inversion and plantarflexion.
- E. Posterior tibial Nerve – Innervates the intrinsic muscles of the foot and provides sensation.

127) Which of the followings ligament present medial to the capsule of the hip joint?

- A. Pubofemoral
- B. Inguinal
- C. Iliofemoral
- D. Ischiofemoral
- E. Ligamentum teres

➤ Explanations:

* The hip joint capsule is reinforced by three main ligaments:

1. Iliofemoral (anterior & superior)
2. Pubofemoral (anterior & inferior, MEDIAL to the capsule)
3. Ischiofemoral (posterior).

A. (Correct Answer) The pubofemoral ligament extends from the pubic part of the acetabular rim to the femur (intertrochanteric line). It reinforces the medial and inferior aspect of the hip joint capsule and prevents excessive abduction and lateral rotation of the hip.

B. Inguinal – Not directly related to the hip joint capsule; it forms the boundary of the femoral triangle.

C. Iliofemoral – Located anteriorly and superiorly, but not specifically medial.

D. Ischiofemoral – Positioned posteriorly, not medial.

E. Ligamentum teres – Lies inside the joint, not medial to the capsule.

128) Which of the following muscles do flexion and abduction of the hip joints?

- A. Rectus femoris
- B. Gracilis
- C. Psoas major
- D. Hamstring
- E. Sartorius

➤ Explanations:

- A. Rectus femoris – Does hip flexion but not abduction (it mainly extends the knee).
- B. Gracilis – Does hip adduction, not abduction.
- C. Psoas major – Does hip flexion, but not abduction (it helps in maintaining posture).
- D. Hamstring – Do hip extension and knee flexion, not hip flexion or abduction.
- E. (Correct Answer) Sartorius:
 - * Origin: Anterior superior iliac spine (ASIS).
 - * Insertion: Medial surface of the tibia (pes anserinus).
 - * Actions at the hip joint: Flexion, Abduction, and Lateral rotation.
 - * Actions at the knee joint: Flexion and Medial rotation (when the knee is flexed).

129) One of the following is NOT true about mature and immature bone?

- A. Immature bone forms more rapidly than mature bone
- B. The mineral content is lower in immature bone
- C. The matrix of immature bone has more ground substance
- D. Mature bone contains more cells per unit area than the immature
- E. Immature bone has no lamellated appearance

➤ Explanations:

- A. True. Woven bone (immature) is quickly formed during fetal development and fracture healing.
- B. True. Immature bone is less mineralized and has a lower calcium and phosphate content.
- C. True. Woven bone has more proteoglycans and less organized collagen, contributing to a higher ground substance content.
- D. (Correct Answer - The False statement) Immature bone (also called woven bone) contains more cells per unit area compared to mature bone. This is because woven bone is formed quickly and has a less organized structure with a higher cellular density. Mature bone (lamellar bone) is more structured and has a lower number of osteocytes per unit area, because the cells are more evenly distributed in organized lamellae.
- E. True. Unlike mature bone, which has a lamellar (layered) structure, immature bone has a random fiber arrangement and lacks lamellae.

130) The distance between Z-lines is equivalent to the length of the?

- A. Sarcomere
- B. M line
- C. A band
- D. H band

E. I band

➤ Explanations:

A. (Correct Answer) The Z-line (or Z-disc) is the boundary that defines the ends of a sarcomere. The distance between the Z-lines represents the length of the sarcomere, which is the basic contractile unit of a muscle. And the Z-line serves as the anchor for actin filaments.

B. M line – The middle of the sarcomere where thick (myosin) filaments are anchored; it does not represent the full length of a sarcomere.

C. A band – Represents the region where both thick and thin filaments overlap; it does not define the total length.

D. H band – The region of the A band where only thick filaments (myosin) are present.

E. I band – The region where only thin filaments (actin) are present.

131) Which of the following pairs is mismatched?

A. Streptococcus pyogenes— erysipelas

B. Pseudomonas aeruginosa — scalded skin syndrome

C. Staphylococcus aureus — impetigo

D. Propionibacterium acnes — acne

E. Streptococcus pyogenes — TSS

➤ Explanations:

A. Streptococcus pyogenes is known to cause erysipelas, a skin infection characterized by raised, red, well-demarcated skin lesions.

B. (Correct Answer - Mismatched) This is incorrect. Scalded skin syndrome is typically caused by Staphylococcus aureus, not Pseudomonas aeruginosa. It leads to the shedding of the outer skin layer, usually in infants and children.

C. Staphylococcus aureus – impetigo. Correctly matched; it is a common cause of superficial skin infections with honey-colored crusts.

D. Propionibacterium acnes – acne. Correctly matched; this bacteria is responsible for follicle inflammation leading to acne.

E. Streptococcus pyogenes – TSS. Correctly matched; it can cause toxic shock syndrome (TSS), which is a severe systemic infection with high fever, rash and multi-organ failure.

132) Infective Stage of spiralis is?

A. larval eggs

B. adult female worm

C. encysted larvae in muscle

D. male worm

E. encysted larvae in stool

➤ Explanations:

C. (Correct Answer) The infective stage of *Trichinella spiralis* is the encysted larvae found in the skeletal muscle of an infected animal. Humans acquire it by consuming undercooked meat containing these larvae. Once ingested, they mature in the small intestine and produce more larvae which then migrate to muscle tissue to encyst.

Option	Explanation
A. Larval eggs	<i>Trichinella spiralis</i> does not produce larval eggs. Instead, the female releases live larvae (not eggs), which then migrate to muscle tissue.
B. Adult female worm	The adult female <i>Trichinella spiralis</i> lives in the small intestine of the host and releases larvae, but it's not the infective stage.
C. Encysted larvae in muscle	The encysted larvae in skeletal muscle are the infective stage. Humans become infected by eating undercooked or raw meat containing larvae.
D. Male worm	The male worm only fertilizes the female and then dies. It does not play in transmission or infection of a new host.
E. Encysted larvae in stool	<i>Trichinella spiralis</i> larvae do not appear in stool because they migrate to the muscles. Stool examination is not used for diagnosing trichinellosis.

133) In hyperhidrosis: Which one of the following is true?

- A. It protects against bacterial and fungal in groins or axilla
- B. It can be made worse by topical aluminum chloride hexahydrate
- C. It produces a pungent smell due to sweat secreted by apocrine glands
- D. Excessive sweating is reduced by a topical deodorant
- E. In the axilla, it may respond to local injection of botulinum toxin

➤ Explanations:

- A. False. Hyperhidrosis actually increases the risk of infections because excessive sweating creates a moist environment for microbes.
- B. False. Aluminum chloride hexahydrate is a first-line treatment that works by blocking sweat glands, not worsening the condition.
- C. False. Hyperhidrosis affects eccrine glands (odorless sweat). Apocrine glands are responsible for body odor when bacteria break down their secretions, but they are not the main issue here.
- D. False. Deodorants only mask odor; antiperspirants (containing aluminum chloride) are needed to help control sweating.
- E. (Correct Answer) Botulinum toxin (Botox) injections are an FDA-approved treatment for axillary hyperhidrosis as they block acetylcholine release to reduce sweat production.

134) In march, a nursery school reports an outbreak among the children of a disease characterized by a high-grade fever starts suddenly and rapidly falls, children develop short-lived maculopapular rash that begins on the trunk spreads to the extremities. Most likely causative agent is?

- A. Herpes simplex virus 1
- B. Rubella virus

- C. Human herpes virus 6
- D. Parvovirus B19
- E. Varicella-zoster virus

➤ *Explanations:*

- A. HSV-1 typically causes oral herpes (cold sores), not a widespread rash with high fever in children.
- B. Rubella (German measles) has a low-grade fever and the rash starts on the face, not the trunk.
- C. (Correct Answer) HHV-6 causes Roseola infantum. It starts with a high fever (3-5 days), followed by a sudden drop in fever and the appearance of a maculopapular rash starting on the trunk.
- D. Parvovirus B19 causes "slapped cheek" rash on the face, not a trunk-first maculopapular rash.
- E. Varicella-zoster (chickenpox) presents with a vesicular rash (blisters) in multiple stages, not maculopapular.

135) Aspirin as antipyretic drug, all are true except?

- A. Increase set point level
- B. Decreases PGE₂ synthesis
- C. Lowers the body temperature of both normal person and feverish
- D. Decreases set point level
- E. Stimulates the heat-losing center

➤ *Explanation:*

- A. Correct answer, Fever occurs when pyrogens (like IL-1, IL-6, TNF- α) stimulate the hypothalamus to raise the body's "set point" temperature via increased prostaglandin E₂ (PGE₂) synthesis. Aspirin, as an antipyretic, lowers the set point, not increases it.
- B. Aspirin is a non-selective COX inhibitor that inhibits cyclooxygenase (COX-1 and COX-2), leading to reduced PGE₂ synthesis. Since PGE₂ mediates fever, its inhibition reduces fever.
- C. Aspirin primarily lowers body temperature in feverish individuals by resetting the elevated hypothalamic set point. In normothermic (normal temperature) individuals, aspirin does not significantly reduce body temperature because the set point isn't elevated to begin with. This statement is misleading or false, as aspirin's effect is specific to fever.
- D. Aspirin reduces fever by decreasing the hypothalamic set point through inhibition of PGE₂ synthesis.
- E. By lowering the set point, the body activates vasodilation, sweating, and increased peripheral heat loss, helping to reduce fever.

136) Which of the following ligaments prevents over abduction of the hip joint?

- A. Pubofemoral ligament
- B. Transverse acetabular ligament
- C. Iliofemoral ligament
- D. Ligamentum teres
- E. Ischiotemoral ligament

➤ *Explanations:*

A. (Correct Answer) The pubofemoral ligament is a medial and inferior ligament of the hip joint that extends from the pubic part of the acetabulum to the femoral neck. Its main function is to prevent excessive abduction and limit extension of the hip joint.

B. Transverse acetabular ligament – Completes the acetabular rim but does not limit movement.

C. Iliofemoral ligament – The strongest ligament; it prevents hyperextension.

D. Ligamentum teres – Provides blood supply to the femoral head but has little role in stability.

E. Ischiofemoral ligament – Limits internal rotation and extension, not abduction.

137) Select the correct statement of the following?

A. Protrusion of omentum or an organ through a surgical incision is called Spigelian hernias

B. An epigastric hernia occurring along the semilunar lines of anterior abdominal wall

C. Pfannenstiel's incision commonly used for approach to the pelvic Organs

D. Upper paramedian incision is the most suitable for explorative laparotomy

E. Para rectus incisions is considered one of low-risk incisions

➤ *Explanation:*

A. A Spigelian hernia occurs through the Spigelian fascia, which is the aponeurotic layer between the rectus abdominis and the semilunar line, not through a surgical incision. A hernia through a surgical incision is called an incisional hernia.

B. Epigastric hernias occur along the midline (linea alba), not the semilunar lines (which are lateral). Hernias occurring along the semilunar lines are called Spigelian hernias.

C. Correct answer, Pfannenstiel's incision (a low transverse abdominal incision) is commonly used in gynecological and urological surgeries, such as C-sections and hysterectomies, because it provides excellent access to the pelvic organs and has a good cosmetic outcome.

D. Midline laparotomy is preferred for exploratory laparotomy because it provides better access to abdominal organs and can be extended if needed. The upper paramedian incision has limited exposure and is less commonly used.

E. Para-rectus incisions (such as the Battle incision) have a higher risk of complications, including nerve injury and incisional hernias, compared to midline or Pfannenstiel incisions.

138) All the following about skeletal muscle relaxants are true except?

A. Baclofen is a skeletal muscle relaxant by acting as GABA -B receptor agonist

B. Succinylcholine is useful for short endotracheal intubation before general anesthesia

C. Tizanidine has central alpha₂ agonist activity and can Lower blood pressure

D. Botulinum toxin A (Botox) is useful in blepharospasm.

E. Pancuronium is short acting but can slow heart due to central vagal stimulation

➤ *Explanation:*

A. Baclofen is a centrally acting muscle relaxant that works by stimulating GABA-B receptors in the spinal cord, leading to inhibition of excitatory neurotransmission and muscle relaxation.

B. Succinylcholine is a depolarizing neuromuscular blocker that provides rapid onset and short duration of muscle relaxation, making it ideal for rapid sequence intubation (RSI).

C. Tizanidine is an α_2 -agonist that reduces muscle spasticity by inhibiting excitatory neurotransmitter release. It can also cause hypotension as a side effect due to its central α_2 agonist action.

D. Botox works by blocking acetylcholine release at the neuromuscular junction, leading to temporary muscle paralysis. It is commonly used for blepharospasm (involuntary eyelid muscle spasms), cervical dystonia, and cosmetic wrinkle reduction.

E. Correct answer, Pancuronium is a long-acting non-depolarizing neuromuscular blocker, not a short-acting one.

* Instead of slowing the heart, pancuronium actually causes tachycardia by blocking muscarinic receptors (vagal inhibition), leading to increased heart rate.

* It does not have significant central effects because it does not cross the blood-brain barrier.

139) The following events in procollagen biosynthesis occur Within cells EXCEPT?

A. Oxidation of lysyl residues

B. Formation of disulfide bonds

C. Chain alignment

D. O-linked glycosylation

E. Hydroxylation of lysyl residues

➤ Explanation:

A. Correct answer, In collagen biosynthesis, lysyl residues are oxidized to allysine by lysyl oxidase, which occurs outside the cell in the extracellular matrix.

* This oxidation is crucial for cross-linking collagen fibrils, which provides strength and stability.

B. Disulfide bond formation occurs within the endoplasmic reticulum (ER) and is essential for correct procollagen triple helix assembly.

C. Procollagen chains align within the ER before forming the triple helix, which is stabilized by disulfide bonds and hydrogen bonding.

D. O-linked glycosylation of collagen occurs in the Golgi apparatus, where sugars (e.g., galactose, glucose) are added to hydroxylysine residues.

E. Hydroxylation of lysyl and prolyl residues occurs in the ER, catalyzed by lysyl hydroxylase and prolyl hydroxylase, respectively.

* This process requires vitamin C (ascorbic acid) as a cofactor.

140) For collagen synthesis, choose the incorrect statement?

A. Lysyl oxidase and extracellular enzyme produces the final step in the collagen synthesis pathway

B. The beginning of collagen synthesis begins with turning on genes

C. There are approximately 24 genes associated with collagen formation

D. In the Golgi apparatus, the procollagen goes through one last post-translational modification before being secreted

E. Collagen carboxylase, removes the "loose ends" of the procollagen molecule

➤ Explanations:

A. Lysyl oxidase catalyzes oxidative deamination of lysine and hydroxylysine residues in tropocollagen to form cross-links between collagen fibrils. This is a final extracellular step that strengthens collagen fibers.

B. Collagen synthesis starts at the genetic level, where genes encoding collagen chains are transcribed into mRNA and translated into pre-procollagen in ribosomes.

C. There are more than 30 genes coding for different collagen chains, forming different collagen types.

D. Glycosylation of hydroxylysine residues and packaging of procollagen into vesicles occur in the Golgi apparatus before secretion.

E. (Correct Answer - The False statement) The enzyme responsible for removing propeptides ("loose ends") is procollagen peptidase, not "collagen carboxylase." This step occurs outside the cell, converting procollagen into tropocollagen, which then assembles into fibrils.

141) Which of the following enzymes is ultimately responsible for the production of prostaglandins associated with inflammatory reactions?

A. Lipoxygenase

B. Cyclooxygenase II

C. Phospholipase

D. Cyclooxygenase-I

E. Xanthine oxidase

➤ Explanations:

A. Lipoxygenase is responsible for the synthesis of leukotrienes, which are involved in inflammation, but not prostaglandins.

B. (Correct Answer) COX-2 is an inducible enzyme expressed in response to inflammation, cytokines, and injury. It catalyzes the conversion of arachidonic acid into prostaglandins (PGE₂, PGI₂, etc.), which mediate pain, fever, and inflammation. This is why COX-2 inhibitors (like celecoxib) are used as anti-inflammatory drugs.

C. Phospholipase A₂ releases arachidonic acid from membrane phospholipids, which is the precursor for prostaglandin synthesis, but it does not directly produce prostaglandins.

D. COX-1 is a constitutive enzyme that produces prostaglandins for physiological functions (e.g., gastric protection, platelet aggregation, kidney function). It is not primarily involved in inflammatory responses.

E. Xanthine oxidase is involved in purine metabolism and uric acid production (related to gout), not prostaglandin synthesis.

142) Rigor mortis is caused by?

A. Increase C⁺⁺ in ECE

B. Decrease in ICE

C. Increase lactic acid

D. Depletion of ATP

E. Decrease ADP

➤ Explanations:

* A: Incorrect. Rigor mortis is caused by intracellular calcium changes, not extracellular (ECE).

* B: Incorrect. This is not directly related to the muscle contraction process in rigor mortis.

* C: While lactic acid increases after death due to anaerobic metabolism, it does not directly cause rigor mortis.

* D: (Correct Answer) After death, ATP production stops because cellular respiration ceases. ATP is required to detach myosin heads from actin after muscle contraction. Without ATP, myosin remains bound to actin, causing muscle stiffness known as rigor mortis.

* E: ADP levels are not the main cause of rigor mortis; the issue is the absence of ATP to break cross-bridges between actin and myosin.

143) For elastin, choose the incorrect statement?

A. The ELN gene provides instructions for making a protein called tropoelastin

B. Elastin is made by linking many soluble tropoelastin protein molecules

C. Elastin production continues throughout the life.

D. The expression of ELN gene mainly occurs before birth.

E. It is mainly made up of amino acids- valine, glycine alanine and proline

➤ Explanations:

* A: True. The ELN gene encodes tropoelastin, which is the precursor of elastin.

* B: True. Tropoelastin molecules are cross-linked by lysyl oxidase to form elastin, which provides elasticity to tissues.

* C: (Correct Answer - The False statement) Most elastin is produced before birth and in early childhood. In adults, elastin production is very limited, and damage to elastin fibers is difficult to repair.

* D: True. ELN gene expression is highest during fetal development and early childhood, supporting the formation of elastic tissues.

* E: True. Elastin is rich in hydrophobic amino acids, including valine, glycine, alanine, and proline, which contribute to its elastic properties.

144) Which of the following is FALSE regarding cellulites and erysipelas?

A. Erysipelas has more dermal involvement.

B. Cellulitis is caused by *S. pyogenes* and uncommonly by *S. aureus*.

C. Complications without treatment.

D. Doctors can't always distinguish between them.

E. Cellulitis has well demarcated edge.

➤ Explanations:

* A: True. Erysipelas affects the upper dermis and superficial lymphatics, while cellulitis involves deeper dermal and subcutaneous tissues.

* B: True. Group A Streptococcus (*S. pyogenes*) is the most common cause of cellulitis. Staphylococcus aureus, especially MRSA, can also cause cellulitis but is less common than *S. pyogenes*.

* C: True. If left untreated, both erysipelas and cellulitis can lead to abscess formation, necrotizing fasciitis, sepsis, or bacteremia.

* D: True. The clinical presentation of cellulitis and erysipelas can overlap, making diagnosis challenging, especially in cases with moderate inflammation.

* E: (Correct Answer - The False statement) Erysipelas typically has well-demarcated, raised, and erythematous borders. Cellulitis, on the other hand, has ill-defined, poorly demarcated margins, blending into the surrounding skin.

145) Regarding osteoclast, one of the following is TRUE?

A. Break down the inorganic part of bone

B. Has a smooth surface

C. Originated from osteoblast

D. Multinucleated cell that contains lysosomes

E. Sharpey's lacunae are areas of bone resorption by osteoclast.

➤ *Explanations:*

* A: False. Osteoclasts break down both organic (collagen matrix) and inorganic (mineralized) components of bone during bone resorption.

* B: False. Osteoclasts have a ruffled border, which increases their surface area for resorption and enhances their ability to break down bone.

* C: False. Osteoclasts originate from hematopoietic stem cells (monocyte/macrophage lineage), not from osteoblasts.

* D: (Correct Answer) Osteoclasts are large, multinucleated cells derived from monocyte/macrophage. They contain lysosomes filled with hydrolytic enzymes (e.g., cathepsin K, acid phosphatase, and collagenases) that help degrade bone matrix.

* E: False. The correct term is Howship's lacunae, not Sharpey's lacunae. Howship's lacunae are small depressions on bone surfaces where osteoclasts actively resorb bone.

146) Which of the following is false regarding the inguinal canal?

A. The superficial inguinal ring lies immediately above and medial to the pubic tubercle

B. The direct inguinal hernia is the remains of the processus vaginalis

C. In the posterior wall is the conjoint tendon medially & fascia transversalis laterally

D. The lacunar ligament form part of floor

E. The margins of the deep ring give attachment to the internal spermatic fascia

➤ *Explanations:*

* A: True. The superficial inguinal ring is an opening in the external oblique aponeurosis, located above and medial to the pubic tubercle.

* B: (Correct Answer - The False statement) Indirect inguinal hernias are caused by a persistent processus vaginalis, which remains open and allows abdominal contents to protrude. Direct inguinal hernias occur due to weakness in the posterior wall of the inguinal canal (Hesselbach's triangle) and are not related to the processus vaginalis.

* C: True. The posterior wall of the inguinal canal is formed by:

- Medially: Conjoint tendon (fusion of the internal oblique and transversus abdominis aponeuroses).
- Laterally: Fascia transversalis, which covers the deep inguinal ring.

* D: True. The floor of the inguinal canal is formed by:

- Medially: Lacunar ligament (a continuation of the inguinal ligament, attaching to the pubic bone).
- Laterally: The inguinal ligament itself.

* E: True. The deep inguinal ring is an opening in the fascia transversalis, and its margins contribute to the internal spermatic fascia, which covers the spermatic cord in males.

147) Regarding extra-capsular ligaments of the knee joint, which is false?

- A. Lateral collateral ligament is separated from the capsule and lateral meniscus by popliteus.
- B. Medial collateral ligament is firmly adherent to the capsule and medial meniscus.
- C. Ligamentum patellae is the termination of quadriceps tendon
- D. Arcuate popliteal ligament over the popliteus tendon
- E. Posterior oblique ligament, is a reflected extension from the semitendinosus extends upwards and laterally to the lateral condyle of the femur.

➤ Explanations:

* A: True. The LCL is not attached to the lateral meniscus because the popliteus muscle runs between them. This separates the LCL from both the capsule and meniscus.

* B: True. The MCL is attached to the medial meniscus, making them functionally linked. This is why medial meniscus injuries often occur with MCL tears.

* C: True. The ligamentum patellae (patellar ligament) is a continuation of the quadriceps tendon, extending from the patella to the tibial tuberosity.

* D: True. The arcuate popliteal ligament reinforces the posterior knee capsule and arches over the popliteus tendon.

* E: (Correct Answer - The False statement) The posterior oblique ligament (POL) is not from the semitendinosus. Instead, it is a part of the superficial MCL, originating from the adductor tubercle of the femur and reinforcing the posteromedial knee. It extends upward and medially, not laterally to the lateral condyle.

148) For melanin, all of the following are correct except?

- A. Eumelanin is the most abundant type of melanin in humans
- B. Pheomelanin is a red-yellow pigment
- C. Eumelanin can be found only as a black eumelanin
- D. Melanin possesses photochemical qualities that make it a photoprotectant
- E. Neuromelanin can be found in the medulla, and in the adrenal gland

➤ Explanations:

* A: True. Eumelanin is the dominant form of melanin in human skin, hair, and eyes, providing pigmentation and UV protection.

* B: True. Pheomelanin is responsible for red and yellow pigmentation, found in individuals with red or blond hair and in certain areas like lips and nipples.

* C: (Correct Answer - The False statement) Eumelanin exists in two forms: 1. Black eumelanin, 2. Brown eumelanin. Both contribute to hair and skin color variations. This statement is incorrect because eumelanin is not limited to only the black form.

* D: True. Melanin absorbs UV radiation, preventing DNA damage and reducing the risk of skin cancer.

* E: True. Neuromelanin is present in the substantia nigra of the brain and is also found in the adrenal medulla.

149) Which one of the following measures considered as a primary prevention for Musculo-skeletal injury?

A. Bullet proof vests

B. Life vests

C. Seat belts

D. Motorcycle helmets

E. Safety caps on poisonous substances

➤ Explanations:

* A: They primarily prevent penetrating injuries (e.g., gunshot wounds) rather than musculoskeletal injuries.

* B: Life vests prevent drowning rather than musculoskeletal injuries.

* C: Correct answer, Seat belts prevent high-impact injuries in car accidents, reducing the risk of fractures, spinal injuries, and whiplash, which are all musculoskeletal injuries.

* D: While helmets prevent head and brain injuries, they are not specifically designed to prevent musculoskeletal injuries.

* E: This is a primary prevention measure, but it prevents poisoning rather than musculoskeletal injuries.

150) The following statements concerning the spermatic cord are correct except which?

A. It contains the vas deferens.

B. It is covered with three layers of fascia derived from the anterior abdominal wall.

C. It contains the genital branch of the genitofemoral nerve

D. The inferior epigastric artery passes through

E. The testicular artery and vein lie within it.

➤ Explanations:

A: True. The vas deferens (ductus deferens) carries sperm from the testis to the ejaculatory duct.

B: True. The spermatic cord is covered by three layers of fascia:

* External spermatic fascia (from external oblique aponeurosis)

* Cremasteric fascia (from internal oblique muscle)

* Internal spermatic fascia (from transversalis fascia)

C: True. The genital branch of the genitofemoral nerve supplies the cremaster muscle and provides sensation to the scrotum.

D: (Correct Answer - The False statement) The inferior epigastric artery does not pass through the spermatic cord. Instead, it runs medial to the deep inguinal ring and helps define the boundaries of direct and indirect inguinal hernias.

E: True. The testicular artery (a branch of the abdominal aorta) and the pampiniform venous plexus (which drains into the testicular vein) are contained within the spermatic cord.

151) To decrease heat loss in cold exposure?

- A. V.C of skin blood vessels, counter current exchanger occurs in femoral artery and deep veins of lower Limbs and Curling the body occurs.
- B. V.C of skin blood vessels occurs.
- C. V.D of skin blood vessels occurs.
- D. Counter current exchanger occurs in femoral artery and deep veins of lower limbs.
- E. Curling the body.

➤ Explanations:

A: (Correct Answer) All these mechanisms work together:

* Vasoconstriction (VC) of skin blood vessels: Reduces blood flow to the skin to minimize heat loss by radiation and convection.

* Countercurrent heat exchange in the femoral artery and deep veins of the lower limbs: Warm blood in the arteries transfers heat to the cooler blood in the veins, helping retain heat in the core rather than losing it to the environment.

* Curling the body (fetal position): Reduces exposed surface area, minimizing heat loss.

C: False. Vasodilation (VD) increases blood flow to the skin, leading to heat loss, which happens in hot environments, not cold exposure.

E: While this helps reduce heat loss, it is not the only mechanism.

151) Movements of pronation and supination occur in?

- A. Elbow and superior radioulnar joints
- B. Middle and inferior radioulnar joints
- C. Superior and middle radioulnar joints
- D. Superior and inferior radioulnar joints
- E. Wrist and inferior radioulnar joints

➤ Explanation:

A: The elbow only allows flexion and extension, not rotation, it's not involved in pronation/supination.

B & C: no "middle" radioulnar joint; only the superior and inferior ones exist.

D: (Correct Answer) These movements occur at two main joints:

* Superior (proximal) radioulnar joint: Located near the elbow, where the head of the radius rotates within the annular ligament.

* Inferior (distal) radioulnar joint: Located near the wrist, where the radius moves around the fixed ulna.

Pronation and supination are rotational movements of the forearm:

* Pronation: The palm faces downward (posteriorly in anatomical position).

* Supination: The palm faces upward (anteriorly in anatomical position).

E: The wrist joint is not involved in pronation/supination; it primarily allows flexion/extension and some radial/ulnar deviation.

152) For collagen, choose the incorrect statement?

- A. Type IV forms the bases of cell basement membrane
- B. Type II collagen is the main component of cartilage
- C. Type III collagen is found in the walls of arteries
- D. Type V forms cell surfaces, hair and placenta
- E. Type V collagen and type XI collagen are major components of tissue

➤ Explanation:

A: True. Type IV collagen is a network-forming collagen found in basement membranes, providing support and filtration.

B: True. Type II collagen is found in hyaline cartilage, providing elasticity and tensile strength.

C: True. Type III collagen is abundant in blood vessels, skin, and reticular fibers (important in wound healing).

D: (Correct Answer - The False statement) Type V collagen is not a major component of cell surfaces or hair. It is mainly found in placenta, cornea, and some connective tissues, but not on cell surfaces or hair.

E: True. Type V collagen is found in fibrillar collagens, supporting tissues like placenta and bone.

Type XI collagen is associated with cartilage and collagen fibril organization.

Collagen		Be (So Totally) Cool, Read Books.
Type I	Most abundant protein in the human body. Extensively modified by posttranslational modification. Organizes and strengthens extracellular matrix.	Type I: bone. ↓ production in osteogenesis imperfecta type I.
Type II	Cartilage (including hyaline), vitreous body, nucleus pulposus.	Type II: cartilage.
Type III	Reticulin—skin, blood vessels, uterus, fetal tissue, granulation tissue.	Type III: deficient in the uncommon, vascular type of Ehlers-Danlos syndrome (Three D).
Type IV	Basement membrane (basal lamina), lens.	Type IV: under the floor (basement membrane). Defective in Alport syndrome; targeted by autoantibodies in Goodpasture syndrome.

153) Which of the following ligaments of the hip joint attached to iliopectineal eminence?

- A. Ischiofemoral ligament
- B. Transverse acetabular ligament
- C. Iliofemoral ligament
- D. Pubofemoral ligament
- E. Ligamentum teres

➤ Explanation:

A: Originates from the ischium (posterior acetabulum) and attaches to the greater trochanter. Reinforces the posterior part of the hip joint.

B: Bridges the acetabular notch at the inferior rim of the acetabulum. Helps keep the femoral head in the acetabulum.

C: Originates from the anterior inferior iliac spine (AIIS) and attaches to the intertrochanteric line of the femur. The strongest ligament, preventing hyperextension.

D: (Correct Answer) The pubofemoral ligament is one of the extracapsular ligaments of the hip joint. It:

- * Originates from the iliopectineal eminence, superior pubic ramus, and obturator crest.
- * Inserts into the femoral neck.
- * Function: It prevents over-abduction and excessive extension of the hip joint.

E: Ligamentum teres (round ligament)

- * Attaches the fovea capities of the femoral head to the acetabular notch.
- * Carries the artery to the head of the femur.

154) Meromelia is?

- A. Abnormal fusion of the fingers
- B. Extra number of the fingers
- C. Central cleft in the hand
- D. Short hand
- E. The limbs represented only by hand

➤ Explanation:

A: Abnormal fusion of the fingers (Syndactyly). This condition occurs when two or more fingers are fused together due to failure of separation during development.

B: Extra number of fingers (Polydactyly). A congenital anomaly where a person has extra fingers or toes.

C: Central cleft in the hand (Ectrodactyly or "Lobster claw" deformity). A condition where the central digits (fingers) are missing, leading to a cleft in the hand.

D: Short hand (Phocomelia), A more severe limb defect where the proximal parts of the limb (humerus, radius, ulna) are absent, but the hand is directly attached to the shoulder.

E: (Correct Answer) Meromelia is a congenital limb malformation where part of a limb is missing. It occurs due to disruptions in limb development during early embryogenesis (usually between the 4th and 8th week of gestation). In meromelia, the limb is partially formed, and in severe cases, only the hand or foot may be present without a fully developed limb, it's often associated with thalidomide embryopathy (caused by thalidomide exposure during pregnancy).

155) All the following are characteristics of chondromas, except?

- A. They usually are diagnosed in persons the ages of 20 and 50 years.
- B. They typically are solitary.
- C. The most common location is the pelvis.
- D. Ollier disease and Maffucci syndrome are characterized by multiple chondromas
- E. Solitary chondromas rarely undergo malignant transformation.

➤ Explanation:

A: True. Chondromas are most commonly diagnosed in young to middle-aged adults.

B: True. Most chondromas occur as a single lesion (solitary), although they can also appear in multiple syndromic conditions.

C: (Correct Answer - The False statement) Chondromas are benign tumors of hyaline cartilage that commonly arise in the bones of the hands and feet (particularly in the small bones of the fingers and toes).

They are less commonly found in long bones like the femur, humerus, and tibia. The pelvis is not a typical location for chondromas; instead, chondrosarcomas (malignant cartilage tumors) are more commonly found in the pelvis.

D: True. Ollier disease is a condition with multiple enchondromas, leading to bone deformities.

Maffucci syndrome includes multiple chondromas along with soft tissue hemangiomas.

E: True. Solitary chondromas have a very low risk of becoming chondrosarcomas. However, multiple chondromas (as seen in Ollier disease or Maffucci syndrome) have a higher risk of malignant transformation.

156) Which muscles of mastication arises from inner aspect of zygomatic arch?

- A. Superficial head of medial pterygoid
- B. Deep head of medial pterygoid
- C. Superficial head of masseter
- D. Deep head of masseter
- E. Temporalis

➤ Explanation:

A: This originates from the maxillary tuberosity of the zygomatic arch.

B: Originates from the lateral pterygoid plate of the sphenoid bone.

C: This arises from the lower border of the zygomatic arch, not the inner aspect.

D: (Correct Answer) The deep head of the masseter is responsible for elevating the mandible and plays a role in jaw clinching.

E: Originates from the temporal fossa and temporal fascia, not the zygomatic arch.

- The masseter muscle is one of the four muscles of mastication. It has two heads:
 - * Superficial head – originates from the zygomatic process of the maxilla and the anterior two-thirds of the lower border of the zygomatic arch.
 - * Deep head – originates from the inner aspect (deep surface) of the zygomatic arch.

157) Select the wrong statement regarding the openings in the base of the skull and the structures that pass through it?

- A. Optic canal nerve & the ophthalmic artery
- B. Foramen magnum Medulla oblongata
- C. Jugular foramen Hypoglossal nerve
- D. Foramen spinosum — Middle meningeal artery
- E. Foramen ovale Mandibular division of the trigeminal N.

➤ Explanation:

A: Correct. Optic canal contents: Optic nerve (CN II) & Ophthalmic artery.

Location: Lesser wing of sphenoid bone.

B: Correct. Foramen magnum contents: Medulla oblongata, vertebral arteries, spinal roots of the accessory nerve (CN XI), and meninges. Location: Occipital bone.

C: (Correct Answer - The False statement) The Hypoglossal nerve (CN XII) DOES NOT pass through the jugular foramen; it passes through the hypoglossal canal. The actual contents of the jugular foramen are: Glossopharyngeal (CN IX), Vagus (CN X), and Accessory (CN XI) nerves, along with the internal jugular vein.

D: Correct. Foramen spinosum contents: Middle meningeal artery & vein, and meningeal branch of mandibular nerve (V3). Location: Sphenoid bone.

E: Correct. Foramen ovale contents: Mandibular division of the trigeminal nerve (V3), accessory meningeal artery, and lesser petrosal nerve. Location: Sphenoid bone.

158) Scalded skin syndrome is?

- A. Most common in neonates and children less than 10 years of age.
- B. A direct effect of bacterial infection.
- C. Associated with all *S. aureus* strains.
- D. Loss of intercellular junction between cells in stratum granulosum layer.
- E. Sequelae in all cases.

➤ *Explanation:*

A: Correct. SSSS is most common in neonates and young children, particularly those under 5 years old, not just under 10 years of age.

B: False. It is not a direct effect of bacterial infection, but rather caused by the toxins produced by the bacteria.

C: False. Not all strains of *S. aureus* cause SSSS; only those that produce the exfoliative toxins.

D: (Correct Answer) This is because the condition is caused by exfoliative toxins produced by *Staphylococcus aureus*, which leads to loss of adhesion between cells in the stratum granulosum of the skin. This disruption causes the skin to peel off, resulting in the appearance of burns or scalds.

E: False. Sequelae are not common in all cases, as the condition can resolve with appropriate treatment, though complications can occur if left untreated.

159) Which of the following sentences describes a Blister best?

- A. Fluid-filled raised skin lesion.
- B. Fluid-filled raised skin lesion of less than 5 millimeters in diameter
- C. Elevated dome-shaped skin lesion
- D. Fluid-filled raised skin lesion of more than 5 millimeters in diameter
- E. Dry flaky skin peels

➤ *Explanation:*

A: (Correct Answer) This is a general description of a blister. A blister is characterized by fluid accumulation between the layers of the skin, leading to a raised lesion. It can be either a vesicle (small) or a bulla (large), but this choice broadly applies to both types of blisters.

B: This specifically describes a vesicle, which is a small blister, less than 5mm in diameter. It is a more specific definition, but it doesn't apply to all blisters, as some can be larger.

C: This describes a general skin lesion that may or may not be fluid-filled. It's a broad description, but it does not specifically capture the key characteristic of a blistering being fluid-filled.

D: This describes a bulla (plural: bullae), which is a larger type of blister, typically greater than 5mm in diameter. It's more specific than Choice A but doesn't account for smaller blisters, so it doesn't encompass all types of blisters.

E: This describes desquamation, which is the shedding or peeling of the outer layer of the skin, often due to dryness, irritation, or other skin conditions. It's not related to blisters, which are fluid-filled lesions.

160) All following matches about biological agents and side effects are true EXCEPT?

- A. Infliximab-Pancytopenia
- B. Infliximab- Increase risk of infections
- C. Etanercept- Local site reactions
- D. Rituximab- Liver toxicity
- E. Anakinra- Neutropenia

Explanations:

A: True. Infliximab can cause pancytopenia, infusion reactions, and an increased risk of infections.

B: True. As a TNF inhibitor, it suppresses the immune system, increasing vulnerability to infections.

C: True. Etanercept (a TNF inhibitor) commonly causes local injection site reactions.

D: (Correct Answer - The False statement) Rituximab (a monoclonal antibody targeting CD20 on B-cells) is primarily associated with infusion reactions, increased risk of infections, and rare cases of progressive multifocal leukoencephalopathy (PML). It is not typically known for liver toxicity.

E: True. Anakinra (an IL-1 receptor antagonist) can cause neutropenia and injection site reactions.

161) Anencephaly?

- A. No mandible bone
- B. No Zygomatic bone
- C. No mastoid bone
- D. No parietal bone
- E. No Vomer bone

➤ Explanation:

D: (Correct Answer) Anencephaly is a severe neural tube defect where the major parts of the brain, especially the cerebrum and cerebellum, are absent or severely underdeveloped. It is not directly related to specific bones like the mandible, zygomatic, mastoid, or vomer. However, the parietal bones, which are part of the skull, are often absent in this condition because they are closely related to brain development.

162) Regarding Musculo-skeletal injury; which one of the following statements is WRONG?

- A. Death rates due to injury tend to be higher in those in the higher income groups
- B. Injuries, unintentional or intentional, constitute a major public health problem
- C. Injuries killing many people worldwide and causing many more cases of disability
- D. People from all economic groups suffer fatal injuries
- E. The poor are also less likely to make a full recovery following an injury

➤ Explanation:

* A: (Correct Answer - The False statement) In general, death rates due to injury tend to be higher in lower-income groups. People from lower-income backgrounds often face more risk factors, such as poor access to healthcare, unsafe living or working conditions, and a lack of resources for injury prevention. Conversely, higher-income groups may have better access to healthcare, safer living conditions, and greater capacity for injury prevention, leading to lower death rates from injuries.

* B: True. Injuries, whether they are unintentional (like car accidents, falls, etc.) or intentional (such as violence or self-harm), are a significant public health issue worldwide. They are responsible for a high number of deaths, disabilities, and hospitalizations each year. Addressing and preventing injuries is a major focus for public health systems globally.

* C: True. Injuries are one of the leading causes of death worldwide, and even more people suffer non-fatal injuries that lead to long-term disability. For example, road traffic accidents, falls, and violence can cause life-altering injuries that impact a person's ability to work, perform daily tasks, or enjoy a good quality of life. The World Health Organization (WHO) recognizes injuries as a major global health issue.

* D: True. Fatal injuries do affect people from all economic backgrounds. However, the rates of fatal injuries are higher in lower-income groups due to various socioeconomic factors like poor living conditions, inadequate access to medical care, and more hazardous work environments. Despite this, fatal injuries are not exclusive to any one economic group.

* E: True. People in lower-income groups are more likely to experience delayed recovery from injuries due to limited access to healthcare, lack of rehabilitation services, and inadequate social support. Additionally, they may face financial constraints that hinder their ability to seek proper medical treatment and follow-up care. This often results in poorer outcomes and longer recovery times compared to individuals in higher-income groups.

163) For hypocalcaemia, all of the following are correct except?

- A. It manifests as a symptom of unusually low magnesium levels
- B. Hypocalcaemia may be associated with high levels of inactive PTH
- C. It is the presence of low serum calcium levels in the blood
- D. It manifests as a symptom of a (PTH) deficiency/malfunction
- E. It manifests as a symptom of a high Vitamin D levels

➤ Explanation:

* A: True. Hypocalcemia can indeed be associated with low magnesium levels. Magnesium plays a role in the secretion and function of parathyroid hormone (PTH), and low magnesium can impair PTH secretion, which in turn can lead to hypocalcemia.

* B: True. In cases of hypocalcemia, PTH (parathyroid hormone) levels may be elevated, but the hormone may be in an inactive or ineffective form. This can occur due to renal issues or other dysfunctions in calcium regulation, where the body is unable to activate PTH efficiently.

* C: True. Hypocalcemia is defined by abnormally low levels of calcium in the blood, typically less than 8.5 mg/dL.

* D: True. One of the primary causes of hypocalcemia is a deficiency or malfunction of PTH, which is responsible for regulating calcium levels in the blood. Conditions like hypoparathyroidism can lead to PTH deficiency and result in hypocalcemia.

* E: (Correct Answer - The False statement) High levels of Vitamin D typically lead to hypercalcemia, not hypocalcemia. Vitamin D increases calcium absorption from the gut, which would raise calcium levels in the blood. Therefore, high Vitamin D levels would not lead to hypocalcemia but rather the opposite.

164) All following about methotrexate MTX are true EXCEPT?

- A. Can be given to pregnant women
- B. used alone or in combination therapy
- C. Inhibits purine synthesis
- D. Response to MTX occurs sooner than with other agents
- E. Doses in rheumatoid arthritis is low

➤ Explanation:

* A: Methotrexate (MTX) is strictly contraindicated in pregnancy because it is teratogenic. It can cause severe congenital malformations, miscarriage, or fetal toxicity. Women of childbearing age must use effective contraception while on MTX and discontinue it well before conception.

* B: MTX is commonly used as a monotherapy for autoimmune diseases like rheumatoid arthritis (RA) but can also be combined with other disease-modifying antirheumatic drugs (DMARDs) to enhance efficacy and prevent disease progression.

* C: MTX inhibits dihydrofolate reductase (DHFR), leading to a decrease in tetrahydrofolate, which is essential for purine and pyrimidine synthesis. This results in suppressed DNA replication and immune cell proliferation, making it effective in both autoimmune diseases and cancer.

* D: MTX has a faster onset of action compared to other DMARDs. While traditional DMARDs may take months to show benefits, MTX often improves symptoms within 4-6 weeks, making it a preferred first-line treatment in RA.

* E: The dose of MTX in rheumatoid arthritis (typically 7.5-25 mg per week) is much lower than in chemotherapy for cancer treatment. This lower dose helps manage autoimmune diseases effectively while minimizing severe side effects.

165) Regarding cruciate ligaments, which is false?

- A. Anterior cruciate ligament attaches to the posterior part of the medial surface of the lateral condyle of the femur
- B. Anterior cruciate ligament prevents hyperextension Of the knee
- C. Posterior cruciate ligament prevents anterior displacement of femur on tibia
- D. Anterior cruciate ligament prevents posterior displacement of the tibia
- E. Posterior cruciate ligament attaches to the anterior part of the lateral surface of the medial condyle of the femur

➤ Explanation:

* A: The anterior cruciate ligament (ACL) originates from the anterior intercondylar area of the tibia and attaches to the posterior part of the medial surface of the lateral condyle of the femur.

* B: The ACL prevents hyperextension of the knee by resisting excessive anterior movement of the tibia relative to the femur.

* C: The posterior cruciate ligament (PCL) prevents anterior displacement of the femur on the tibia, stabilizing the knee during flexion.

* D: The ACL prevents anterior displacement of the tibia (it stops the tibia from moving too far forward). Posterior displacement of the tibia is prevented by the PCL.

* E: (The False statement) The PCL actually attaches to the posterior part of the lateral surface of the medial femoral condyle, not the anterior part.

166) All the following are arteries of the anterolateral abdominal wall EXCEPT?

- A. Subcostal artery
- B. Superficial circumflex iliac artery
- C. Obturator artery
- D. Superior epigastric artery
- E. Deep circumflex iliac

➤ Explanation:

A. Subcostal artery: A branch of the thoracic aorta that supplies the lower part of the abdominal wall.

B. Superficial circumflex iliac artery: A branch of the femoral artery, supplying the skin and superficial fascia near the inguinal region.

C. (Correct answer) Obturator artery: The obturator artery is a branch of the internal iliac artery, and it mainly supplies the medial thigh, hip joint, and pelvic structures rather than the abdominal wall.

D. Superior epigastric artery: A continuation of the internal thoracic artery, supplying the rectus abdominis and upper abdominal wall.

E. Deep circumflex iliac: A branch of the external iliac artery, supplying the inferior abdominal wall.

167) The severity of receptor defect rickets is due to?

- A. Recognition of several mutant forms of receptor defect rickets
- B. Very severe hypocalcaemia
- C. Totally resistant to therapy
- D. Secondary risks of calcium therapy
- E. Elevation of serum calcitriol level

➤ Explanation:

A. Regarding the severity: While multiple mutations of the Vitamin D receptor (VDR) exist, the severity of receptor defect rickets is not primarily due to recognizing different mutations but rather their functional impact.

B. Hypocalcaemia is a symptom of receptor defect rickets, but the severity of the disease is more related to its resistance to treatment rather than just the level of hypocalcaemia.

- C. (Correct answer) Resistance to therapy: Receptor defect rickets (also called Vitamin D-dependent rickets type II) is caused by a mutation in the vitamin D receptor (VDR), leading to resistance to active vitamin D (calcitriol) therapy. This makes treatment extremely challenging, making this the most appropriate answer.
- D. Therapy risks: High-dose calcium therapy is often used in severe cases, but the risks of therapy are not the main reason for the disease's severity.
- E. Calcitriol levels: Due to VDR resistance, serum calcitriol (active vitamin D) levels are often elevated but ineffective, as the receptor does not respond properly. However, this is a consequence rather than the reason for severity.

168) All the followings are Ergonomic problems indicators, EXCEPT?

- A. Increased incidence of cumulative trauma disorders
- B. Employer complaint
- C. Employee generated changes
- D. Absenteeism and high turn over
- E. poor quality

➤ Explanation:

A. Cumulative trauma disorders: Ergonomic problems can lead to repetitive strain injuries (RSIs) such as carpal tunnel syndrome and tendonitis.

B. (Correct answer) Employer complaint: While employers may notice issues, employee complaints and objective measures (e.g., injury reports, absenteeism) are stronger indicators of ergonomic problems.

C. Employee generated changes: When workers adjust their workstations or workflows to reduce discomfort, it suggests ergonomic issues exist.

D. Absenteeism: Discomfort and physical strain reduce productivity and accuracy, leading to errors and poor work quality.

E. Poor quality: Poor ergonomics can lead to injuries, discomfort, and job dissatisfaction, causing employees to take more sick leaves or quit.

169) For osteoblasts, choose the incorrect statement?

- A. Osteoblasts are multinucleated cells.
- B. Osteoblasts synthesize most of proteins found in bone
- C. Osteoblasts are responsible for the deposition of new bone matrix
- D. Osteoblasts are responsible for bone formation
- E. Osteoblasts control mineralization process

➤ Explanation:

* A (Incorrect): Osteoblasts are multinucleated cells is incorrect. Osteoblasts are typically mononucleated cells, meaning they have only one nucleus. Multinucleated cells are characteristic of osteoclasts, not osteoblasts.

* B: Osteoblasts synthesize most of the proteins found in bone is correct. Osteoblasts are responsible for producing the organic components of the bone matrix, such as collagen and other proteins.

Ergonomic problems refer to workplace conditions that cause physical strain or discomfort due to improper design, leading to injuries or reduced efficiency.

Causes: * Poor posture
* Repetitive movements

Solution:
* Adjusting workstations for better comfort

* C & D: Osteoblasts are the cells responsible for bone formation through the production of osteoid, which later becomes mineralized.

* E: Osteoblasts regulate the mineralization of bone matrix by controlling the deposition of calcium and phosphate.

170) A 3-year-old child presents at the physician's office with symptoms of coryza, conjunctivitis, low grade fever, and Koplik's spots. The causative agent of this disease is?

- A. Human papilloma virus
- B. Herpesvirus
- C. poxvirus
- D. parvovirus B19
- E. Measles virus.

➤ Explanation:

* A. HPV: This virus causes warts and, in some cases, is associated with certain cancers, not symptoms like those described in the question.

* B. Herpesvirus: This family of viruses causes infections like cold sores, chickenpox, and shingles, which do not fit the symptoms described.

* C. Poxvirus: This family includes the smallpox virus, which is eradicated, and the varicella virus (which causes chickenpox), but chickenpox does not present with the specific signs described here.

* D. Parvovirus B19: This virus causes erythema infectiosum (fifth disease) which presents with a distinctive "slapped cheek" rash, not the symptoms listed here.

* E. (Correct answer) Measles: The symptoms described – coryza (cold-like symptoms), conjunctivitis, low-grade fever, and Koplik's spots (small white spots on the mucous membranes of the mouth) – are characteristic of measles, which is caused by the measles virus (a paramyxovirus).

171) Concerning treatment of severe and widespread ECZEMA, all the following are true EXCEPT?

- A. Referral to dermatologist
- B. Histamine
- C. Oral or intramuscular steroids
- D. Phototherapy
- E. Oral methotrexate

➤ Explanation:

* A. Referral: Referral to a dermatologist is appropriate for severe or widespread eczema, as they can provide specialized treatment.

* B. Histamine (The False statement): This is incorrect because histamine is a chemical involved in allergic reactions and is not used as a direct treatment for eczema. Treatments for eczema typically focus on reducing inflammation, controlling the immune response, and managing symptoms with corticosteroids, immunosuppressants, and other therapies.

- * C. Steroids: These are often used to manage severe eczema, especially in flare-ups or widespread cases.
- * D. Phototherapy: Phototherapy, which uses ultraviolet light to treat eczema, is commonly recommended for widespread or severe eczema.
- * E. Methotrexate: Methotrexate is sometimes used as an immunosuppressant for severe, treatment-resistant eczema, particularly when other therapies have failed.

172) Which of the following is CORRECTLY paired regarding skin glands?

- A. Eccrine sweat glands ----- merocrine secretion.
- B. Sebaceous glands ----- apocrine secretion.
- C. Eccrine sweat glands----- adrenergic innervation.
- D. Apocrine sweat glands----- cholinergic innervation.
- E. Apocrine sweat glands----- holocrine secretion.

➤ Explanation:

- * A (Correct): Eccrine sweat glands release their secretions (sweat) through merocrine secretion, where the cells secrete their product via exocytosis without losing their cellular material.
- * B: Sebaceous glands secrete sebum via holocrine secretion, not apocrine. In holocrine secretion, the entire cell disintegrates to release its contents.
- * C: Eccrine sweat glands are primarily under cholinergic (not adrenergic) innervation, especially during thermoregulatory sweating.
- * D: Apocrine sweat glands are typically innervated by adrenergic fibers, not cholinergic fibers.
- * E: Apocrine sweat glands secrete via an apocrine mechanism, where only part of the cell is released with the secretion, not holocrine.

173) Topical steroids in skin disease: Which one of the following is false?

- A. Potent steroids must not be used on face or skin.
- B. Their therapeutic potency is increased by halogenation with fluoride or chloride.
- C. Their long term use causes skin atrophy and pink striae
- D. They decrease sebaceous gland activity.
- E. Mild potency topical steroids are ineffective in PLAQUE psoriasis

➤ Explanation:

- * A: Potent steroids can lead to significant side effects like thinning of the skin, so they should be used cautiously on the face and sensitive areas of the skin.
- * B: Halogenation, particularly with fluorine or chlorine, increases the potency of corticosteroids by enhancing their ability to penetrate the skin and bind to glucocorticoid receptors.
- * C: Chronic use of topical steroids can cause thinning of the skin (atrophy) and the development of striae (stretch marks), especially in areas of skin that are more sensitive or where the steroid is overused.
- * D: This is true. Topical steroids can reduce the activity of sebaceous glands, which can lead to a reduction in sebum production and may even exacerbate conditions like acne in some individuals.

* E (False statement): Mild potency steroids can be effective in treating localized plaque psoriasis, particularly in less severe cases or when used for short durations. However, for more widespread or severe cases, higher-potency steroids are often required for better efficacy.

174) Concerning the wrist joint?

- A. It usually communicates with the midcarpal joint
- B. The distal radius is not part of the joint
- C. The joint capsule is thicker posteriorly
- D. It usually communicates with the distal radioulnar joint
- E. The triquetral bone forms part of the wrist joint

➤ Explanation:

* A: The wrist joint (radiocarpal joint) typically does not communicate with the midcarpal joint. They are separate joints, with the midcarpal joint sitting between the two rows of carpal bones (proximal and distal rows).

* B: The distal radius is indeed a key part of the wrist joint, specifically forming the radiocarpal joint with the scaphoid, lunate, and triquetral bones of the carpal group.

* C: The joint capsule of the wrist is generally thicker anteriorly to provide more stability during wrist movements, while the posterior side tends to be thinner.

* D: There is usually no direct communication between the radiocarpal joint (wrist joint) and the distal radioulnar joint (DRUJ). These joints are anatomically distinct, although they function closely during wrist movements.

* E (True): This is true. The triquetral bone, located on the ulnar side of the wrist, forms part of the radiocarpal joint. Specifically, it articulates with the distal radius and contributes to the wrist's motion and stability.

175) All of the following facts are true about non-steroidal anti-inflammatory drugs (NSAIDs) except?

- A. They are anti-inflammatory
- B. They do not cause dependence
- C. They are antipyretic
- D. There is ceiling effect to their analgesia
- E. They can Cause tolerance

➤ Explanation:

* A: This is true. NSAIDs are indeed anti-inflammatory, meaning they help reduce inflammation in the body, which is one of their main uses.

* B (False Statement): This is true. NSAIDs are not known to cause physical dependence, unlike opioids or certain other medications.

* C: They are antipyretic. NSAIDs help reduce fever, so they have antipyretic effects.

* D: NSAIDs have a ceiling effect for their analgesic (pain-relieving) action, meaning after a certain dose, increasing the dose does not significantly increase their pain-relieving effect.

* E: NSAIDs do not typically cause tolerance. Tolerance occurs when a person needs increasingly higher doses to achieve the same effect, which is more common with substances like opioids, not NSAIDs.

176) What are responsible for increase the depth of the shoulder cavity?

- A. Articular cartilage
- B. Glenoid cavity
- C. Glenoid labrum ✓ ✓ ✓
- D. Synovial membrane
- E. Capsule

➤ Explanation:

* A. Articular cartilage: Articular cartilage covers the surface of the bones in the joint to reduce friction but does not significantly affect the depth of the shoulder cavity.

* B. Glenoid cavity: The glenoid cavity is the shallow socket of the scapula where the head of the humerus fits, but on its own, it does not significantly increase the depth.

* C (Correct): The glenoid labrum is a fibrocartilage structure that surrounds the glenoid cavity, deepening it and providing a more stable surface for the humeral head. This is the correct answer.

* D. Synovial membrane: The synovial membrane lines the joint capsule and produces synovial fluid but does not impact the depth of the cavity.

* E. Capsule: The joint capsule holds the shoulder joint together but does not significantly increase the depth of the glenoid cavity.

177) Which of the following medications would represent arthritis therapy that is least likely to cause gastric ulceration?

- A. Aspirin
- B. Acetaminophen
- C. Meclofenamate
- D. Rofecoxib
- E. Piroxicam

➤ Explanation:

* A. Aspirin: A nonsteroidal anti-inflammatory drug (NSAID) that is known to cause gastric ulceration as it inhibits cyclooxygenase (COX) enzymes, reducing protective prostaglandin production in the stomach.

* B (Correct): Unlike NSAIDs, acetaminophen (paracetamol) is not an anti-inflammatory agent and does not affect COX enzymes significantly. It is not associated with gastric ulceration, making it the least likely to cause this side effect.

* C. Meclofenamate: A nonsteroidal anti-inflammatory drug (NSAID) that can cause gastric irritation and ulcers, similar to other NSAIDs.

- * *D. Rofecoxib: A selective COX-2 inhibitor, a type of NSAID that was less likely to cause gastric ulcers compared to non-selective NSAIDs. However, it was withdrawn from the market due to cardiovascular risks.*
- * *E. Piroxicam: Another NSAID known for its potential to cause gastric ulcers and irritation, similar to aspirin.*

178) Which one of the following injuries resulted from an insufficiency of a vital element?

- A. Chemical
- B. Electrical
- C. Thermal
- D. Strangulation
- E. Mechanical

➤ *Explanation:*

- * *A. Chemical: This type of injury results from exposure to toxic chemicals or substances, not from an insufficiency of a vital element.*
- * *B. Electrical: Electrical injuries are caused by exposure to electric current, not from an insufficiency of a vital element.*
- * *C. Thermal: Thermal injuries are caused by extreme temperatures (heat or cold), not from a lack of any vital element.*
- * *D (Correct): Strangulation causes a lack of oxygen to vital organs, particularly the brain, due to the obstruction of blood vessels or airways. This injury directly results from the insufficiency of oxygen, a vital element.*
- * *E. Mechanical: Mechanical injuries involve physical force or trauma, such as cuts, bruises, or fractures, not related to an insufficiency of a vital element.*

179) Which of the following soft tissue Sarcoma shows a characteristic t(X;18) translocation?

- A. Dermatofibroma.
- B. Synovial sarcoma.
- C. Pleomorphic fibroblastic sarcoma
- D. Liposarcoma
- E. Rhabdomyosarcoma

➤ *Explanation:*

- * *A. Dermatofibroma: This is a benign skin lesion and is not associated with t(X;18) translocation.*
- * *B (Correct): This type of soft tissue sarcoma is known for the characteristic t(X;18) translocation, which involves the fusion of the SYT gene on chromosome 18 with the SSX1, SSX2, or SSX4 gene on chromosome X. This translocation is a hallmark feature of synovial sarcoma.*
- * *C. This is a rare, high grade soft tissue sarcoma, but it does not show characteristic t(X;18) translocation.*
- * *D. This is a malignant tumor of fat cells but is not associated with t(X;18) translocation.*
- * *E. This a soft tissue sarcoma of skeletal muscle origin but is not associated with t(X;18) translocation.*

180) Smooth muscle contractility is characterized by ?

- A. Rapid cycling of cross bridges
- B. Low O₂ consumption
- C. Slow cycling of cross bridges, low both energy & O₂ consumption
- D. Low energy consumption
- E. Slow cycling of cross bridges

➤ Explanation:

* A: Rapid cycling of cross bridges is characteristic of skeletal muscle, not smooth muscle. Smooth muscle has slower cross-bridge cycling.

* B: While smooth muscle does have lower energy consumption than skeletal muscle, the primary characteristic of smooth muscle contractility is the slow cycling of cross-bridges and reduced energy and oxygen consumption, rather than just low oxygen consumption.

* C (Correct): Smooth muscle contraction is slower due to slower cross-bridge cycling. Additionally, smooth muscle is more energy-efficient than skeletal muscle, leading to low overall energy and oxygen consumption. This is the most accurate description.

* D: While smooth muscle does consume less energy compared to skeletal muscle, the key feature of smooth muscle contractility is the slow cycling of cross-bridges, not just low energy consumption.

* E: This part is true for smooth muscle, but the full characteristic includes both slow cross-bridge cycling and low energy and oxygen consumption, making answer C more comprehensive.

181) Regarding treatment of ACNE VULGARIS, the following are adverse effects of ISOTRETINOIN, EXCEPT?

- A. Teratogenicity
- B. Increase of liver function tests.
- C. Extreme Xerosis.
- D. Increase of triglycerides.
- E. Heart failure of the pregnant woman.

➤ Explanation:

* A. Teratogenicity: Isotretinoin is highly teratogenic and can cause severe birth defects if taken during pregnancy. This is a known and well-documented adverse effect.

* B. Liver function tests: Isotretinoin can elevate liver enzymes, leading to liver dysfunction in some patients. Regular monitoring of liver function tests is required during treatment.

* C. Extreme Xerosis: Xerosis (dryness of the skin) is a common side effect of isotretinoin. The drug significantly reduces sebaceous gland activity, leading to dry skin, lips, and eyes.

* D. Increase of triglycerides: Isotretinoin can cause an increase in triglyceride levels, which may require monitoring of lipid profiles during treatment.

* E (False statement): Heart failure in pregnant women is not a recognized adverse effect of isotretinoin. While isotretinoin is contraindicated in pregnancy due to teratogenic effects, it does not directly cause heart failure in pregnant women.

182) All of the following muscles share in adduction of the shoulder joint, except?

- A. Subscapularis
- B. Teres major
- C. Supraspinatus
- D. Infraspinatus
- E. Teres minor

➤ *Explanation:*

* *A. Subscapularis:* The subscapularis muscle is part of the rotator cuff group and is responsible for internal rotation and adduction of the shoulder joint.

* *B. Teres major:* The teres major muscle helps with adduction and internal rotation of the shoulder joint.

* *C (Correct):* The supraspinatus muscle primarily abducts the shoulder joint (especially in the first 15 degrees). It does not contribute to shoulder adduction, which makes it the correct answer here.

* *D. Infraspinatus:* The infraspinatus muscle is involved in external rotation of the shoulder, but it can also assist in adduction, particularly when the arm is extended and internally rotated.

* *E. Teres minor:* The teres minor muscle is also part of the rotator cuff group and aids in external rotation, but it also plays a role in adduction, especially when the shoulder is extended.

183) Where is the fovea?

- A. Just below and behind the center of the head of femur
- B. Just below the center of the head of femur
- C. In the center of the head of femur
- D. Just behind the center of the head of femur
- E. Just above and behind the center of the head of femur

➤ *Explanation:*

* *The fovea (also known as the fovea capitis femoris) is a small pit or depression located on the femoral head. It is situated slightly below the center of the head of the femur, and it serves as the attachment point for the ligamentum teres, which connects the femur to the acetabulum of the pelvis.*

So, option B is the correct answer.

184) The intervertebral discs are composed of?

- A. A matrix dominated by collagen type II
- B. Elastic cartilage
- C. Elastic connective tissue
- D. Fibrocartilage
- E. Hyaline cartilage

➤ *Explanation:*

A: A matrix dominated by collagen type II is part of the disc, but it doesn't fully describe the composition.

B: Elastic cartilage is found in structures like the ear, not the intervertebral discs.

C: Elastic connective tissue isn't the primary composition of intervertebral discs.

D (Correct): The intervertebral discs are composed of fibrocartilage, which consists primarily of:

- * Type I collagen (for tensile strength) and Type II collagen (for elasticity).
 - * A gel-like substance called proteoglycans is present in the nucleus pulposus, which helps in absorbing shock.
 - * The annulus fibrosus (the outer portion of the intervertebral disc) is made of fibrocartilage, providing strength and resistance to pressure.
 - * The nucleus pulposus (inner part) is a more gelatinous material that helps cushion and absorb impact.
- E: Hyaline cartilage is found in joints, not intervertebral discs.

185) Stair-case phenomenon?

- A. May caused by cooling of the muscle.
- B. May occur in skeletal and cardiac muscle. ✓✓✓
- C. May be caused by increase K^+ and increase Na^+ intracellularly.
- D. May be caused by increase K^+ and decrease Na^+ intracellularly.
- E. May be caused by increase K^+ and increase Ca^{++} intracellularly.

➤ Explanation:

* The staircase phenomenon (or treppe) refers to an increase in the strength of muscle contraction that occurs when a muscle is repeatedly stimulated at a constant frequency. This phenomenon is typically observed when the muscle is stimulated at a low frequency, and the force of contraction gradually increases with each subsequent stimulus.

A: Cooling can affect muscle function, it is not the primary cause of the staircase phenomenon.

B (Correct): The staircase phenomenon can occur in both skeletal and cardiac muscles. It is a general response of muscle tissue to repeated stimulation, where each contraction becomes stronger, leading to a staircase-like pattern.

Options C, D, E: These describe various changes in ion concentrations that can affect muscle function, but they are not directly responsible for the staircase phenomenon.

186) Which of the following is INCORRECTLY paired?

- A. Ruffini's corpuscles reticular layer and respond to continuous stress
- B. Pacinian corpuscle large receptive field
- C. Merkel's corpuscle most sensitive non-capsulated modality
- D. Meissner's corpuscle low frequency stimuli
- E. Free nerve ending epidermis complex modality

➤ Explanation:

* A. Ruffini's corpuscles: Ruffini's corpuscles are located in the reticular layer of the dermis and are sensitive to continuous stress and skin stretch.

* B. Pacinian corpuscle: Pacinian corpuscles are large receptors with a large receptive field that respond to deep pressure and vibration.

* C. Merkel's corpuscle: Merkel's corpuscles are non-capsulated and located in the epidermis, especially in areas with high tactile acuity (like fingertips). They are sensitive to sustained pressure and texture. They are considered the most sensitive among non-capsulated receptors.

* D. Meissner's corpuscle: Meissner's corpuscles are sensitive to light touch and low-frequency stimuli, primarily found in the dermal papillae of glabrous (hairless) skin. This pairing is correct.

* E (Incorrect): Free nerve endings are present in epidermis and other tissues and are typically associated with pain (nociception) and temperature sensation, not complex modalities. They are non-capsulated and respond to a wide variety of stimuli, but they are not typically classified as "complex modalities."

187) Which of the following statements is TRUE regarding necrotizing fasciitis?

A. Slow spreading of redness area.

B. Low grade pain and tenderness over the involved skin.

C. Caused only by anaerobic bacteria.

D. Anesthesia is the hallmark symptom.

E. High mortality rates.

➤ Explanation:

* A. Redness: Necrotizing fasciitis is characterized by rapid spread of infection, often within hours, not slow spreading.

* B. Pain: The pain is often severe and out of proportion to the appearance of the skin. It is not typically low grade.

* C. Bacteria: Necrotizing fasciitis is caused by a mixture of both aerobic and anaerobic bacteria, not only anaerobes.

* D. Anesthesia: While anesthesia (loss of sensation) may occur due to nerve involvement, it is not the hallmark symptom. The hallmark symptoms are severe pain, swelling, fever, and rapid progression.

* E (Correct): Necrotizing fasciitis is a severe, life-threatening condition with a high mortality rate if not treated promptly.

188) Smooth muscle are characterized by all the following EXCEPT?

A. Contains Calmodulin instead of troponin

B. Its membrane potential is unstable

C. Have a resting membrane potential is about -50mV

D. They are relaxed by acids and excess calcium

E. Its contraction increased with warming

➤ Explanation:

* A. Calmodulin: Smooth muscle lacks troponin and instead uses calmodulin to regulate contraction.

* B. Unstable potential: Smooth muscle cells exhibit spontaneous fluctuations in membrane potential, known as slow waves.

* C. Resting potential: The resting membrane potential of smooth muscle is typically around -50 to -60 mV, which is less negative than skeletal muscle.

* D. (Correct answer) Relaxation: Acidosis (low pH) can impair muscle contraction, but it does not necessarily lead to relaxation in all cases. Excess calcium enhances smooth muscle contraction, as calcium binds to calmodulin, activating myosin light-chain kinase (MLCK), leading to contraction.

* E. Higher temperatures enhance enzyme activity (such as MLCK), increasing contraction efficiency.

189) One of the following neoplasm can be detected by myogenin and MYOD-I immunohistochemical stains?

A. Pleomorphic fibroblastic sarcoma.

B. Dermatofibroma.

C. Liposarcoma.

D. Rhabdomyosarcoma

E. Synovial sarcoma

➤ Explanation:

* Myogenin and MYOD-1 are muscle-specific transcription factors that play a crucial role in skeletal muscle differentiation.

* These markers are highly specific for rhabdomyosarcoma (RMS) and are used in immunohistochemistry to confirm its diagnosis.

* Rhabdomyosarcoma (RMS) is a malignant tumor that arises from skeletal muscle precursors.

So, option E is the correct answer.

190) The H zone?

A. Is constant in width during contraction

B. Contains both actin and myosin

C. Contains only actin

D. Is divided by the M line.

E. Increases in width during contraction.

➤ Explanation:

* The H zone is the region of the sarcomere that:

* Is located within the A band.

* Contains only thick filaments (myosin), but no actin. D is the correct answer.

* Is bisected by the M line, which serves as the attachment site for myosin filaments.

* Option A & E: The H zone narrows as actin filaments slide over myosin during contraction. The H zone decreases in width as muscle contracts.

* Option B & C: The H zone contains only myosin filaments, not actin.

191) The following are adverse effects of methoxsalen in PUVA therapy except?

A. Increase in ANF titer in blood.

B. Actinic keratosis.

C. Hyperlipidemia.

D. Skin cancer.

E. Photoaging.

➤ Explanation:

* Methoxsalen (a psoralen) is used in PUVA therapy (Psoralen + UVA) to treat conditions like psoriasis and vitiligo.

A. PUVA therapy can trigger autoimmune responses, leading to increased antinuclear factor (ANF) titers.

B. PUVA therapy can cause precancerous skin changes like actinic keratosis due to prolonged UV exposure.

C. (Correct answer): PUVA therapy is not known to cause hyperlipidemia as a side effect.

Methoxsalen does not significantly affect lipid metabolism.

D. Long-term PUVA therapy increases the risk of squamous cell carcinoma and melanoma.

E. UVA exposure accelerates skin aging, leading to wrinkles, pigmentation changes, and loss of elasticity.

192) What are the types of the shoulder joint?

A. Ellipsoid

B. Hinge

C. Condylloid

D. Ball and socket

E. Saddle

➤ Explanation:

* A. Ellipsoid: Found in joints like the radiocarpal (wrist) joint, allowing biaxial movement but not full rotation.

* B. Hinge: Found in joints like the elbow and knee, permitting movement in one plane (flexion and extension).

* C. Condylloid: Similar to ellipsoid joints; found in the metacarpophalangeal joints, allowing movement in two planes.

* D. (Correct answer) The shoulder joint (glenohumeral joint) is a synovial ball-and-socket joint, which allows for the greatest range of motion among all joint types. It consists of:

* The head of the humerus (ball)

* The glenoid cavity of the scapula (socket)

* E. Saddle: Found in the thumb (1st carpometacarpal joint), allowing biaxial movement but not full rotation.

193) A 26-year-old man has complained of a left arm On physical examination. a 4- cm area Of the lateral upper left arm exhibits swelling and redness with pain on palpation. A radiograph of the left arm shows no fracture. Three months later, there now is a 2-cm, painful, well-circumscribed, subcutaneous mass at the site of the original injury. A radiograph shows a solid soft-tissue mass. Which of the following lesions is most likely to be present?

A. Superficial fibromatosis

B. Lipoma

C. Malignant fibrous histiocytoma

- D. Nodular fasciitis
- E. Organizing abscess

➤ *Explanation:*

- * A. *Superficial fibromatosis: Slow-growing, fibrotic condition affecting palmar/plantar fascia (e.g., Dupuytren's contracture), not a rapidly growing mass after trauma.*
- * B. *Lipoma: Painless, slow-growing, soft mass; not associated with prior trauma or inflammation.*
- * C. *Malignant fibrous histiocytoma: A malignant, aggressive tumor seen in older adults; less likely in a young patient with a history of trauma and a self-limiting lesion.*
- * D. *(Correct answer) Nodular fasciitis is a benign, self-limiting, reactive proliferation of fibroblasts and myofibroblasts, often triggered by trauma. It commonly occurs in the upper extremities, presenting as a rapidly growing, painful, well-circumscribed mass. Radiologically, it appears as a soft-tissue mass without aggressive features like bone destruction.*
- * E. *Organizing abscess: Would likely present with fluctuance, systemic symptoms (fever), and not a firm, circumscribed soft-tissue mass.*

194) One of the following antigens usually induces urticaria by Mast cell-dependent, IgE-independent pathogenesis?

- A. Drugs
- B. Pollen
- C. Food
- D. Insect venom
- E. Opiates

➤ *Explanation:*

➤ *Urticaria (hives) can be triggered by various mechanisms. Mast cell activation plays a central role, and it can occur through:*

1- *IgE-dependent mechanisms – Typical in allergic reactions (e.g., pollen, food, insect venom).*

2- *IgE-independent mechanisms – Certain substances directly stimulate mast cells, leading to histamine release without IgE involvement.*

- * A. *Drugs: Some drugs (e.g., penicillin) can cause IgE-mediated allergic urticaria.*
- * B. *Pollen: Causes IgE-mediated allergic reactions (e.g., seasonal allergies).*
- * C. *Food: Common cause of IgE-mediated urticaria (e.g., nuts, shellfish).*
- * D. *Insect venom: Typically triggers IgE-mediated hypersensitivity reactions.*
- * E. *(Correct): Opiates (like morphine) can directly trigger mast cell degranulation, causing urticaria through an IgE-independent pathway.*

195) All the muscles attached to the bicipital (intertubercular) groove?

- A. Adduct the arm.
- B. Abduct the arm (shoulder joint).
- C. Abduction and medial rotation
- D. Medial rotation of the arm.

E. Adduction and medial rotation

- *Explanation: Option E is the correct answer.*
- *The bicipital (intertubercular) groove of the humerus serves as the attachment site for three important muscles:*
 - * *Pectoralis Major – Attaches to the lateral lip of the groove.*
 - * *Latissimus Dorsi – Attaches to the floor of the groove.*
 - * *Teres Major – Attaches to the medial lip of the groove.*
- *Functions of These Muscles:*
 - * *All three muscles contribute to adduction of the arm (pulling the arm toward the body).*
 - * *All three contribute to medial (internal) rotation of the arm at the shoulder joint.*
 - * *None of them contribute to abduction (which is mainly done by the deltoid and supraspinatus).*

196) Structures may found in the submandibular triangle include followings except?

- A. Parts of the facial artery and vein
- B. The submental artery
- C. The hypoglossal nerve
- D. The mylohyoid muscle Nerve
- E. The anterior jugular vein

➤ *Explanation:*

➤ *The submandibular (digastric) triangle is a subdivision of the anterior triangle of the neck and is bounded by:*

* *Superiorly: The mandible.*

* *Inferiorly: The anterior and posterior bellies of the digastric muscle.*

A. *Facial artery and vein: The facial artery passes through the submandibular triangle to supply the face. The facial vein runs with it and drains into the internal jugular vein.*

B. *Submental artery: The submental artery, a branch of the facial artery, is found in this region.*

C. *Hypoglossal nerve: The hypoglossal nerve runs deep to the submandibular gland and provides motor innervation to the tongue muscles.*

D. *Mylohyoid muscle Nerve: The nerve to the mylohyoid, a branch of the mandibular nerve (V3), is present here and innervates the mylohyoid and anterior belly of digastric.*

E (The Exception): *The anterior jugular vein is located more anteriorly in the midline of the neck, not within the submandibular triangle.*

197) Regarding treatment of Acute Gout, all the following are true EXCEPT?

- A. Colchicine should be used during first 24 hours of the attack.
- B. life style changes are also important.
- C. Corticosteroids are also included in treatment.
- D. Probenecid is the first line of treatment.
- E. NSAIDS are important for treatment.

➤ Explanation:

* Acute gout is characterized by sudden, severe pain, swelling, and redness in joints due to the deposition of monosodium urate crystals. The treatment focuses on reducing inflammation and pain, not lowering uric acid levels initially.

A. Colchicine: True. Colchicine should be used during the first 24 hours of the attack. It is most effective if given within the first 24 hours of symptom onset.

B. Life style changes: True. Weight loss, reducing alcohol consumption, and avoiding purine-rich foods (e.g., red meat, seafood) can help prevent future attacks.

C. Corticosteroids: True. Oral or intra-articular corticosteroids are used when NSAIDs or colchicine are contraindicated.

D. Probenecid (The False statement): Probenecid is a uricosuric agent used for chronic gout, not acute attacks. It lowers uric acid levels but does not provide immediate relief in acute gout.

In acute attacks, urate-lowering therapy should not be started or altered.

E. NSAIDs: True. NSAIDs (e.g., indomethacin, naproxen) are first-line treatment for acute attacks.

198) The virus that lead to inhibit the activity of proteins encoded p53 gene is:

A- HPV.

B- B19.

C- HSV.

D- Small box.

E- VZV.

➤ Explanation:

A. Correct answer: HPV (Human Papillomavirus), particularly high-risk strains (like HPV-16 and HPV-18), produces proteins (such as E6) that bind to and degrade the p53 protein, thereby inhibiting its tumor-suppressing activity. This inhibition of p53 allows infected cells to avoid cell cycle arrest or apoptosis, contributing to the development of cancers such as cervical cancer.

B. B19: While B19 virus can cause erythema infectiosum (slapped cheek syndrome), it does not significantly inhibit p53 activity in the same way as HPV does.

C. HSV: While HSV can cause a variety of infections, it does not directly inhibit p53 in the same manner as HPV.

D. Small box: Smallpox virus does not inhibit p53 as a primary mechanism. Its main effects are on immune evasion and skin lesions.

E. VZV: VZV does not directly interfere with p53 in the way HPV does.

* The p53 gene is a tumor suppressor gene that plays a crucial role in regulating the cell cycle and preventing cancer by initiating apoptosis in damaged cells. Some viruses have evolved mechanisms to inhibit p53 activity, allowing infected cells to survive and replicate.

199) Which of the following nerves supplied the angle of the mandible:

A- Lesser occipital nerve.

B- Transverse cutaneous nerve.

C- Great auricular nerve.

D- Suprascapular nerve.

E- Accessory nerve.

➤ Explanation:

A. Lesser occipital nerve: This nerve, also from the cervical plexus (C2), supplies the skin over the lateral side of the neck and the scalp posterior to the ear, but it does not supply the angle of the mandible.

B. Transverse cutaneous nerve: This nerve, another branch of the cervical plexus (C2, C3), provides sensation to the anterior and lateral neck but does not supply the angle of the mandible.

C. Correct answer: The great auricular nerve is a branch of the cervical plexus (C2, C3) and it supplies sensation to the angle of the mandible, as well as the external ear and the skin over the parotid gland. The great auricular nerve travels over the sternocleidomastoid muscle and provides sensory innervation to the skin over the angle of the mandible and the anterior auricle.

D. Suprascapular nerve: This nerve arises from the brachial plexus (C5, C6) and innervates the supraspinatus and infraspinatus muscles, which are located on the shoulder, not the angle of the mandible.

E. Accessory nerve: The accessory nerve (cranial nerve XI) innervates the sternocleidomastoid and trapezius muscles, but it does not provide sensory innervation to the angle of the mandible.

200) The mandibular nerve pass through which foramen of the skull:

A- Foramen spinosum.

B- Foramen ovale.

C- Stylomastoid foramen.

D- Foramen lacerum.

E- Jugular foramen.

➤ Explanation:

A. Foramen spinosum: This foramen transmits the middle meningeal artery and the meningeal branch of the mandibular nerve. It is not the primary passage for the main mandibular nerve.

B. (Correct) Foramen ovale: The mandibular nerve (V3), which is the third division of the trigeminal nerve (cranial nerve V), passes through the foramen ovale in the skull. This foramen is located in the sphenoid bone, and the mandibular nerve exits the cranial cavity through it to innervate the lower part of the face, including the jaw, teeth, and muscles of mastication.

C. Stylomastoid foramen: This foramen transmits the facial nerve (cranial nerve VII) and the stylomastoid artery, but it does not transmit the mandibular nerve.

D. Foramen lacerum: This foramen is largely filled with cartilage and transmits some small vessels and nerves, but it does not transmit the mandibular nerve.

E. Jugular foramen: This foramen transmits several important structures, including the glossopharyngeal nerve (CN IX), vagus nerve (CN X), accessory nerve (CN XI), and the internal jugular vein, but not the mandibular nerve.

201) One of the following is a keratolytic agent:

A- Hydrocortisone.

B- Lotions.

C- Flucanotide.

D- Urea.

➤ *Explanation:*

A. Hydrocortisone: This is a steroidal anti-inflammatory medication, not a keratolytic agent. It is used to reduce inflammation, itching, and swelling in various skin conditions.

B. Lotions: This is a general term for topical preparations and doesn't specifically refer to a keratolytic agent. Some lotions may contain active ingredients with keratolytic properties, but "lotions" themselves aren't categorized this way.

C. Flucanotide: This is a potent corticosteroid used to treat inflammatory skin conditions, but it is not a keratolytic agent. It works by reducing inflammation rather than breaking down skin layers.

D. (Correct answer) Urea is a keratolytic agent, meaning it helps break down the outer layer of the skin (stratum corneum) and facilitates the shedding of dead skin cells. It is commonly used in dermatology for the treatment of conditions such as dry skin, psoriasis, eczema, and calluses.

202) Which of the following is selective COX-2 inhibitor:

A- Meloxicam.

B- Diclofenac.

C- Naproxen.

D- Sulindac.

E- Etoricoxib.

➤ *Explanation:*

A. Meloxicam: While Meloxicam is a COX-2 preferential inhibitor, it is not as selective as Etoricoxib. It has some inhibition of COX-1 as well, though it is more selective for COX-2 than older NSAIDs.

B. Diclofenac: Diclofenac is a non-selective COX inhibitor, meaning it inhibits both COX-1 and COX-2 enzymes, and is not selective for COX-2.

C. Naproxen: Naproxen is also a non-selective COX inhibitor and affects both COX-1 and COX-2.

D. Sulindac: Sulindac is another non-selective COX inhibitor that inhibits both COX-1 and COX-2 enzymes.

E. (Correct answer): Etoricoxib is a selective COX-2 inhibitor, meaning it specifically inhibits the cyclooxygenase-2 (COX-2) enzyme, which is responsible for the production of pro-inflammatory prostaglandins. By selectively targeting COX-2, Etoricoxib provides anti-inflammatory and analgesic effects while generally having a lower risk of gastrointestinal side effects compared to non-selective COX inhibitors.

203) Uricosuric agent:

A- Sulfinpyrazone.

B- Allopurinol.

C- Colchicine.

D- Indomethacin.

➤ *Explanation:*

A. (Correct answer) Sulfinpyrazone: Uricosuric agents are medications that increase the excretion of uric acid in the urine, thus lowering its levels in the blood. Sulfinpyrazone is a uricosuric agent, meaning it works by blocking the renal tubular reabsorption of uric acid, increasing its excretion and helping to reduce the risk of gout flares.

B. Allopurinol: Allopurinol is not a uricosuric agent. It is a xanthine oxidase inhibitor, which decreases the production of uric acid in the body, helping to manage conditions like gout by lowering uric acid levels.

C. Colchicine: Colchicine is not a uricosuric agent. It is an anti-inflammatory medication used to treat acute gout attacks by reducing inflammation rather than altering uric acid levels.

D. Indomethacin: Indomethacin is a nonsteroidal anti-inflammatory drug (NSAID) used to treat pain and inflammation associated with conditions like gout but does not influence uric acid excretion.

204) All of the following are treatment for hyperhidrosis except:

A- Topical steroids.

B- Iontophoresis.

C- Systemic agents.

D- Botulinum toxin.

E- Parasympathoectomy.

➤ Explanation:

A. (Correct answer) Topical steroids: Steroids are mainly used for inflammatory skin conditions (eczema, dermatitis) but do not reduce excessive sweating. They might reduce irritation caused by sweat but are not a treatment for hyperhidrosis itself.

B. Iontophoresis: Uses a mild electrical current to temporarily disable sweat glands, mainly for hands and feet.

C. Systemic agents: Oral anticholinergic medications (e.g., glycopyrrolate, oxybutynin) reduce sweating by blocking acetylcholine.

D. Botulinum toxin: Botox injections block nerve signals to sweat glands, effectively reducing sweating in targeted areas.

E. Parasympathoectomy: A surgical procedure that involves cutting the sympathetic nerve fibers, mainly for severe cases of palmar hyperhidrosis.

205) We must take special care from the sun when UV-index is :

A- 7-8.

B- 2-3.

C- 5-6.

D- 4-5.

E- 3-4.

➤ Explanation:

The UV Index (UVI) is a measure of ultraviolet radiation exposure from the sun. Higher values indicate a greater risk of skin damage and the need for sun protection. (Table provided in image shows 5-6 as Moderate risk where protection is needed).

Answer: A

UV Index	Risk Level	Precautions needed?
1-2	Low	Minimal protection needed
3-5	Moderate	Wear sunglasses, apply sunscreen (SPF 30+) and seek shade during midday.
6-7	High	Use sunscreen, protective clothing and sunglasses Avoid midday sun (10AM-4PM)
8-10	Very High	Extra protection required (wide-brim hat, long sleeves, (SPF 50+), avoid sun exposure.
11+	Extreme	Avoid direct sun exposure as much as possible

206) The dangerous layer of the scalp is:

- A- Skin.
- B- Loose areolar tissue.
- C- Connective tissue.
- D- Aponeurosis.
- E- Pericranium.

➤ Explanation:

• The scalp consists of five layers, which can be remembered using the mnemonic "SCALP":

- * S - Skin
- * C - Connective tissue (dense)
- * A - Aponeurosis (Galea Aponeurotica)
- * L - Loose areolar tissue -> DANGEROUS LAYER
- * P - Pericranium (Periosteum of skull bones)
 - Contains valveless emissary veins, which connect the scalp veins to the dural venous sinuses inside the skull.
 - Infections from the scalp can spread rapidly into the cranial cavity via these veins, leading to intracranial complications such as: Meningitis, Brain abscess, Cavernous sinus thrombosis.
 - It also allows the scalp to move freely over the underlying skull.

Answer: B

207) Which one of the following measures considered as a primary prevention for musculoskeletal injury:

- A- Motorcycle helmets.
- B- Life vests.
- C- Seatbelts.
- D- Bullet proof vests.
- E- Trigger locks on guns.

➤ *Explanation:*

- *Primary Prevention -> Prevents injury before it happens (e.g., helmets, trigger locks).*
- *Secondary Prevention -> Reduces severity after an event (e.g., seatbelts, life vests, bulletproof vests).*

A: Motorcycle Helmets -> Primary -> Prevents head injuries before accidents.

B: Life Vests -> Secondary -> Prevents drowning after falling in water.

C: Seatbelts -> Secondary -> Limits injury after a crash.

D: Bulletproof Vests -> Secondary -> Reduces impact after being shot.

E. Correct: Trigger Locks on Guns -> Primary -> Prevents accidental gun discharge.

208) The leading cause of difference in stain between territorial & interterritorial matrix is:

A- The extracellular matrix richer in GAGs.

B- Collagen type II doesn't form bundles.

C- Proteoglycan complexes bind to the surface of type II collagen fibrils.

D- The refractive index of collagen fibrils and ground substance is the same.

➤ *Explanation:*

A. Correct, The territorial matrix around chondrocytes contains higher concentrations of glycosaminoglycans (GAGs), which attract water and stain more intensely. This is why there is a difference in staining between territorial and interterritorial matrix.

B. While type 2 collagen does not form thick bundles like type 1 collagen, this does not directly cause the staining difference. The staining variation is due to GAG content, not collagen fiber organization.

C. Although proteoglycans interact with type 2 collagen, their binding does not directly cause the staining difference. The staining variation is due to GAG content.

D. The refractive index does not significantly affect staining properties. The key factor is the higher GAG concentration in the territorial matrix, which makes it stain more intensely.

209) Multinucleated giant cells originated from fusion of monocytes:

A- Osteoblast.

B- Osteoprogenitor.

C- Osteoclast.

D- Chondrocyte.

E- Chondroblast.

➤ *Explanation:*

A. Osteoblast: Osteoblasts are bone-forming cells derived from osteoprogenitor cells, not monocytes. They synthesize bone matrix and regulate mineralization.

B. Osteoprogenitor cells are precursor cells that differentiate into osteoblasts, not osteoclasts.

C. (Correct answer): Osteoclasts are multinucleated giant cells that originate from the fusion of monocytes/macrophages. They are responsible for bone resorption and are part of the mononuclear phagocyte system.

D. Chondrocyte: Chondrocytes are cartilage cells derived from chondroblasts. They do not originate from monocytes.

E. Chondroblast: Chondroblasts are cartilage-forming cells derived from mesenchymal stem cells, not monocytes.

210) one of the following statement is wrong regarding muscles of mastication:

A- Upper lateral muscle inserted into articular disc of temporomandibular joint.

B- Lower lateral muscle inserted into pterygoid fovea.

C- Superficial medial muscle originated from maxillary tuberosity.

D- Deep medial muscle originated from medial surface of medial pterygoid.

E- Deep medial muscle originated from medial surface of lateral pterygoid.

➤ *Explanation:*

A: The upper head of the lateral pterygoid muscle inserts into the articular disc of the temporomandibular joint (TMJ), which helps in the depression and protrusion of the jaw.

B: The lower head of the lateral pterygoid muscle inserts into the pterygoid fovea on the neck of the mandible and helps in protrusion and lateral movements of the mandible.

C. The superficial head of the medial pterygoid muscle originates from the maxillary tuberosity and helps in elevation and protraction of the mandible.

D. The deep head of the medial pterygoid muscle actually originates from the medial surface of the lateral pterygoid plate (not contributed to elevation of the mandible).

E. Correct answer, The deep head of the medial pterygoid muscle actually originates from the medial surface of the lateral pterygoid plate (not from the medial surface of lateral pterygoid muscle).

211) Which zone of regions of osteoclast contains lysosomes:

A- Vesicular zone.

B- Clear zone.

C- Basal zone.

D- Sealing zone.

➤ *Explanation:*

A. Correct answer, This zone contains lysosomes that are involved in the degradation of bone matrix. These lysosomes release enzymes that break down the mineralized bone tissue during the process of bone resorption.

B. Clear zone: This zone is located near the osteoclast's membrane, and it helps to anchor the osteoclast to the bone surface, but it does not contain lysosomes.

C. Basal zone: The basal zone is associated with the basal membrane of the osteoclast, helping with cellular structure and support, but it is not where lysosomes are located.

D. Sealing zone: The sealing zone is where the osteoclast seals itself to the bone surface, creating a tight barrier to allow for the resorption process. It also doesn't contain lysosomes.

212) Which layer of the epidermis called prickle cell layer:

A- Basale.

- B- Spinosum.
- C- Granulosum.
- D- Lucidum.
- E- Corneum.

➤ *Explanation:*

The stratum spinosum is commonly called the prickly cell layer because the cells in this layer have spiny or prickly projections when viewed under a microscope. These projections are due to the desmosomal connections between the keratinocytes, which give the appearance of spines or prickles.

Answer: B

213) Which structure of the skull related to middle meningeal artery:

- A- Asterion.
- B- Infratemporal fossa.
- C- Suprameatal triangle.
- D- Pterion.
- E- Pterygomandibular fossa.

➤ *Explanation:*

- A. Asterion: Landmark, but not directly related to the middle meningeal artery.
- B. Infratemporal fossa: Contains muscles and nerves, not related to the artery.
- C. Suprameatal triangle: Near the external ear, not related to the artery.
- D. (Correct answer), Pterion: Directly related to the middle meningeal artery, injury here can cause epidural hematoma.
- E. Pterygomandibular fossa: Not related to the middle meningeal artery.

214) One of the following nerve doesn't supply the upper eyelid:

- A- Supratrochlear.
- B- Supraorbital.
- C- Infratrochlear.
- D- Infraorbital.
- E- Palpebral branch of lacrimal.

➤ *Explanation:*

- A. Supratrochlear: This nerve is a branch of the frontal nerve, which is a branch of the ophthalmic division (V1) of the trigeminal nerve. It supplies sensory innervation to the upper eyelid.
- B. Supraorbital: Also a branch of the frontal nerve, it provides sensory innervation to the forehead and the upper eyelid.
- C. Infratrochlear: This is a branch of the nasociliary nerve (also from the ophthalmic division of the trigeminal nerve). It supplies the medial part of the upper eyelid and the skin around the eye.

D. (Correct answer), *Infraorbital*: This nerve is a branch of the maxillary division (V2) of the trigeminal nerve, and it provides sensory innervation to the lower eyelid, cheek, and upper lip. It does not supply the upper eyelid.

E. *Palpebral branch of lacrimal*: This branch of the lacrimal nerve (which is a branch of the ophthalmic division of the trigeminal nerve) supplies sensory innervation to the upper eyelid.

215) Which of the neck can turn the face to the same side:

A- Rectus capitis posterior major.

B- Rectus capitis anterior.

C- Rectus capitis posterior minor.

D- Rectus capitis lateralis.

E- Superior oblique.

➤ *Explanation:*

A. Correct, This muscle helps in turning the head to the same side (*ipsilateral rotation*). It is located in the posterior neck and attaches to the spinous process of the axis (C2) and the occipital bone.

B. *Rectus capitis anterior*: This muscle primarily helps in flexing the head forward, not in rotating it to the same side.

C. *Rectus capitis posterior minor*: This muscle is involved in extending the head, not in rotating it.

D. *Rectus capitis lateralis*: This muscle mainly helps in lateral flexion (tilting the head sideways) rather than rotation.

E. *Superior oblique*: This muscle is involved in rotating the head to the opposite side (*contralateral rotation*), not the same side.

216) All of the following are deep relations of lateral pterygoid muscle except:

A- Lingual nerve.

B- Auriculotemporal nerve.

C- Middle meningeal artery.

D- Chorda tympani.

E- Posterior auricular nerve.

➤ *Explanation:*

A. *Lingual nerve*: The lingual nerve is a deep relation of the lateral pterygoid muscle. It passes through the infratemporal fossa and runs just medial to the muscle.

B. *Auriculotemporal nerve*: This nerve is another deep relation of the lateral pterygoid muscle. It also passes through the infratemporal fossa and runs closely with the lateral pterygoid muscle.

C. *Middle meningeal artery*: The middle meningeal artery passes through the infratemporal fossa and is a deep relation of the lateral pterygoid muscle.

D. *Chorda tympani*: This is a branch of the facial nerve that travels with the lingual nerve, passing in close proximity to the lateral pterygoid muscle.

E. Correct answer, Posterior auricular nerve: This nerve does not have a deep relation with the lateral pterygoid muscle. It is a branch of the facial nerve and does not pass through the infratemporal fossa or come in close contact with the lateral pterygoid muscle.

217) Which of these decrease smooth muscle membrane potential:

- A- Norepinephrine.
- B- Cold.
- C- Stretch.
- D- Acetylcholine.
- E- Parasympathetic.

➤ *Explanation:*

A. Norepinephrine: Norepinephrine typically increases the smooth muscle membrane potential, causing depolarization and contraction in most smooth muscles, especially in blood vessels.

B. Correct answer, Cold generally decreases the smooth muscle membrane potential. It causes a hyperpolarizing effect, which can lead to smooth muscle relaxation. This is why blood vessels constrict in response to cold temperatures (a process known as vasoconstriction).

C. Stretch: Stretch of smooth muscle usually increases the membrane potential and can induce a contractile response (the myogenic response), which helps regulate blood flow.

D. Acetylcholine: Acetylcholine generally depolarizes smooth muscle membranes, causing muscle contraction, especially in the presence of parasympathetic stimulation.

E. Parasympathetic: Parasympathetic stimulation typically releases acetylcholine, which decreases membrane potential (depolarizes the membrane) and promotes smooth muscle contraction.

218) Most common bone tumor in children present in :

- A- Epiphysis.
- B- Vertebrae.
- C- Metaphysis of long bone.
- D- Diaphysis.
- E- Skull.

➤ *Explanation:*

A. Epiphysis: Although some bone tumors can affect the epiphysis (e.g., giant cell tumors), these are less common in children.

B. Vertebrae: Vertebral bone tumors are not the most common in children. They are more commonly seen in adults.

C. Correct answer, Metaphysis of long bone: The most common bone tumors in children, such as osteosarcoma and Ewing's sarcoma, typically present in the metaphysis of long bones (e.g., distal femur, proximal tibia).

D. Diaphysis: Bone tumors in the diaphysis are less common in children. The diaphysis is more commonly involved in adults.

E. Skull: While tumors can arise in the skull, they are less common in children compared to long bones.

219) Macule, papule, vesicle and crust. In which virus this skin lesions will occur:

- A- B19.
- B- Robeol.
- C- Small box.
- D- VZV.
- E- Rubella.

➤ Explanation:

A. B19: B19 virus causes erythema infectiosum (fifth disease), which presents with a "slapped cheek" rash and a lacy red rash on the body, not macules, papules, vesicles, and crusts.

B. Robeol: Rubeola (measles) typically presents with a maculopapular rash, not vesicles or crusts. The rash starts at the hairline and spreads downwards.

C. Small box: Smallpox (variola) presents with pustules, not macules, papules, and vesicles in the typical sequence.

D. Correct answer, VZV: Chickenpox (varicella) caused by VZV typically progresses through macules, papules, vesicles, and then crusts. This sequence of lesions is characteristic of varicella.

E. Rubella: Rubella (German measles) presents with a maculopapular rash, not vesicles or crusts.

220) The sole of the foot inclined inward, this anomaly called :

- A- Talipes Valgus.
- B- Talipes calcenus.
- C- Talipes varus.
- D- Talipes equinus.
- E- Hallux valgus.

➤ Explanation:

A. Talipes Valgus: This condition refers to the outward angulation of the foot, not inward.

B. Talipes calcenus: This refers to the abnormal position of the foot where the heel is prominent, and the toes are pointing upward, often due to dorsiflexion of the ankle.

C. Correct answer, Talipes varus: This is the condition where the sole of the foot is inclined inward, and the foot is turned toward the midline of the body.

D. Talipes equinus: This refers to a condition where the foot is in a downward position (like walking on tiptoes) due to plantar flexion of the ankle.

E. Hallux valgus: This is a condition involving the deviation of the big toe outward, often resulting in a bunion, but not related to the inward inclination of the foot.

221) Alveolar rhabdomyosarcoma is type of malignant mesenchymal tumour and it is come from mutation by fusion between two genes, these genes are :

- A- MYH9-USP6.
- B- SS18-SSX.

- C- EWSR1-FL1.
- D- MDM2-CDK4.
- E- FOXO1-PAX3.

➤ *Explanation:*

- A. MYH9-USP6: This fusion gene is associated with a different type of tumor, specifically nodular fasciitis, not alveolar rhabdomyosarcoma.
- B. SS18-SSX: This fusion gene is associated with synovial sarcoma, not rhabdomyosarcoma.
- C. EWSR1-FL1: This fusion gene is related to Ewing's sarcoma, not rhabdomyosarcoma.
- D. MDM2-CDK4: These are genes associated with well-differentiated liposarcoma, not rhabdomyosarcoma.
- E. Correct answer, FOXO1-PAX3: This is the correct fusion gene mutation associated with alveolar rhabdomyosarcoma, which is a subtype of rhabdomyosarcoma. The fusion of these two genes leads to the development of this cancer.

222) Potts disease is:

- A- Skeletal tuberculosis.
- B- Sclerotic phase of pagets.
- C- Lytic phase of pagets.
- D- Pyogenic osteomyelitis.

➤ *Explanation:*

- A. Correct answer, Skeletal tuberculosis: Potts disease refers to tuberculosis of the spine, which is a form of skeletal tuberculosis. It typically affects the vertebrae, leading to bone destruction, kyphosis, and abscess formation.
- B. Sclerotic phase of pagets: This phase refers to a stage in Paget's disease of bone where there is increased bone formation and sclerosis, but it is not related to Potts disease.
- C. Lytic phase of pagets: The lytic phase of Paget's disease involves increased bone resorption and weakening of the bones, but this is also unrelated to Potts disease.
- D. Pyogenic osteomyelitis: Pyogenic osteomyelitis is an infection of the bone caused by bacteria, typically staphylococci, but it is not related to Potts disease, which is caused by Mycobacterium tuberculosis.

223) Baby with no philtrum in:

- A- Median harelip.
- B- Medial harelip.
- C- Unilateral harelip.
- D- Bilateral harelip.

➤ *Explanation:*

- A. Correct answer, Median harelip: This refers to a type of cleft lip where there is a cleft in the middle of the upper lip, which may result in the absence or underdevelopment of the philtrum, the vertical groove in the middle of the upper lip.

B. Medial harelip: This is not a common or standard term used in describing cleft lips. It may be confused with "median harelip," but it's not typically used in clinical practice.

C. Unilateral harelip: This type of cleft lip affects one side of the upper lip, typically resulting in a cleft lip with a normal philtrum on the unaffected side.

D. Bilateral harelip: This type of cleft lip affects both sides of the upper lip, but the philtrum is typically not absent; instead, it may appear underdeveloped or distorted.

224) All of the following are true about inflammatory myopathy except?

A- Treated successfully with corticosteroids.

B- Autoimmune disorder.

C- Endomysial inflammatory infiltrate contain CD4+.

D- Increased expression of MHC I.

➤ *Explanation:*

A. Treated successfully with corticosteroids: Inflammatory myopathies (such as polymyositis and dermatomyositis) are often treated with corticosteroids, which help reduce inflammation and muscle damage. This statement is true.

B. Autoimmune disorder: Inflammatory myopathies are considered autoimmune disorders where the body's immune system attacks the muscles. This is true.

C. Correct answer, Endomysial inflammatory infiltrate contain CD4+: Inflammatory myopathies are characterized by inflammatory infiltrates in the muscles, but these infiltrates primarily contain CD8+ T cells rather than CD4+ T cells. CD8+ T cells are cytotoxic T cells involved in the muscle damage seen in these conditions. Thus, this statement is incorrect.

D. Increased expression of MHC I: In inflammatory myopathy, there is often increased expression of major histocompatibility complex (MHC) class I molecules on the muscle fibers, which is a hallmark of the immune-mediated muscle damage in these conditions. This is true.

225) One of the following is not found in Klippel Feil syndrome:

A- Fusion of two lumbar vertebrae.

B- Short neck.

C- Facial asymmetry.

D- Low hairline.

E- Limited neck mobility.

➤ *Explanation:*

A. Correct answer, Fusion of two lumbar vertebrae: Klippel-Feil syndrome is characterized by congenital fusion of cervical (neck) vertebrae, not lumbar vertebrae. The syndrome typically involves the cervical spine, so the fusion of two lumbar vertebrae is not a typical feature.

B. Short neck: A short neck is a common feature of Klippel-Feil syndrome due to the fusion of cervical vertebrae, leading to limited neck movement and a visibly shortened neck.

C. *Facial asymmetry: Facial asymmetry can be associated with Klippel-Feil syndrome, as the abnormal development of the cervical spine may lead to misalignment of the head and neck, affecting the symmetry of the face.*

D. *Low hairline: A low hairline is often seen in Klippel-Feil syndrome, especially at the back of the neck, due to the abnormal shape of the cervical vertebrae.*

E. *Limited neck mobility: Limited neck mobility is a hallmark of Klippel-Feil syndrome, as the fusion of the cervical vertebrae restricts the normal range of motion of the neck.*

226) One of the following direct control on calcitonin release:

A- Hypocalcemia.

B- Hypophosphatemia.

C- Hypercalcemia.

D- Hyperphosphatemia.

➤ *Explanation:*

A. *Hypocalcemia: Hypocalcemia (low calcium levels) does not directly stimulate calcitonin release. In fact, calcitonin helps to lower calcium levels, so it would be more likely to be released in response to hypercalcemia, not hypocalcemia.*

B. *Hypophosphatemia: Hypophosphatemia (low phosphate levels) does not have a direct effect on calcitonin release.*

C. *Correct answer, Hypercalcemia: Hypercalcemia (high calcium levels) directly stimulates the release of calcitonin from the thyroid gland. Calcitonin works to lower blood calcium levels by inhibiting bone resorption and promoting calcium excretion through the kidneys.*

D. *Hyperphosphatemia: Hyperphosphatemia (high phosphate levels) does not directly control calcitonin release.*

227) Melanin is in all of the following except :

A- Hair.

B- Nail.

C- Skin.

D- Brain stem.

E- Spinal cord.

➤ *Explanation:*

A. *Hair: Melanin is present in hair, giving it its color. Different types of melanin (eumelanin and pheomelanin) determine the color of the hair.*

B. *Nail: Melanin can also be present in nails, especially in the skin around the nails, but its presence in nails is less significant compared to hair and skin.*

C. *Skin: Melanin is found in the skin, where it plays a critical role in protecting against UV radiation and contributing to skin pigmentation.*

D. Brain stem: Melanin is found in certain areas of the brain, including the brainstem, particularly in neurons like those in the substantia nigra, which are involved in movement and reward.

E. Correct answer, Spinal cord: Melanin is not typically found in the spinal cord in the same way it is in hair, skin, or brain tissue.

228) Which statement is true regarding buccinator muscle :

A- It's nerve supply from temporal and zygomatic nerves.

B- It's upper fibers originate from the alveolar process of maxilla opposite canine teeth.

C- Supplied by buccal branch of mandibular nerve.

D- Blowing.

E- It's lower fibers originate from the alveolar process of mandible opposite pre molar teeth.

➤ *Explanation:*

A: This statement is incorrect. The buccinator muscle is primarily innervated by the buccal branch of the facial nerve (CN VII), not the temporal and zygomatic nerves.

B: This is not accurate. The buccinator muscle originates from the alveolar processes of the maxilla and mandible as well as the pterygomandibular raphe, but not specifically opposite the canine teeth.

C: This statement is incorrect. The buccinator muscle is not supplied by the buccal branch of the mandibular nerve. It is actually innervated by the buccal branch of the facial nerve (CN VII).

D: This statement is correct. The buccinator muscle is responsible for compressing the cheeks against the teeth, which is essential in actions like blowing or sucking.

E: This statement is incorrect. The lower fibers of the buccinator muscle originate from the mandible near the molar region, not opposite the premolar teeth.

229) Styloid process give attachment for all of the following except :

A- Stylomandibular ligament.

B- Stylohyoid muscle.

C- Styloglossus muscle.

D- Stylohyoid ligament.

E- Stylolaryngeus muscle.

➤ *Explanation:*

* A: The stylomandibular ligament attaches to the styloid process and extends to the angle of the mandible.

* B: The stylohyoid muscle originates from the styloid process and attaches to the body of the hyoid bone.

* C: The styloglossus muscle originates from the styloid process and inserts into the tongue.

* D: The stylohyoid ligament attaches to the styloid process and helps connect it to the hyoid bone.

* E: Correct answer, There is no muscle called the stylolaryngeus muscle. This is the incorrect choice, as no such muscle attaches to the styloid process.

230) Lymphatic drainage in carotid triangle supplied by :

A- Submandibular lymph nodes.

B- Submental lymph nodes.

- C- Deep cervical lymph nodes.
- D- Prelaryngeal lymph nodes.
- E- Pretracheal lymph nodes.

➤ *Explanation:*

A. *Submandibular lymph nodes:* These lymph nodes are located beneath the mandible and are involved in draining areas of the lower face and parts of the oral cavity. They are not the primary drainage of the carotid triangle.

B. *Submental lymph nodes:* These lymph nodes are located beneath the chin and drain the chin, lower lip, and parts of the floor of the mouth. They do not directly drain the carotid triangle.

C. *Correct answer,* The deep cervical lymph nodes are located along the internal jugular vein and are the primary lymphatic drainage for the carotid triangle. They receive lymph from several regions, including the head and neck.

D. *Prelaryngeal lymph nodes:* These are located near the larynx and are involved in draining the laryngeal region. They do not primarily drain the carotid triangle.

E. *Pretracheal lymph nodes:* These lymph nodes are located in front of the trachea and are involved in draining the neck and thyroid region, but not the carotid triangle.

231) A patient complaining from right knee pain, and then experiencing additive ankle pain.

What is the possible diagnosis:

- A- SLE.
- B- Rheumatoid arthritis.
- C- septic arthritis.
- D- Reactive arthritis.

➤ *Explanation:*

A. *SLE:* SLE is a systemic autoimmune disease that can cause joint pain, but it typically affects multiple joints in a non-specific pattern, often with a characteristic butterfly-shaped rash and other systemic symptoms like skin, renal, and cardiovascular issues. It doesn't typically present with a specific sequence like knee followed by ankle pain.

B. *Rheumatoid arthritis:* Rheumatoid arthritis (RA) is a chronic inflammatory disease that primarily affects the small joints and often presents symmetrically. RA can involve larger joints like the knees and ankles, but it's less likely to present as an initial knee pain followed by ankle pain in an additive manner, as in this case.

C. *septic arthritis:* Septic arthritis typically presents with acute, severe pain, redness, swelling, and fever at the affected joint. It usually affects one joint, and while it can spread, it doesn't commonly present with additive pain involving multiple joints like in this case.

D. *Correct answer,* Reactive arthritis is an inflammatory condition that often follows an infection, especially urogenital or gastrointestinal infections. It can cause pain in large joints like the knees and ankles in an additive or migratory pattern. The presentation of right knee pain followed by ankle pain is consistent with reactive arthritis.

232) Kind of bacteria that secrete toxins of scalded skin syndrome:

- A- Staphylococcus aureus.
- B- Streptococcus pyogenes.

➤ *Explanation:*

A. *Correct answer, Staphylococcus aureus: This bacteria is the primary cause of scalded skin syndrome (also known as Ritter's disease), which is due to the secretion of exfoliative toxins. These toxins cause the epidermis to separate from the underlying skin layers, leading to widespread skin blistering and peeling.*

* *Streptococcus pyogenes: This bacteria can cause various skin infections, including impetigo and cellulitis, but it does not typically cause scalded skin syndrome. It is more commonly associated with conditions like scarlet fever and toxic shock syndrome rather than scalded skin syndrome.*

233) One of the following is true regarding tinea capitis :

- A- The most common kind of athlete's foot.
- B- Ring like rash with a raised hand.
- C- Leaving a scar and alopecia after healing.
- D- Mostly in obese and diabetics.
- E- Introduced into subcutaneous tissue through trauma.

➤ *Explanation:*

A. *The most common kind of athlete's foot: This statement is incorrect. Athlete's foot refers to tinea pedis, which affects the feet, not the scalp. Tinea capitis is a fungal infection of the scalp.*

B. *Ring like rash with a raised hand: This description is more characteristic of tinea corporis, a fungal infection of the body, not tinea capitis.*

C. *Correct answer, Leaving a scar and alopecia after healing: This is true. Tinea capitis often leads to scarring alopecia, especially if the infection is severe or untreated for a long period. The fungal infection can cause hair loss and scarring after healing.*

D. *Mostly in obese and diabetics: This is incorrect. While fungal infections can be more common in individuals with diabetes, tinea capitis primarily affects children and is more associated with poor hygiene and close contact rather than obesity or diabetes.*

E. *Introduced into subcutaneous tissue through trauma: This is incorrect. Tinea capitis is a superficial fungal infection of the scalp, not a subcutaneous tissue infection. It is typically spread by direct contact with infected individuals or contaminated objects.*

234) Leading cause of chiclero ulcer is :

- A- Ltropica.
- B- Lmajor.
- C- Laethiopica.
- D- Lmexicana.
- E- Lbrazillensis.

➤ *Explanation:*

- A. *Ltropica*: Causes urban cutaneous leishmaniasis, not typically associated with Chiclero ulcer.
- B. *Lmajor*: Causes cutaneous leishmaniasis but is not the primary cause of Chiclero ulcer.
- C. *Laethiopica*: Causes cutaneous leishmaniasis in Africa, but it's not typically associated with Chiclero ulcer.
- D. Correct answer, *Lmexicana*: Chiclero ulcer, also known as cutaneous leishmaniasis, is a type of skin ulceration caused by infection with certain species of *Leishmania* parasites. The leading cause of Chiclero ulcer is *Leishmania mexicana*, which is transmitted by the bite of infected sandflies.
- E. *Lbrazillensis*: Causes mucocutaneous leishmaniasis, not typically associated with Chiclero ulcer.

235) One of the following is incorrect about trichenilosis :

- A- Man is intermediate host.
- B- Adult is infective stage.
- C- Adult live in small intestine.
- D- Larvae is diagnostic stage.
- E- Treated by mebendazole.

➤ *Explanation:*

- A. Man is intermediate host: Incorrect. Humans are definitive hosts for *Trichinella* species, not intermediate hosts. The intermediate hosts are usually pigs or wild carnivores, where the larvae encyst in the muscle.
- B. Adult is infective stage: Incorrect. The larvae are the infective stage, not the adult worms. After ingestion of undercooked meat, the larvae are released in the intestines, mature into adults, and then produce new larvae that encyst in muscle tissues.
- C. Adult live in small intestine: Correct. The adult *Trichinella* worms reside in the small intestine, where they mate and release larvae.
- D. Larvae is diagnostic stage: Correct. The larvae encysted in muscle tissue are the diagnostic stage of the infection.
- E. Treated by mebendazole: Correct. Mebendazole is commonly used to treat *Trichinella* infections.

Answer: A/B

236) One of the following structure is not lateral relation of psoas major :

- A- Iliacus muscle.
- B- Ilioinguinal nerve.
- C- Femoral nerve.
- D- Iliohypogastric nerve.
- E- Genitofemoral nerve.

➤ *Explanation:*

- A. Iliacus muscle: Lateral to psoas major, filling the iliac fossa.
- B. Ilioinguinal nerve: Lateral to psoas major, running along the posterior abdominal wall.
- C. Femoral nerve: Lateral to psoas major, emerging from the lumbar plexus.
- D. Iliohypogastric nerve: Lateral to psoas major, supplying the abdominal wall.

E. Correct answer, Genitofemoral nerve: Passes through the psoas major (not lateral) and emerges on its anterior surface.

237) One of the following is wrong about infrahyoid muscles :

- A- The four infrahyoid muscles are : sternohyoid, sternothyroid, Omohyoid and thyrohyoid.
- B- All muscles supplied by ansa cervicalis except thyrohyoid only by C1.
- C- Sternohyoid muscle depresses the hyoid bone.
- D- All muscles are innervated by vagus nerve.
- E- Sternohyoid muscle attached to the back of medial part of the clavicle.

➤ Explanation:

* A: The infrahyoid muscles include Sternohyoid, Sternothyroid, Omohyoid (not "Odontoid"), and Thyrohyoid.

* B: All are supplied by the ansa cervicalis (C1-C3) except thyrohyoid, which is supplied by C1 via the hypoglossal nerve (CN XII).

* C: These muscles primarily depress the hyoid bone and larynx during swallowing and speech.

* D: Correct answer, They are NOT innervated by the vagus nerve (CN X).

238) In patient with Steven Johnson syndrome, all of the following consistent with the diagnosis in this patient are true except :

- A- Caused by mycoplasma.
- B- Recent drug exposure.
- C- Detachment to epidermis (more than 30 percent of skin affected).
- D- Discrete confluent zone of basal epidermal necrosis and blister.
- E- Involve mucosa layer.

➤ Explanation:

A. Caused by mycoplasma: *Mycoplasma pneumoniae* can trigger SJS, especially in children.

B. Recent drug exposure: Drugs like sulfonamides, NSAIDs, anticonvulsants, and allopurinol are common triggers.

C. Correct answer, Detachment to epidermis:

SJS and toxic epidermal necrolysis (TEN) are on a spectrum of severe mucocutaneous reactions.

SJS involves <10% of total body surface area (TBSA), whereas TEN involves >30% of TBSA.

If >30% TBSA is affected, the condition is classified as Toxic Epidermal Necrolysis (TEN), not SJS.

D. Discrete confluent zone: Histopathological finding in SJS/TEN.

E. Involve mucosa layer: SJS commonly affects the oral, ocular, and genital mucosa.

239) Which one of the following makes 7th vertebrae not typical :

- A- It has long non bifid spine.
- B- It has no body.
- C- It has odontoid process.
- D- It has facet.
- E- It has short bifid spine.

➤ *Explanation:*

- A. *Correct answer, It has long non bifid spine: The 7th cervical vertebra (C7) is also called vertebra prominens because of its long, prominent, non-bifid spinous process, which can be easily felt at the back of the neck. This feature makes C7 atypical compared to the other cervical vertebrae, which generally have short, bifid spinous processes.*
- B. *It has no body: C7 has a vertebral body, unlike C1 (atlas), which lacks a body.*
- C. *It has odontoid process: The odontoid process (dens) is found on C2 (axis), not C7.*
- D. *It has facet: All cervical vertebrae have facets for articulation, so this does not make C7 atypical.*
- E. *It has short bifid spine: Typical cervical vertebrae have short bifid spinous processes, unlike C7.*

240) When you rotate your head to the left side, which muscle is used :

- A- Trapezius.
- B- Levator scapulae.
- C- Infrahyoid.
- D- Right sternocleidomastoid.
- E- Left sternocleidomastoid.

➤ *Explanation:*

The sternocleidomastoid (SCM) muscle is responsible for rotating the head to the opposite side and tilting it slightly to the same side.

- A. *Trapezius: Primarily elevates and retracts the scapula; does not rotate the head.*
- B. *Levator scapulae: Elevates the scapula and helps in neck lateral flexion, not rotation.*
- C. *Infrahyoid: Mainly involved in swallowing and stabilizing the hyoid bone, not head rotation.*
- D. *Correct answer, Right sternocleidomastoid: Right SCM -> Rotates the head to the left.*
- E. *Left sternocleidomastoid: Would rotate the head to the right, not the left.*

241) Which statement is wrong regarding heat stroke :

- A- Occurs in hot humid atmosphere.
- B- It's most severe form of heat exhaustion.
- C- All heat loss mechanism work.
- D- Intravenous fluid intake is treatment.
- E- Depression of thermoregulatory centre occur.

➤ *Explanation:*

- A. *Occurs in hot humid atmosphere: True. High humidity prevents heat dissipation through sweating, increasing the risk.*
- B. *It's most severe form of heat exhaustion: Heat stroke is a progression from heat exhaustion when the body can no longer cool itself.*
- C. *Correct answer, All heat loss mechanism work: Heat stroke is a life-threatening condition where the body fails to regulate temperature due to prolonged exposure to heat. The thermoregulatory mechanisms stop working, leading to a rapid rise in body temperature (>40°C or 104°F).*

- D. Intravenous fluid intake is treatment: IV fluids help restore hydration and circulation.
- E. Depression of thermoregulatory centre occur: The hypothalamus (body's thermostat) fails, leading to loss of temperature control.

242) A 32 year old woman discovers she is pregnant and eagerly awaits her first ultrasound at 8 weeks gestation. During the ultrasound, the doctor notices an abnormality: the embryo appears small than expected and further examination reveals a loss of somite cells, Which muscle of the following you expect to affect :

- A- Latissimus dorsi.
- B- Rhomboid major.
- C- Trapezius.
- D- Levator scapulae.
- E- Longissimus capitis.

➤ Explanation:

Somites are blocks of mesoderm located on either side of the neural tube in the developing embryo. They give rise to:

- * Sclerotome -> Forms vertebrae and ribs.
- * Dermatome -> Forms dermis of the skin.
- * Myotome -> Forms skeletal muscles (divided into epaxial and hypaxial muscles).
- * Epaxial muscles (formed from the dorsal part of the myotome) -> Develop into deep back muscles (e.g., longissimus capitis, erector spinae).
- * Hypaxial muscles (formed from the ventral part of the myotome) -> Develop into limb and body wall muscles (e.g., latissimus dorsi, rhomboid major, trapezius, levator scapulae).
- * Since somite loss affects myotome-derived muscles, the epaxial muscles, like longissimus capitis, would be affected. Answer: E

243) Can not be considered as a risk factor for rickets :

- A- Inflammation.
- B- Prematurity.
- C- Neoplasm.
- D- Congenital.
- E- Nutrient.

➤ Explanation:

- A. Inflammation: Chronic inflammation (e.g. celiac disease, IBD) can impair vitamin D absorption.
- B. Prematurity: Premature infants have lower vitamin D and mineral stores.
- C. Correct answer, Neoplasm: Not typically associated with rickets; not a recognized risk factor.
- D. Congenital: Some congenital disorders (like renal tubular defects) can lead to rickets.
- E. Nutrient: Nutritional deficiency (especially vitamin D, calcium, phosphorus) is the most common cause.

244) One of the following is true about succinylcholine :

- A- Causes arrhythmia and hyperkalemia.
- B- Neostigmine is used to reverse it's toxicity.
- C- Atropine is used in malignant hyperthermia.
- D- Has long duration of action.
- E- Affect the impulse transmission from motor nerves.

Explanation:

A. Correct, Causes arrhythmia and hyperkalemia: Succinylcholine can cause potassium release from muscles, leading to hyperkalemia and potentially arrhythmias.

B. Neostigmine is used to reverse it's toxicity: Neostigmine may prolong succinylcholine action by inhibiting its breakdown.

C. Atropine is used in malignant hyperthermia: Dantrolene, not atropine, is the treatment for malignant hyperthermia.

D. Has long duration of action: It has a short duration (about 5-10 minutes).

E. Affect the impulse transmission from motor nerves: It acts at the neuromuscular junction, not on the nerve impulse itself.

245) All of the following statement are true about skeletal muscle relaxant except :

- A- Suggamadex is selective inhibitor to rocuronium.
- B- Botulinum toxin used as adjuvant to general anaesthesia.
- C- Depolarizing neuromuscular agents used for endoscopy.
- D- Diazepam is CNS depressant while dantrolene is hepatotoxic.
- E- Mivacurium is a short acting competitive neuromuscular blocker.

➤ Explanation:

A. Suggamadex is selective inhibitor to rocuronium: It binds rocuronium and reverses its action.

B. Correct answer, Botulinum toxin used as adjuvant to general anaesthesia: Botulinum toxin is used locally for muscle spasticity, not in general anaesthesia.

C. Depolarizing neuromuscular agents used for endoscopy: Succinylcholine is often used for short procedures like endoscopy.

D. Diazepam is CNS depressant while dantrolene is hepatotoxic: Dantrolene can cause liver toxicity with prolonged use.

E. Mivacurium is a short acting competitive neuromuscular blocker: It is a non-depolarizing agent with short duration.

246) Which structure is an elastic fiber :

- A- Posterior longitudinal ligament.
- B- Supraspinous ligament.
- C- Intertransverse ligament.
- D- Ligamentum flavum.
- E- Anterior longitudinal ligament.

➤ *Explanation:*

- A. *Posterior longitudinal ligament: Made mostly of collagen, not elastic fibers.*
- B. *Supraspinous ligament: Composed mainly of collagenous tissue.*
- C. *Intertransverse ligament: Mostly fibrous connective tissue, not elastic.*
- D. *Correct answer, Ligamentum flavum: True; rich in elastic fibers, giving it a yellow color and flexibility.*
- E. *Anterior longitudinal ligament: Made of dense collagen fibers.*

247) A patient with an injury in his face, he lost sensation of skin above the angle of the mandible. The injured nerve is :

- A- *Auriculotemporal nerve.*
- B- *Great auricular nerve.*
- C- *Marginal mandibular nerve.*
- D- *Supraclavicular nerve.*
- E- *Accessory nerve.*

➤ *Explanation:*

- A. *Auriculotemporal nerve: Supplies anterior ear, external auditory meatus, and temporal region, not the area above the mandible angle.*
- B. *Correct answer, Great auricular nerve: Supplies the skin over and around the angle of the mandible, parotid region, and lower part of the auricle.*
- C. *Marginal mandibular nerve: Motor branch of facial nerve; does not provide sensation.*
- D. *Supraclavicular nerve: Supplies skin over clavicle and upper chest, not face.*
- E. *Accessory nerve: Purely motor, innervates SCM and trapezius; no skin sensation.*

248) All of the following contribute in the formation of rectus sheath except :

- A- *External oblique aponeurosis.*
- B- *Internal oblique aponeurosis.*
- C- *Fascia transversalis.*
- D- *Inguinal ligament.*
- E- *5,6,7 costal cartilage.*

➤ *Explanation:*

- A. *External oblique aponeurosis: Contributes to the anterior layer of the rectus sheath.*
- B. *Internal oblique aponeurosis: Contributes to both anterior and posterior layers (depending on level).*
- C. *Fascia transversalis: Contributes to the posterior layer below the arcuate line.*
- D. *Correct answer, Inguinal ligament: Not part of the rectus sheath; it is a thickened band formed from the external oblique aponeurosis but lies inferior to it.*
- E. *5,6,7 costal cartilage: Form the origin of the rectus abdominis muscle, which lies within the sheath*

249) One of the following is wrong about Brown fat :

- A- *It is as electrical blanket.*
- B- *Important for acclimatization to cold.*

- C- It is found in infants but not in adult.
- D- Richly supplied by sympathetic nerve fibers.
- E- Way of heat loss.

➤ *Explanation:*

- A. *It is as electrical blanket: Brown fat generates heat like an "internal heater" via non-shivering thermogenesis.*
- B. *Important for acclimatization to cold: It helps maintain body temperature in cold environments.*
- C. *It is found in infants but not in adult: Brown fat is more abundant in infants, though small amounts may persist in adults.*
- D. *Richly supplied by sympathetic nerve fibers: Sympathetic stimulation activates thermogenesis.*
- E. *Correct answer, Way of heat loss: Incorrect; brown fat generates heat, it does not lose it – it's a mechanism for heat production, not loss.*

250) Regarding insensible respiration, the correct statement is :

- A- Not important in panting animals.
- B- Mechanism of heat gain.
- C- Non evaporative mechanism.
- D- At rest, about 15-25 ml of water are evaporated per hour.
- E- Vaporization of 1 ml of water causes loss of 0.6 C.

➤ *Explanation:*

- A. *Not important in panting animals: Incorrect; it's very important in panting animals for heat dissipation.*
- B. *Mechanism of heat gain: Wrong; insensible respiration is a mechanism of heat loss, not gain.*
- C. *Non evaporative mechanism: Incorrect; it is an evaporative form of heat loss.*
- D. *At rest, about 15-25 ml of water are evaporated per hour: Underestimation; actual evaporation is usually around 300-400 ml/day, so more like 15-20 ml/hour, but still a bit variable.*
- E. *Correct answer, Vaporization of 1 ml of water causes loss of 0.6 C: Correct; this reflects the cooling effect of water evaporation.*

251) Acidosis calcium absorption, while alkalinity calcium absorption, but level of calcium is unchanged.

- A- decrease , increase , bound
- B- increase , decrease , bound
- C- increase , increase , complex
- D- decrease , increase , complex
- E- increase , decrease , complex

➤ *Explanation:*

1. *Acidosis decreases calcium absorption: In the intestines, an acidic environment reduces calcium absorption, partly by impairing vitamin D-dependent transport.*

2. Alkalinity increases calcium absorption: A more alkaline pH can enhance calcium absorption, as it favors better vitamin D activity and calcium solubility in the gut.

3. Bound calcium level remains unchanged: The total bound calcium (to proteins like albumin) doesn't change significantly in the absorption process – it's the ionized calcium levels that vary with pH.

Answer: A

252) When athletes do warm up, which kind of muscle do they use :

A- Isometric.

B- Tetanus.

C- Isotonic.

D- Clonus.

➤ Explanation:

A. Isometric: Muscle contracts without changing length (e.g., wall sit) – not the main type used in warm-up.

B. Tetanus: A sustained muscle contraction due to rapid stimulation – not normal in warm-up; it's a pathological or lab condition.

C. Correct answer, Isotonic: Isotonic muscle contractions involve movement – the muscle changes length while producing force. Warm-up exercises, like jogging, stretching, or light weightlifting, involve isotonic contractions, as the muscles move and generate force. This includes concentric (muscle shortens) and eccentric (muscle lengthens) actions.

D. Clonus: Involuntary, rhythmic muscle contractions – seen in neurological conditions, not during warm-up.

253) Which statement is wrong about tacrolimus :

A- It's a calcineurin inhibitors that inhibit T cells proliferation.

B- No skin atrophy.

C- EDA is concerned about long term use because it lead to skin cancer.

D- Dermatologists are concerned of it.

➤ Explanation:

A. It's a calcineurin inhibitors that inhibit T cells proliferation: Tacrolimus is a calcineurin inhibitor that suppresses T-cell activation, making it effective for inflammatory skin conditions like atopic dermatitis.

B. Correct answer, False statement: While topical tacrolimus is less likely than steroids to cause skin atrophy, it's incorrect to say "no skin atrophy" at all. Though rare, minimal thinning may still occur with long-term use, so this absolute statement is misleading.

C. EDA is concerned about long term use because it lead to skin cancer: The FDA has issued warnings about potential risk of skin cancer and lymphoma with long-term use, though the evidence is not conclusive.

D. Dermatologists are concerned of it: Many dermatologists express caution regarding long-term use due to the FDA warning and prefer short-term or intermittent use.

254) Which one of the following disease characterised by high level of histamine:

- A- Erythema multiforme.
- B- Psoriasis.
- C- Lichen planus.
- D- Urticaria.
- E- Pemphigus vulgaris.

➤ *Explanation:*

- A. Erythema multiforme: Immune-mediated, often triggered by infections or drugs, but not histamine-driven.
- B. Psoriasis: Chronic autoimmune condition with T-cell involvement, not histamine.
- C. Lichen planus: T-cell mediated skin disorder, no significant histamine role.
- D. Correct answer, Urticaria (hives) is characterized by elevated histamine levels, released from mast cells in response to allergens or triggers. Histamine causes vasodilation, increased vascular permeability, and itchy wheals.
- E. Pemphigus vulgaris: Autoimmune blistering disease caused by anti-desmoglein antibodies, not histamine.

255) All of the following are increased risk of fracture except:

- A- Diabetes.
- B- Obesity.
- C- Radiotherapy.
- D- Infection.
- E- Smoking.

➤ *Explanation:*

- A. Diabetes: Increases fracture risk due to poor bone quality and increased fall risk.
- B. Correct answer, Obesity: Though associated with other health issues, mild to moderate obesity may actually be protective against fractures due to increased bone loading. However, severe obesity can still increase fall risk, but generally, it is not a direct risk factor for fractures in most cases.
- C. Radiotherapy: Damages bone tissue and blood supply, weakening bone and increasing fracture risk.
- D. Infection: Chronic bone infections (e.g., osteomyelitis) can weaken bone structure.
- E. Smoking: Reduces bone density and impairs healing, increasing fracture risk.

256) There are two types of sweat gland, the true statement about it is:

- A- Merocrine has adrenergic innervation while apocrine has cholinergic innervation.
- B- Apocrine ducts open in skin surface.
- C- Both have two types of secretory cells.
- D- Apocrine is truly merocrine in mechanism of secretion.
- E- Merocrine secretion is viscous and odorless.

➤ *Explanation:*

- A. (eccrine) glands have cholinergic innervation, while apocrine glands have adrenergic innervation (opposite of what's stated).
- B. Apocrine ducts do not open on the skin surface, but into hair follicles.

- C- Only merocrine glands clearly have two secretory cell types (dark and clear cells); apocrine glands do not.
- D- Correct answer, Apocrine is truly merocrine in mechanism of secretion: Despite the name, apocrine glands actually use a merocrine secretion mechanism (exocytosis), not true apocrine shedding.
- E- Merocrine secretion is viscous and odorless: Merocrine sweat is watery and odorless, not viscous.

257) Content of the Carotid sheath, except:

- A. Internal carotid artery
- B. Common carotid artery
- C. Vagus nerve
- D. Internal jugular vein
- E. Sympathetic trunk (chain)

➤ *Explanation:*

- A. Internal carotid artery: Yes, in the upper part of the sheath (after bifurcation).
- B. Common carotid artery: Yes, in the lower part of the sheath.
- C. Vagus nerve: Yes, lies between the artery and vein.
- D. Internal jugular vein: Yes, lateral to the artery.
- E. Correct answer, Sympathetic trunk (chain): NOT inside the carotid sheath. It lies posterior to the sheath, embedded in the prevertebral fascia.

258) These symptoms (cough, coryza, conjunctivitis) are with which of the following:

- A. Rubeola
- B. Roseola
- C. Rubella
- D. HSV-6
- E. Varicella-zoster virus

➤ *Explanation:*

- A. Correct answer, Rubeola: The classic prodrome of measles (Rubeola) includes the three C's: Cough, Coryza (runny nose), Conjunctivitis. These are usually followed by Koplik spots and then the maculopapular rash that spreads from the face downward.
- B. Roseola: High fever followed by rash, no 3 C's.
- C. Rubella: Milder symptoms, often with posterior auricular lymphadenopathy, not the 3 C's.
- D. HSV-6: Same as Roseola; sudden rash after fever, no cough/coryza/conjunctivitis.
- E. Varicella-zoster virus: Causes chickenpox; starts with fever and rash, but not the 3 C's.

259) The drug of choice of cutaneous larva migrans is:

- A. Albendazole
- B. Thiabendazole
- C. Ivermectin
- D. Mebendazole
- E. Pentostam

➤ *Explanation:*

- A. Albendazole: Effective alternative, especially in multiple-day regimens.
- B. Thiabendazole: Older option, can be used topically or orally, but has more side effects.
- C. Correct answer, Ivermectin: Drug of choice due to its high effectiveness and convenient dosing (often a single dose).
- D. Mebendazole: Less effective against migrating larvae.
- E. Pentostam: Used for leishmaniasis, not CLM.

260) The MELANIN Stain found in all of these; except :

- A. Skin
- B. Hair
- C. Iris
- D. Spinal cord
- E. Brain stem

➤ Explanation:

- A. Skin: Melanocytes in the basal layer of the epidermis produce melanin.
- B. Hair: Melanin gives hair its color.
- C. Iris: Melanin determines eye color.
- D. Correct answer, Spinal cord: Does not normally contain melanin. It lacks pigmented neurons like those found in the brainstem.
- E. Brain stem: Specifically in areas like the substantia nigra, which appears dark due to neuromelanin.

261) Infratemporal surface of greater wing of sphenoid gives attachment to:

- A. Superficial head of medial pterygoid muscle
- B. Deep head of medial pterygoid muscle
- C. Upper head of lateral pterygoid muscle
- D. Lower head of lateral pterygoid muscle

➤ Explanation:

- A. Superficial head of medial pterygoid muscle originates mainly from the maxillary tuberosity.
- B. Deep head of medial pterygoid muscle originate from pterygoid fossa of the sphenoid bone, not the greater wing.
- C. Correct answer, Upper head of lateral pterygoid muscle: This muscle originates from this surface and inserts into the temporomandibular joint (TMJ) capsule and neck of the mandible.
- D. Lower head of lateral pterygoid muscle: Originates from the lateral surface of the lateral pterygoid plate, not the greater wing.

262) Patient comes to hospital with thrombocytopenic purpura history. He complains from almost every day headache with dull feeling, and this headache begins afternoon and persists till sleeping. A drug to control headache is prescribed to the patient, what is it?

- A) Paracetamol
- B) Meloxicam

- C) Ibuprofen
- D) Naproxen
- E) Aspirin

➤ *Explanation:*

A. *Paracetamol is correct: It is an analgesic and antipyretic. It does not affect platelet function. It is safe for patients with thrombocytopenia.*

Other options: NSAIDs (Meloxicam, Ibuprofen, Naproxen, Aspirin): The patient has a history of thrombocytopenic purpura, which means low platelet count and an increased risk of bleeding. Therefore, NSAIDs like ibuprofen, naproxen, meloxicam, and especially aspirin should be avoided because: They inhibit platelet function (especially aspirin irreversibly). They increase bleeding risk, which is dangerous in thrombocytopenic patients.

263) 7 years girl goes to hospital and proceeds a vaginal grape like tumor excission. A pathologist reveals that this tumor is:

- A) dedifferentiated rhabdomyosarcoma
- B) embryonal rhabdomyosarcoma
- C) Botryoids rhabdomyosarcoma
- D) uterine leiomyosarcoma
- E) pleomorphic rhabdomyosarcoma

➤ *Explanation:*

A. *dedifferentiated rhabdomyosarcoma: Rare and usually in adults.*

B. *embryonal rhabdomyosarcoma: Botryoid is a subtype, but the specific term fits better here.*

C. *Correct answer, Botryoids rhabdomyosarcoma: Botryoid rhabdomyosarcoma is a subtype of embryonal rhabdomyosarcoma that commonly presents in young girls, usually under 8 years old, as a grape-like (botryoid) mass protruding from the vagina.*

D. *uterine leiomyosarcoma: Occurs in adults, not 7-year-old girls.*

E. *pleomorphic rhabdomyosarcoma: Seen in older adults, not children.*

264) Can not be considered as a risk factor for rickets:

- A) Inflammation
- B) Prematurity
- C) Neoplasm
- D) Congenital
- E) Nutrient

➤ *Explanation:*

A. *Correct answer, Inflammation: Rickets is a disorder of impaired bone mineralization in children, primarily due to vitamin D deficiency, calcium/phosphate imbalance, or genetic causes. (Inflammation is not a standard risk factor).*

B. *Prematurity: Premature infants miss the critical third-trimester mineral transfer from mother -> high risk.*

C. Neoplasm: Certain tumors (e.g., leukemia, neuroblastoma) can interfere with calcium/phosphate metabolism.

D. Congenital: Genetic disorders (like X-linked hypophosphatemic rickets) are congenital causes.

E. Nutrient: Vitamin D, calcium, and phosphate deficiencies are the most common causes.

265) mesenchymal cells gives all the following cells except:

- A) Osteoclast
- B) osteoblast
- C) chondroblast
- D) chondrocyte
- E) Adipocyte

➤ *Explanation:*

- A. Correct answer, false statement, Osteoclast: Derived from hematopoietic stem cells, not mesenchymal.
- B. osteoblast: Formed from mesenchymal cells; build bone.
- C. chondroblast: Mesenchymal origin; produce cartilage matrix.
- D. chondrocyte: Mature cartilage cell derived from chondroblast; mesenchymal origin.
- E. Adipocyte: Fat-storing cell derived from mesenchymal stem cells.

266) Not related to collagen diseases:

- A) Nutritional deficiency
- B) Secretion
- C) Post translational modifications
- D) post transcriptional modifications

➤ *Explanation:*

- A. Nutritional deficiency: Related: Vitamin C deficiency (scurvy) impairs collagen synthesis by affecting hydroxylation of proline/lysine.
- B. Secretion: Related: Collagen must be secreted from fibroblasts to the extracellular space for proper fiber formation. Defects can cause disease.
- C. Post translational modifications: Related: Critical for collagen stability—includes hydroxylation, glycosylation, and cross-linking. Mutations affecting these lead to disorders like Ehlers-Danlos syndrome.
- D. Correct answer, post transcriptional modifications: Not related: These involve RNA processing (like splicing or polyadenylation), not directly involved in collagen synthesis pathways

267) surgery of thyroid with anesthesia leads to tachypnea and hyperthermia as complication:

- A) Suxamethonium
- B) Meloxicam
- C) gallamine
- D) pancornium
- E) D-tubocurarine

➤ *Explanation:*

- A. Correct answer, *Suxamethonium*: Can cause malignant hyperthermia leading to tachypnea and hyperthermia during anesthesia.
- B. *Meloxicam*: A nonsteroidal anti-inflammatory drug (NSAID), not related to muscle relaxation or hyperthermia.
- C. *Gallamine*: A non-depolarizing muscle relaxant, rarely associated with malignant hyperthermia.
- D. *Pancornium*: Non-depolarizing muscle relaxant, not typically causing malignant hyperthermia.
- E. *D-tubocurarine*: Older non-depolarizing neuromuscular blocker, not linked to malignant hyperthermia.

268) Which of these bones is not paired:

- A) Maxilla
- B) Lacrimal
- C) Nasal
- D) Sphenoid
- E) Zygomatic

Explanation:

- * Maxilla, Lacrimal, Nasal, and Zygomatic bones: are paired (one on each side of the face).
- * The Sphenoid bone: is a single, unpaired bone located at the base of the skull.
- * Answer: D

269) Which of these structures is attached to the posterior end of mylohyoid line:

- A) Sphenomandibular ligament
- B) Tempromandibular ligament
- C) Stylomandibular ligament
- D) Pterygomandibular ligament

➤ *Explanation:*

- A. *Sphenomandibular ligament*: Attaches from the spine of the sphenoid bone to the lingula of the mandible (near the mandibular foramen), not the mylohyoid line.
- B. *Tempromandibular ligament*: Attaches from the articular tubercle of the temporal bone to the neck of the mandible.
- C. *Stylomandibular ligament*: Runs from the styloid process to the angle of the mandible.
- D. Correct answer, *Pterygomandibular ligament*: A tendinous band connecting the pterygoid hamulus of the sphenoid bone to the mylohyoid line of the mandible, so it does attach at the posterior end of the mylohyoid line.

270) The least of the following can metastases to bone?

- A) colon cancer
- B) breast cancer
- C) kidney cancer
- D) lung cancer
- E) prostate cancer

➤ *Explanation:*

A. *Correct answer, Colon cancer: less frequently spreads to bone compared to these others, making it the least common among the options for bone metastasis.*

* *Other options: Breast, prostate, lung, and kidney cancers: commonly metastasize to bone.*

271) Tumor that grossly resembles normal bone and associated with GARDNER SYNDROM:

- A) Ewing's sarcoma
- B) Osteoma
- C) Chondrosarcoma
- D) Osteochondroma

➤ *Explanation:*

A. *Ewing's sarcoma: A malignant small round blue cell tumor that usually affects long bones and pelvis in children. Not associated with Gardner syndrome.*

B. *Correct answer, Osteoma: A benign tumor that resembles mature, compact bone. Commonly found in the skull and facial bones. Associated with Gardner syndrome, where multiple osteomas are a diagnostic feature.*

C. *Chondrosarcoma: A malignant tumor of cartilage-producing cells, typically in adults. Not grossly similar to normal bone and not associated with Gardner syndrome.*

D. *Osteochondroma: A benign bone tumor with a cartilage cap, often found near growth plates. Not linked with Gardner syndrome.*

272) A 3 boy patient has had fever and cough with coryza and conjunctivitis, after a while a rash begins from hair line spreading through out the trunk and body, the best diagnosis is:

- A) Roseola
- B) German Measles
- C) Rubeola
- D) Slapped cheek
- E) Chicken pox

➤ *Explanation:*

A. *Roseola: sudden high fever followed by rash as fever resolves, rash starts on trunk not hairline.*

B. *Grman measles: rash starts on face but milder symptoms, less prominent cough/conjunctivitis.*

C. *Correct answer, Rubeola (Measles): classically presents with the 3 C's: Cough, Coryza (runny nose), Conjunctivitis. Followed by a maculopapular rash that starts at the hairline and spreads downwards over the trunk and body. Also may have Koplik spots inside the mouth before rash.*

D. *Slapped cheek: erythema on cheeks, no conjunctivitis or cough.*

E. *Chicken pox: vesicular rash, not maculopapular, starts on trunk but with vesicles.*

273) What is the difference between Eumycetoma and Actinomycetoma:

- A) Eumycetoma's granules are usually yellow
- B) Actinomycetoma's granules are usually black
- C) There is no difference

- D) Eumycetoma is caused by bacteria, and Actinomycetoma is caused by fungi
E) Eumycetoma is caused by gram-negative organism, and Actinomycetoma is caused by gram positive organism

➤ *Explanation:*

- A. *Correct answer, Granules: Eumycetoma (fungal infection) usually produces black or yellow granules.*
B. *Actinomycetoma (bacterial infection) typically has white, yellow, or red granules, not black.*
D. *Cause: This is reversed: Eumycetoma is caused by fungi; Actinomycetoma is caused by bacteria.*
E. *Eumycetoma is fungal (not classified as gram-positive or gram-negative bacteria), while Actinomycetoma is caused by gram-positive bacteria (actinomycetes).*

274) TNF-alpha receptor blocker drug :

- A) Etanercept
B) Anakinra
C) Methotrexate
D) Leflunomide
E) Sulfasalazine

➤ *Explanation:*

- A. *Correct, Etanercept: A TNF-\alpha receptor blocker; it acts as a decoy receptor to bind TNF-\alpha and prevent its inflammatory effects.*
B. *Anakinra: IL-1 receptor antagonist, not a TNF-\alpha blocker.*
C. *Methotrexate: A folate antagonist; immunosuppressive but not a TNF-\alpha blocker.*
D. *Leflunomide: inhibits pyrimidine synthesis and T-cell proliferation; not a TNF-\alpha blocker.*
E. *Sulfasalazine: Anti-inflammatory used in RA and IBD; does not block TNF-\alpha directly.*

275) The topical steroid that used for treatment of psoriasis in face and skin folds or Safe drug on the face :

- A) Hydrocortison
B) Flucinonide
C) Amcinonide
D) Halcinonide
E) Triamcinolon

➤ *Explanation:*

- A. *Correct answer, Hydrocortison: Low-potency steroid, safe for delicate areas like the face, skin folds, and genitals; commonly used for psoriasis in these areas.*
B. *Flucinonide: High-potency steroid, not safe for long-term use on the face due to risk of skin thinning.*
C. *Amcinonide: High-potency steroid, not recommended for thin-skinned areas.*
D. *Halcinonide: High-potency steroid, can cause atrophy if used on face or folds.*
E. *Triamcinolon: Medium to high potency, generally avoided on face and skin folds for long durations.*

276) One of these is an Intermediate muscle of extrinsic back layer:

- A) Longissimus capitis
- B) Serratus posterior superior
- C) Trapezius
- D) Latissimus dorsi
- E) Levator scapulae

➤ *Explanation:*

- A. *Longissimus capitis: Intrinsic (deep) back muscle, part of the erector spinae group, not extrinsic.*
- B. *Correct answer, Serratus posterior superior: Intermediate muscle of the extrinsic back muscles, involved in respiration (elevates ribs).*
- C. *Trapezius: Superficial extrinsic back muscle, not intermediate.*
- D. *Latissimus dorsi: Also a superficial extrinsic back muscle.*
- E. *Levator scapulae: Another superficial extrinsic back muscle, assists in scapular elevation.*

277) The specific test for SCARLET FEVER :

- A) Shultz-Charlton
- B) Bachman test
- C) Montenegro test
- D) Germ tube test

➤ *Explanation:*

- A. *Correct answer, Shultz-Charlton: Specific test for Scarlet Fever. Involves intradermal injection of antitoxin into the rash area; blanching of the rash confirms scarlet fever.*
- B. *Bachman test: Similar in principle to the Shultz-Charlton test but less commonly used and less specific.*
- C. *Montenegro test: Used for Leishmaniasis (intradermal skin test).*
- D. *Germ tube test: Used to identify Candida albicans (fungal infection), not related to scarlet fever.*

278) Type of cartilage in epiglottis :

- A) Elastic cartilage
- B) Fibro cartilage
- C) Hyaline cartilage

➤ *Explanation:*

- A. *Correct answer, Elastic cartilage: Epiglottis is made of elastic cartilage, which gives it flexibility and resilience—important for its function in covering the trachea during swallowing.*
- B. *Fibro cartilage: Found in intervertebral discs and pubic symphysis—very strong and resistant to compression, not flexible.*
- C. *Hyaline cartilage: Found in the trachea, nose, and articular surfaces of bones—smooth and glassy, but less flexible than elastic cartilage.*

279) All of the following are ways to treatment of hyperhidrosis, except :

- A) Topical agents

- B) Iontophoresis
- C) parasympathctomy
- D) Botulinum toxin
- E) Sweat gland resection

➤ *Explanation:*

- A. *Topical agents: aluminum chloride; first-line for mild cases.*
- B. *Iontophoresis: effective for palmar/plantar hyperhidrosis.*
- C. *True, parasympathctomy: incorrect, as it's not relevant to sweat gland control.*
- D. *Botulinum toxin: inhibits acetylcholine release; very effective for focal hyperhidrosis.*
- E. *Sweat gland resection: surgical option for severe, localized cases.*

280) Talipes valgus:

- A) permanent plantar flexion, walking is done on toes without touching the heel to ground .
- B) permanent dorsiflexion, the heel rests on the ground and the toes pointed upwards .
- C) the sole of the foot inclined outward so that walking is done on the medial side of the foot .
- D) the sole of the foot inclined inward so that walking is done on the lateral side of the foot .

➤ *Explanation:*

* *Talipes refers to: deformities of the foot involving the ankle (talus) and foot (pes).*

* *Valgus means the distal part of the limb is angled outward (laterally).*

A: *plantar flexion; walking on toes.*

B: *dorsiflexion; walking on heel.*

C: *Correct answer, eversion of the foot; sole turns outward, so patient walks on medial side.*

D: *inversion; sole turns inward, walking on lateral side.*

281) The origin of the greater wing of sphenoid is:

- A) Ala orbitalis
- B) Ala temporalis
- C) Trabecula cranii cartilage
- D) Hypophyseal cartilage
- E) Parachordal cartilage

➤ *Explanation:*

* *The greater wing of the sphenoid bone: originates from the ala temporalis, which is part of the cartilaginous neurocranium during embryological development.*

A. *Ala orbitalis: gives rise to the lesser wing of the sphenoid.*

B. *Correct answer, Ala temporalis: gives rise to the greater wing of the sphenoid.*

C. *Trabecula cranii cartilage: forms part of the ethmoid and anterior cranial base.*

D. *Hypophyseal cartilage: contributes to the formation of the body of the sphenoid.*

E. *Parachordal cartilage: gives rise to the basilar part of the occipital bone.*

282) The drug that inhibit dihydrofolate reductase is:

- A) Entracept
- B) Sulfasalazine
- C) Leflunomide
- D) Methotrexate
- E) Hydroxychloroquine

➤ Explanation:

- A. Entracept: A TNF- α receptor blocker, used in autoimmune diseases like rheumatoid arthritis.
- B. Sulfasalazine: An anti-inflammatory and immunomodulatory drug, not a DHFR inhibitor.
- C. Leflunomide: inhibits dihydroorotate dehydrogenase, affecting pyrimidine synthesis, not folate metabolism.
- D. Correct answer, Methotrexate: dihydrofolate reductase (DHFR), preventing the conversion of dihydrofolate to tetrahydrofolate, interfering with DNA synthesis.
- E. Hydroxychloroquine: An antimalarial and immunomodulatory drug, works by inhibiting antigen processing, not folate metabolism.

283) All of the following are contents of anterior abdominal wall, except:

- A) Transversalis fascia
- B) Deep fascia
- C) Transversus abdominis

➤ Explanation:

* Option A/C: * Anterior abdominal wall layers (superficial to deep):

1. Skin
2. Superficial fascia (Camper's and Scarpa's fascia),
3. Muscles (External oblique, Internal oblique, Transversus abdominis (So Option C is included)),
4. Transversalis fascia (So Option A is included)
5. Extraperitoneal fat
6. Parietal peritoneum.

*Option (B): Correct answer-False statement, Deep fascia: is not a distinct named layer in the anterior abdominal wall like in limbs. Instead, the muscles are surrounded by their own investing fascia, but we don't typically refer to a single "deep fascia" of the abdominal wall.

284) What is the diagnostic stage for TRICHENELLA SPIRALIS:

- A) Encysted larvae in muscle
- B) Filariform larvae
- C) Promastigote
- D) Amastigote

➤ Explanation:

- A. Correct answer, Encysted larvae in muscle: *Trichinella spiralis* is a parasitic roundworm responsible for trichinosis, typically acquired by eating undercooked meat (especially pork) containing the encysted larvae. Encysted larvae in muscle biopsy, which is the diagnostic method in suspected cases.
- B. Filariform larvae: Found in *Strongyloides stercoralis*, not *Trichinella*.
- C. Promastigote: Seen in *Leishmania* in the vector (sandfly).

D. Amastigote: Also related to *Leishmania*, seen inside host macrophages.

285) The most important characteristic of the emissary vein:

- A) Connects the outside of the skull to the inside
- B) Valveless

➤ Explanation:

A. connects the outside of the skull to the inside: While option a (connects the outside of the skull to the inside) is true, it's not as clinically important as the fact that they're valveless, which is why option b is the better answer.

B. Accurate answer, valveless: The most important characteristic of emissary veins is that they are valveless, which allows bidirectional flow of blood. This means infections from the outside of the skull (like from the scalp or face) can travel inward to intracranial venous sinuses, potentially leading to serious infections like meningitis or cavernous sinus thrombosis.

286) Tender, swollen, and filled with pus with only one draining point:

- A) boil
- B) furuncle
- C) carbuncle
- D) folliculitis

➤ Explanation:

A. boil: is a lay term that commonly refers to a furuncle.

B. Correct answer, furuncle: A tender, swollen, pus-filled infection of a single hair follicle, typically with one central draining point.

C. carbuncle: A deeper, more extensive infection involving multiple hair follicles, with multiple draining sinuses.

D. folliculitis: A superficial infection of the hair follicle. It presents as small, red, and often itchy pustules—not typically swollen or deeply tender.

287) To view the posterior aspect of the spinal cord, which structures have to be removed?

- A) pedicle and transverse processes
- B) Spinous process, pedicle and laminae
- C) Laminae, Spinous process
- D) spinous process, ligamentum flavum and laminae

➤ Explanation:

* To access the posterior aspect of the spinal cord, a surgeon must remove:

1. Spinous process: The bony projections you can feel along your back.

2. Laminae: The flat parts of the vertebrae that form the "roof" over the spinal canal.

3. Ligamentum flavum: A tough ligament that connects the laminae of adjacent vertebrae and also contributes to the posterior wall of the spinal canal.

* This procedure is typically called a laminectomy and is performed to decompress the spinal cord or nerves.

* Answer: D

288) All of the following about Quadratus Lumborum are correct, except:

- A) It attaches to the transverse processes of all lumbar vertebrae
- B) is innervated by T12 spinal nerve
- C) Bilateral action leads to extension of trunk

➤ Explanation:

- A. Correct answer—False statement: it attaches to L1-L4, not all lumbar vertebrae.
- B. is innervated by T12 spinal nerve: Correct; innervated by T12 and L1-L4.
- C. Bilateral action leads to extension of trunk: Correct; both sides contracting extends the lumbar spine.

289) Which of these skin layers is only found in thick skin:

- A) Stratum corneum
- B) Stratum basale
- C) Stratum spinosum
- D) Stratum lucidum

➤ Explanation:

- A/B/C: The layers (corneum, basale, spinosum): are found in both thick and thin skin.
- D. Correct answer, Stratum lucidum: Stratum lucidum is a thin, translucent layer only found in thick skin, such as the palms of the hands and soles of the feet.

290) Cartilage is:

- A) has typical vascularity
- B) avascular
- C) has low vascularity
- D) with excessive vascularity

➤ Explanation:

- A. Cartilage does not have typical (normal) vascularity; it lacks blood vessels entirely.
- B. Correct answer, Cartilage is avascular; it relies on diffusion for nutrient and waste exchange.
- C. While this may sound reasonable, it's misleading. Cartilage has no blood vessels at all, not just "low" vascularity.
- D. This is the opposite of true. Cartilage is one of the least vascular tissues in the body.

291) What is the drug of choice for treating malignant hyperthermia?

- A) Succinylcholine
- B) Pancuronium
- C) Diazepam
- D) Dantrolene
- E) Vecuronium

➤ Explanation:

A. Succinylcholine: This is a depolarizing neuromuscular blocker. It is actually a triggering agent that can induce an MH crisis in genetically susceptible individuals. It should never be used to treat it.

B. Pancuronium & E. Vecuronium: These are non-depolarizing neuromuscular blockers. While they are safe to use in patients prone to MH, they do not treat the intracellular calcium release process that defines the condition.

C. Diazepam: A benzodiazepine used for sedation and anxiety. It has no effect on the calcium channels within the muscle fiber and therefore has no role in treating MH.

D. Dantrolene (Correct answer): It acts as a postsynaptic muscle relaxant. Specifically, it binds to the Ryanodine Receptor 1 (RyR1) on the sarcoplasmic reticulum of skeletal muscle cells. This binding inhibits the massive release of calcium (Ca^{2+}) into the cytosol, which is the underlying cause of the life-threatening muscle rigidity and hypermetabolic state in Malignant Hyperthermia (MH).

292) which of the following is wrong about buccinator?

- A) stronger in infants than in adults
- B) pierced by buccal branch of facial nerve
- C) prevents dripping of saliva
- D) roofed by facial nerve

➤ Explanation:

A. Buccinator is well-developed in infants to help with sucking during breastfeeding.

B. The buccal branch of the facial nerve does not pierce the buccinator; it runs on its outer surface. It is the buccal branch of the mandibular nerve (CN V3) that pierces the buccinator to provide sensory innervation to the inner cheek.

C. prevents dripping of saliva: Buccinator presses the cheek against the teeth, preventing food and saliva from escaping.

D. roofed by facial nerve: The term "roofed by" is anatomically incorrect. The facial nerve does not form a roof over the buccinator. It innervates the muscle by traveling superficially, but it's not considered a "roof."

* Answer: B/D

293) Which enzyme catalyzes the conversion of tyrosine to DOPA?

- A) Dopamine \beta-hydroxylase
- B) DOPA decarboxylase
- C) Tyrosine hydroxylase
- D) Phenylalanine hydroxylase
- E) Monoamine oxidase

➤ Explanation:

A. Dopamine \beta-hydroxylase: This enzyme functions later in the pathway, converting Dopamine into Norepinephrine within the synaptic vesicles.

B. DOPA decarboxylase: Also known as aromatic L-amino acid decarboxylase, it converts L-DOPA into Dopamine by removing a carboxyl group.

This reaction is the rate-limiting step in the biosynthesis of catecholamines (Dopamine, Norepinephrine, and Epinephrine).

C. Tyrosine hydroxylase (Correct answer): This enzyme adds a hydroxyl group to the amino acid L-Tyrosine to form L-DOPA (L-3,4-dihydroxyphenylalanine). It requires tetrahydrobiopterin (BH₄) as a cofactor.

D. Phenylalanine hydroxylase: This enzyme converts the essential amino acid Phenylalanine into Tyrosine. A deficiency in this enzyme leads to Phenylketonuria (PKU).

E. Monoamine oxidase (MAO): This is an enzyme involved in the degradation (breakdown) of catecholamines and serotonin, not their synthesis.

294) what is correct about vertebral column ligaments and their extensions?

A) anterior longitudinal ligament begins from axis toward sacrum

B) posterior longitudinal ligament begins from axis toward sacrum

C) supraspinous ligament begins from axis toward sacrum

➤ Explanation:

A. The anterior longitudinal ligament actually extends from the base of the skull (occiput), not just from the axis, down to the sacrum.

B. Correct, The posterior longitudinal ligament does indeed extend from the body of the axis (C2) to the sacrum, lying on the posterior aspect of the vertebral bodies, inside the vertebral canal.

C. The supraspinous ligament actually extends from C7 to the sacrum. Above C7, it continues as the ligamentum nuchae, not as the supraspinous ligament.

295) relations to scalenus anterior:

A) both subclavian artery and vein are found posteriorly to muscle

B) both subclavian artery and vein are found anteriorly to muscle

C) subclavian artery is anterior to the muscle, while subclavian vein is posterior

D) the muscle intersects the subclavian artery from vein

➤ Explanation:

➤ The scalenus anterior muscle has important anatomical relationships:

* Subclavian vein lies anterior to the scalenus anterior.

* Subclavian artery lies posterior to the scalenus anterior.

* Therefore, scalenus anterior lies between the subclavian vein (anteriorly) and the subclavian artery (posteriorly)—it separates or intersects them.

* Answer: D

296) Muscle fibers type for bicycle race:

A) White

B) Red

➤ Explanation:

A. white fibers (Type II or fast-twitch): are used for short bursts of strength or speed but fatigue quickly—more typical in sprinting, not endurance racing.

B. Correct answer, Red muscle fibers (also known as Type I fibers or slow-twitch fibers) are:

* Rich in mitochondria, myoglobin, and capillaries

- * Specialized for aerobic metabolism
- * Fatigue-resistant
- * Suited for endurance activities like long-distance cycling

297) staphylococcus that cause SSSS produce :

- A) TSST-1
- B) protein A
- C) exfoliatins

➤ Explanation:

- A. TSST-1: Toxic Shock Syndrome Toxin-1 – associated with toxic shock syndrome, not SSSS.
- B. protein A: Binds IgG and interferes with opsonization and phagocytosis – important in immune evasion, but not the cause of SSSS.
- C. Correct answer: exfoliatins, Staphylococcal Scalded Skin Syndrome (SSSS) is caused by certain strains of *Staphylococcus aureus* that produce exfoliative toxins, also known as exfoliatins (Exfoliatin A and B). These toxins cleave desmoglein-1, a cadherin in the skin, leading to the separation of the epidermis and causing the characteristic skin peeling of SSSS.

298) rheumatic disorders defined more as:

- A) acute
- B) systematic
- C) pain in joints

➤ Explanation:

- A. Some rheumatic diseases can be acute, but many are chronic.
- B. Correct answer, Rheumatic disorders often involve systemic inflammation that affects multiple tissues and organs, not just the joints. While joint pain is a common symptom, rheumatic diseases like rheumatoid arthritis, systemic lupus erythematosus, and others typically have widespread effects beyond acute joint pain.
- C. Joint pain is a symptom, but rheumatic disorders are defined by more than just pain—they involve systemic inflammation and immune dysregulation.

299) a patient has developed a superficial dark pigmentation on her right shoulder, which is recurrent after terminating the medication. What is the most likely diagnosis?

- A) ring worm
- B) candidiasis
- C) mycetoma
- D) tinea versicolor

➤ Explanation:

- A. ring worm: causes scaly, red, circular patches, not usually pigmentation changes.
- B. candidiasis: causes moist, erythematous lesions, often in folds, not pigmentation.
- C. mycetoma: is a chronic granulomatous infection with swelling and draining sinuses, not just pigmentation.

D. Correct answer, *Tinea versicolor* is a superficial fungal infection caused by *Malassezia* yeast, leading to recurrent dark or light pigmented patches on the skin, especially on the trunk and shoulders, which often reappear after stopping treatment.

300) Heat Stroke include all the following, except:

Cold skin

➤ Explanation:

Correct Answer: Cold skin

Heat stroke is a life-threatening condition where the body's thermoregulatory mechanisms fail completely, leading to a rapid rise in core body temperature. One of its cardinal clinical signs is hot and dry skin because the sweating mechanism (evaporative cooling) shuts down. Therefore, "Cold skin" is the opposite of what occurs during a heat stroke and is the correct "except" choice.

301) Which of the following correct about cavity of shoulder joint:

* Communicate with subscapular bursae

➤ Explanation:

Correct Answer: Communicate with subscapular bursae

The glenohumeral (shoulder) joint capsule has a specific opening that allows the synovial cavity to be continuous with the subscapular bursa. This anatomical communication is essential as it lies between the subscapularis tendon and the neck of the scapula, reducing friction during joint movements.

302) Most contagious disease:

A- Measles

B- Rubella

C- None

➤ Explanation:

Correct Answer: A. Measles (*Rubeola*)

Measles (*Rubeola*) is recognized as one of the most highly contagious viral infections. It is characterized by the "3 C's" (Cough, Coryza, and Conjunctivitis). It spreads via respiratory droplets and can remain infectious in the air for extended periods, making it significantly more transmissible than Rubella.

303) correct about Civatte:

lichen planus

➤ Explanation:

Correct Answer: Lichen planus

Civatte bodies (also known as cytoid or colloid bodies) represent necrotic or apoptotic basal keratinocytes. They are a classic histopathological hallmark of Lichen planus, an inflammatory skin disorder mediated by T-cells (specifically CD8+ cells) that attack the basal layer of the epidermis.

304) Which of the following did NOT happen with myasthenia gravis :

symptoms improvement with repeated stimulation

➤ *Explanation:*

Correct Answer: Symptoms improvement with repeated stimulation

Myasthenia Gravis is an autoimmune disorder where antibodies block acetylcholine receptors at the neuromuscular junction. A defining clinical feature is muscle fatigability, where weakness worsens with activity/repeated stimulation and improves with rest. Improvement with repeated stimulation is actually a characteristic of Lambert-Eaton Myasthenic Syndrome, not Myasthenia Gravis.

305) Large pump has been identified for 5-7 days, painful, multiple discharging sinus, healed with a scar:

- A. Furuncle
- B. Carbuncle

➤ *Explanation:*

Correct Answer: Carbuncle

A carbuncle is a deep, painful cluster of interconnected furuncles (boils) that involves multiple hair follicles. It is characterized by multiple drainage points (sinuses) and systemic symptoms like fever. Because the infection is deep and causes extensive tissue destruction, it typically heals with a permanent scar.

306) HSV type 2 is characterized by:

Ulcers on genital organs

➤ *Explanation:*

Correct Answer: Ulcers on genital organs

Herpes Simplex Virus Type 2 (HSV-2) is the primary cause of genital herpes. It manifests as painful vesicles that rupture to form shallow, tender ulcers on the genitalia. While HSV-1 can also cause genital lesions, HSV-2 is classically associated with the genital region.

307) Which of the following drug isn't used for the treatment of acne:

Neomycin

➤ *Explanation:*

Correct Answer: Neomycin

Acne treatment involves keratolytics, benzoyl peroxide, and specific antibiotics like Clindamycin or Doxycycline that target Cutibacterium acnes. Neomycin is an aminoglycoside antibiotic commonly used in topical ointments for superficial skin infections (like cuts or abrasions), but it is not effective for acne and is not part of standard acne therapy.

308) All are Tyrosinase inhibitors except:

- A) Arbutin
- B) Kojic acid
- C) Vitamin E
- D) Vitamin A
- E) Hydroquinone

➤ *Explanation:*

Correct Answer: D) Vitamin A

(Note: Vitamin E is often also categorized as an antioxidant rather than a direct inhibitor, but Vitamin A is primarily for cell turnover).

* Tyrosinase inhibitors work by blocking the rate-limiting enzyme in melanin production. Hydroquinone, Arbutin, and Kojic acid are direct inhibitors. Vitamin A (Retinoids) primarily treats pigmentation by increasing skin cell turnover and shedding melanin-containing cells rather than directly inhibiting the tyrosinase enzyme.

309) Alport Syndrome molecular basis:

- A) Col4A1, Col1A2
- B) Col4A1, Col1A5
- C) Col4A1, Col6A1
- D) COL4A3, COL4A1
- E) COL4A5, COL6A1

➤ Explanation:

Correct Answer: D. COL4A3, COL4A1 (Most accurate in the context of Type IV collagen mutations).

Alport Syndrome is caused by mutations in genes encoding the alpha chains of Type IV collagen, which is a major component of basement membranes. The most common mutations involve COL4A3, COL4A4, and COL4A5. These mutations lead to defective basement membranes in the kidneys, ears, and eyes.

310) What connects the periosteum with the compact part of bone?

- A. Haversian canal
- B. Lacunae
- C. Canaliculi
- D. Volkman canals
- E. Sharpey fibers

➤ Explanation:

Correct Answer: E. Sharpey's fibers

* Sharpey's fibers (perforating fibers) are bundles of collagenous fibers that extend from the periosteum into the bone matrix. They act like "nails" to firmly anchor the periosteum and attached tendons or ligaments to the underlying compact bone.

311) Which muscle does not have an attachment to the third cervical vertebra (C3)?

- A. Scalenus anterior
- B. Scalenus medius
- C. Longus capitis
- D. Longus colli
- E. Superior oblique

➤ Explanation:

Correct Answer: E. Superior oblique

* *Superior oblique*: In the context of neck anatomy, the *Obliquus capitis superior* muscle extends between the atlas (C1) and the occipital bone; it does not attach to C3. If referring to the eye muscle, it is located within the orbit.

* *Options A, B, C, & D*: These are deep cervical muscles. The *Scalene* muscles and *Longus* muscles (*capitis* and *colli*) attach to the transverse processes of various cervical vertebrae, including C3.

312) Which of the following is true regarding the seventh cervical vertebra (C7)?

- A. The scalenus minimus arises from its transverse process.
- B. The scalenus minimus arises from its spine.
- C. It has a bifid spine.
- D. It is a Typical cervical

➤ *Explanation*:

Correct Answer: A. The scalenus minimus arises from its transverse process.

* *Scalenus minimus*: This is a variant muscle that, when present, typically originates from the anterior tubercle of the transverse process of C7 and inserts into the suprapleural membrane (Sibson's fascia).

* *Bifid spine*: C7 is characterized by a long, prominent, and non-bifid spinous process (*Vertebra Prominens*).

* *Typical cervical*: C7 is considered an atypical vertebra because of its long spinous process and small or absent transverse foramina.

313) Which salivary gland is located above the mylohyoid muscle?

- A. Submandibular gland
- B. Minor labial glands
- C. Parotid gland
- D. Sublingual gland

➤ *Explanation*:

Correct Answer: D. Sublingual gland

* *Sublingual gland*: This gland is located in the sublingual fossa of the mandible, sitting directly above the mylohyoid muscle in the floor of the mouth.

* *Submandibular gland*: This gland consists of a large superficial lobe (below the mylohyoid) and a small deep lobe (above the mylohyoid), but it is primarily described as wrapping around the posterior border of the muscle.

* *Parotid gland*: This is located in the retromandibular region, far from the mylohyoid muscle.

314) Which of the following is not related to the scalp?

- A. Superior temporal line
- B. Highest nuchal line
- C. Superior nuchal line
- D. External occipital protuberance
- E. Skin of eyebrow

➤ *Explanation*:

Correct Answer: C. Superior nuchal line

* *Scalp Boundaries:* The scalp extends anteriorly to the eyebrows (E), laterally to the superior temporal lines (A), and posteriorly to the highest nuchal lines (B) and the external occipital protuberance (D).

* *Superior nuchal line:* The "Superior" nuchal line lies just below the "Highest" nuchal line. In strict anatomical terms, the highest line is the actual boundary for the epicranial aponeurosis.

315) Which of the following is incorrect regarding the treatment of acne?

- A. Topical antibiotics treat acne through both antibacterial and anti-inflammatory effects
- B. Some tretinoin formulations should be applied in the evening due to its photolability
- C. Oral isotretinoin systemic treatment can cause elevation of serum triglycerides and elevated liver enzymes
- D. Azelaic acid may cause a darkening effect

➤ *Explanation:*

Correct Answer: D. Azelaic acid may cause a darkening effect

* *Azelaic acid:* This agent is actually used to treat hyperpigmentation (dark spots) because it inhibits tyrosinase; it has a lightening effect, not a darkening one.

* *Antibacterial/Anti-inflammatory:* Topical antibiotics like clindamycin help by killing *C. acnes* and reducing redness.

* *Photolability:* Tretinoin (Retin-A) breaks down in sunlight, which is why it is recommended for nighttime use.

* *Isotretinoin:* Known side effects include hypertriglyceridemia and potential hepatotoxicity.

316) Duchenne Muscular Dystrophy is caused by a mutation in which chromosome region?

- A. Xp21
- B. Xq28
- C. 21q21
- D. 7p15

➤ *Explanation:*

Correct Answer: A. Xp21

* *DMD Gene:* Duchenne Muscular Dystrophy is an X-linked recessive disorder caused by a mutation in the DMD gene located on the short arm (p) of the X chromosome at position 21.

317) In sacralization of L5, how many lumbar vertebrae are present?

- A. 3
- B. 4
- C. 5
- D. 6
- E. 7

➤ *Explanation:*

Correct Answer: B. 4

* *Sacralization*: This is a congenital anomaly where the fifth lumbar vertebra (L5) fuses with the sacrum. Since there are normally 5 lumbar vertebrae, if the 5th one becomes part of the sacrum, only 4 mobile lumbar vertebrae remain.

318) Which parasite is known for causing zigzag migration under the skin?

- A. *Ancylostoma caninum*
- B. *Trichinella spiralis*
- C. *Enterobius vermicularis*
- D. *Ascaris lumbricoides*

➤ *Explanation*:

Correct Answer: A. *Ancylostoma caninum*

* *Cutaneous Larva Migrans*: This condition is caused by the larvae of hookworms (like *Ancylostoma caninum*). As they wander aimlessly under the skin (because humans are accidental hosts), they create a characteristic zigzag or serpiginous (snake-like) red track.

* *Trichinella*: Causes muscle pain after eating undercooked meat.

* *Enterobius/Ascaris*: These are primarily intestinal parasites that do not typically present with wandering skin lesions.

319) Which of the following is correct about atlas?

- A. Articulate only with axis
- B. Has no foramen in transverse process
- C. Has long anterior arch & short posterior arch
- D. Has spine
- E. Give attachment to inferior oblique muscle

➤ *Explanation*:

Correct Answer: E. Give attachment to inferior oblique muscle

* *Inferior oblique muscle*: The *Obliquus capitis inferior* muscle originates from the spine of the axis (C2) and inserts into the transverse process of the atlas (C1).

* *Articulation*: The atlas articulates with both the axis (atlanto-axial joint) and the occipital condyles of the skull (atlanto-occipital joint).

* *Foramen*: Like all cervical vertebrae, the atlas has a foramen transversarium for the vertebral artery.

* *Arch/Spine*: The atlas is unique because it has no body and no spine. It consists of a short anterior arch and a longer posterior arch.

320) Testicular artery arise from abdominal aorta at which level?

- A. 12th Thoracic
- B. 2nd Lumbar
- C. 3rd Lumbar
- D. 2nd Sacral

➤ *Explanation*:

Correct Answer: B. 2nd Lumbar: The testicular arteries (in males) or ovarian arteries (in females) are paired visceral branches that typically originate from the anterior aspect of the abdominal aorta at the level of the second lumbar vertebra (L2), just inferior to the renal arteries.

321) Dartos muscle is a continuation of which of the following in scrotum?

- A. Camper's fascia
- B. Scarpa's fascia
- C. Internal oblique aponeurosis
- D. External oblique aponeurosis
- E. Transversalis Fascia

➤ Explanation:

Correct Answer: A. Camper's fascia

* *Camper's fascia:* In the scrotum, the fatty layer of the superficial fascia (Camper's) loses its fat and is replaced by smooth muscle fibers known as the Dartos muscle.

* *Scarpa's fascia:* This membranous layer continues into the scrotum as Colles' fascia.

* *Dartos Function:* It is responsible for the wrinkling of the scrotal skin to help regulate the temperature of the testes.

322) All of the following considered key regulators of calcium blood level except:

- A. PTH
- B. Calcitonin
- C. Vit D
- D. Bone sialoproteins
- E. Some glycosamines

➤ Explanation:

Correct Answer: E. Some glycosamines

* *Glycosamines:* While they are components of the extracellular matrix in connective tissues, they are not primary hormonal or direct regulators of systemic blood calcium levels.

* *PTH (Parathyroid Hormone):* Increases blood calcium by stimulating osteoclasts.

* *Calcitonin:* Decreases blood calcium by inhibiting osteoclasts.

* *Vitamin D:* Enhances intestinal absorption of calcium.

* *Bone sialoproteins:* These are non-collagenous proteins in bone that play a role in mineralizing the matrix.

323) Which of the following drugs is used in Spinal causes of spasticity?

- A. Tizanidine
- B. Rocuronium
- C. Pancuronium
- D. Curare

➤ Explanation:

Correct Answer: A. Tizanidine

* Tizanidine: This is a centrally acting α_2 -adrenergic agonist. It is used specifically to manage spasticity associated with spinal cord injury or multiple sclerosis.

* Neuromuscular Blockers (B, C, D): Rocuronium, Pancuronium, and Curare are muscle relaxants used during anesthesia to cause total paralysis; they are not used for the long-term management of spasticity.

324) Which of the following features can distinguish woven bone from mature bone?

- A. No organized lamellated appearance
- B. The matrix of mature bone has more ground substance
- C. The mineral content is lower in mature bone

➤ Explanation:

Correct Answer: A. No organized lamellated appearance

* Woven Bone: This is immature bone where collagen fibers are randomly oriented (not organized). It lacks the lamellar (layered) structure seen in mature bone.

* Mature (Lamellar) Bone: Characterized by highly organized, parallel sheets of mineralized matrix (lamellae).

* Mineral Content: Woven bone generally has a lower mineral content and more osteocytes per unit area compared to mature bone.

325) Which of the following is a branch of femoral artery in the anterior abdominal wall?

- A. Superficial epigastric
- B. Deep epigastric
- C. Deep Circumflex iliac artery

➤ Explanation:

Correct Answer: A. Superficial epigastric

* Branching: The question asks for a branch of the femoral artery.

* Superficial epigastric artery and Superficial circumflex iliac artery are direct cutaneous branches of the femoral artery.

* The Deep Circumflex Iliac and Deep (Inferior) Epigastric are typically branches of the External Iliac Artery, while the Superficial Epigastric is a direct branch of the Femoral Artery.