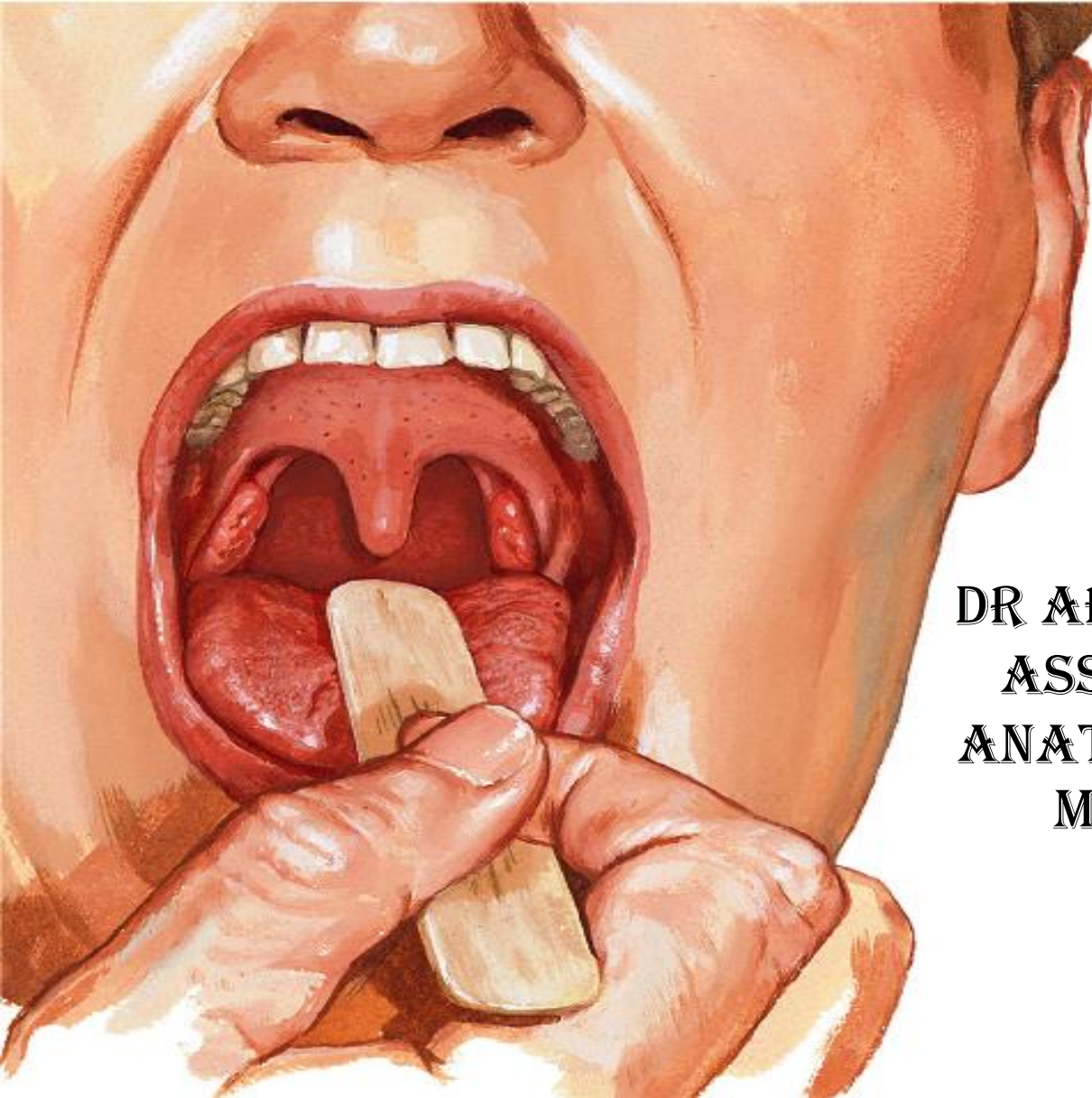


ORAL CAVITY & PALATE



BY

DR ABULMAATY MOHAMED
ASSISTANT PROFESSOR
ANATOMY & EMBRYOLOGY
MUTAH UNIVERSITY

ORAL CAVITY

Boundaries:

Anterior oral opening=oral fissure

opens on the face and bounded by lips

The lateral wall

Is formed by the cheek

Structure:-

1- Skin

2-buccal pad of fat

3-buccopharyngeal fascia

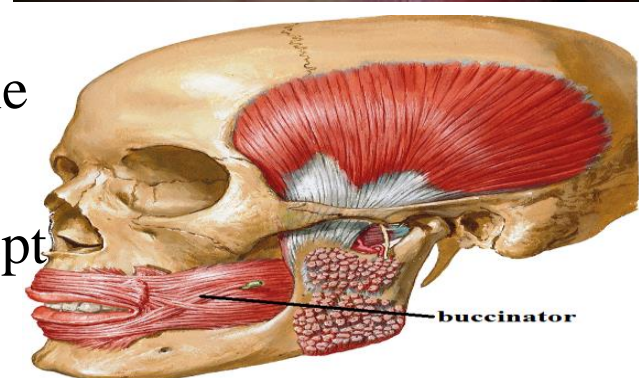
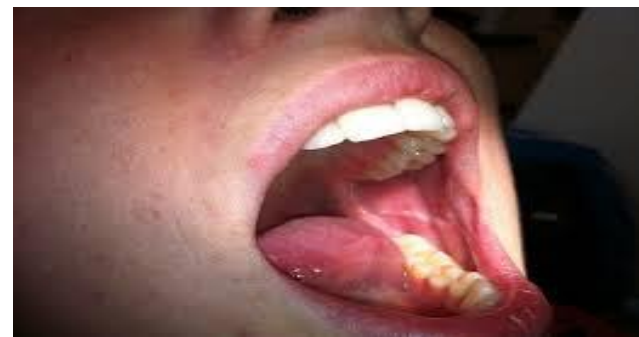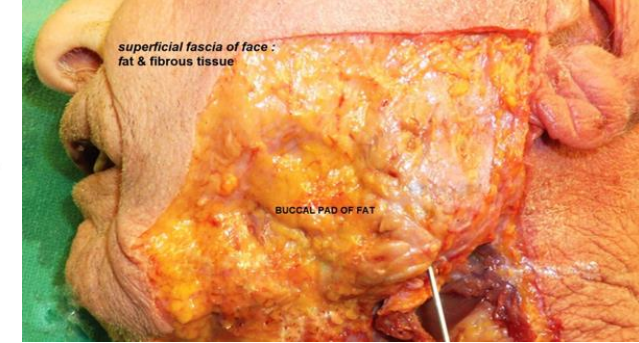
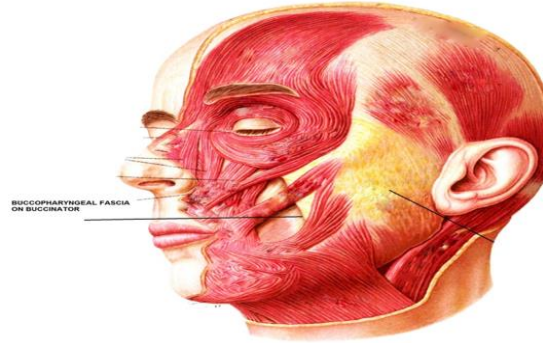
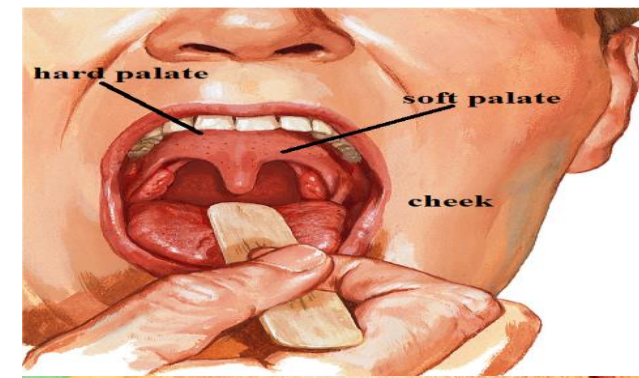
4-buccinators

5-mucous membrane.

-attached to buccinator

-the linea alba may be seen at the occlusal plane of the teeth

N.B. All these layers are pierced by parotid duct except the skin



ORAL CAVITY

Boundaries:

The roof

is formed of hard and soft palate

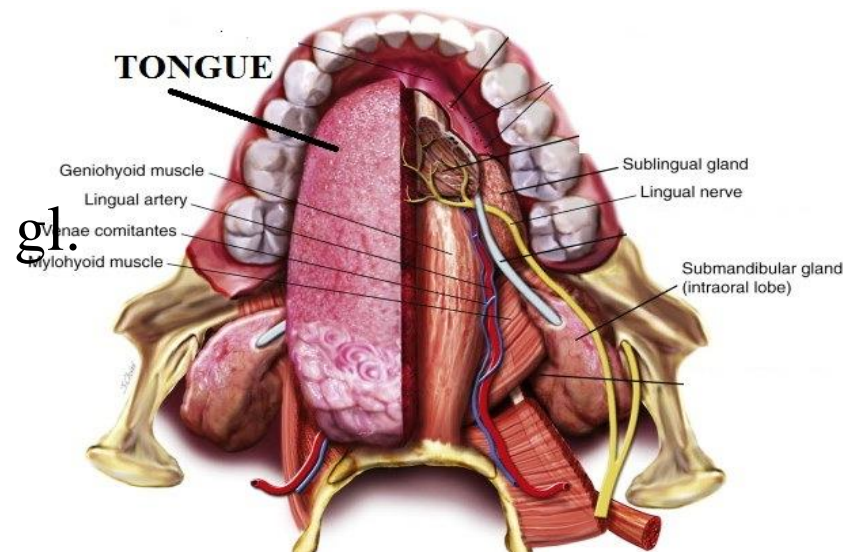
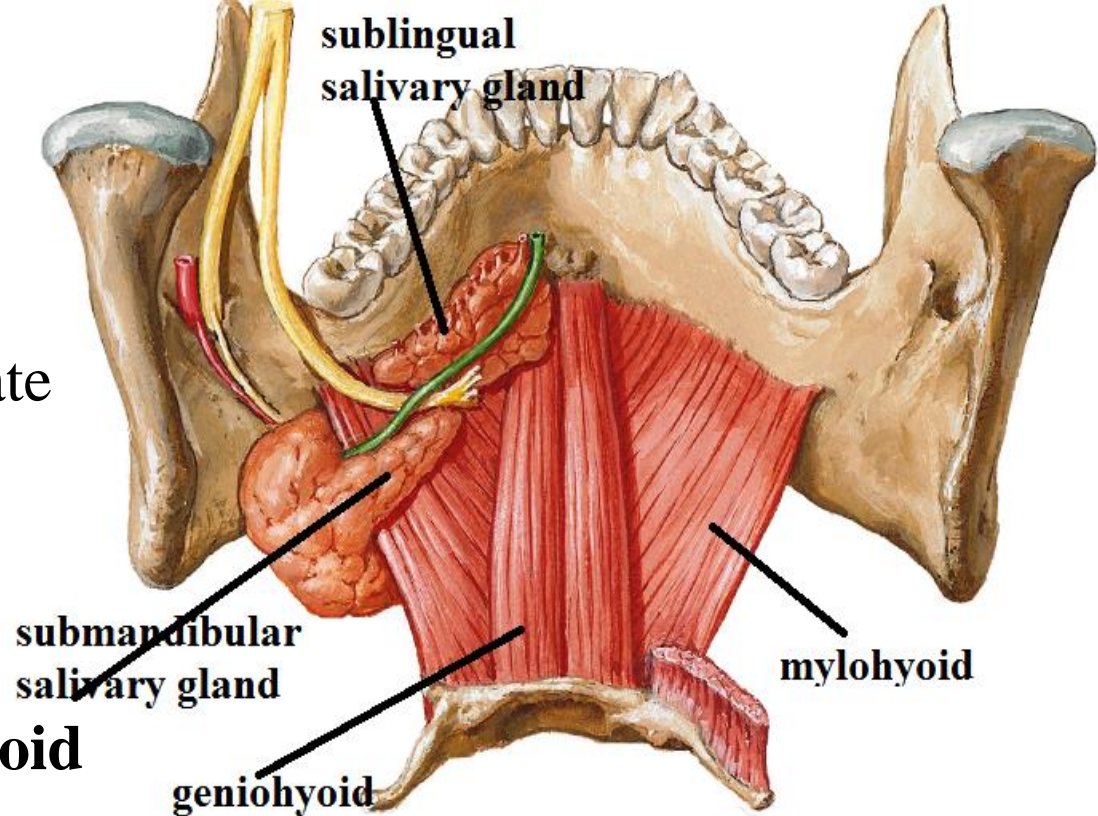
The floor:

is formed mainly by

**-2 mylohyoid muscles and
-the structures above mylohyoid**

which includes:

- Geniohyoid,
- sublingual salivary gland,
- deep part of submandibular salivary gl.
- tongue (with most of its muscles, vessels and nerves.



ORAL CAVITY

Boundaries:

The floor:

Below the tongue the floor shows the following features:

- **Lingual frenulum**

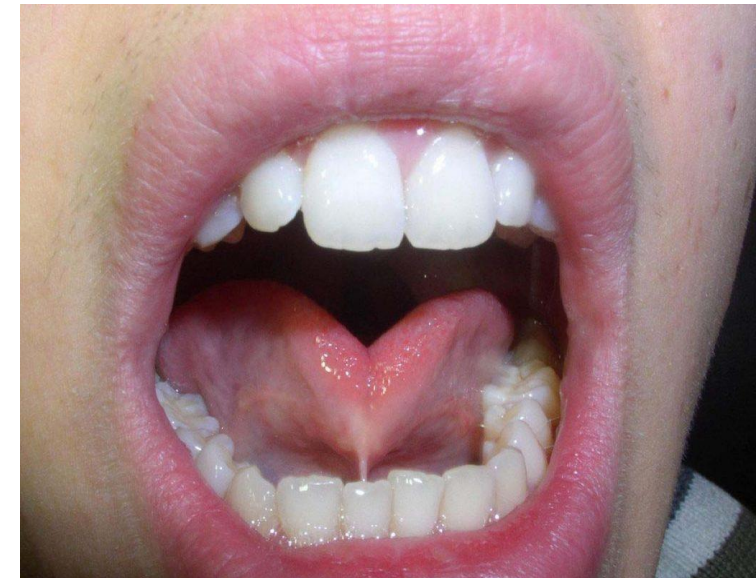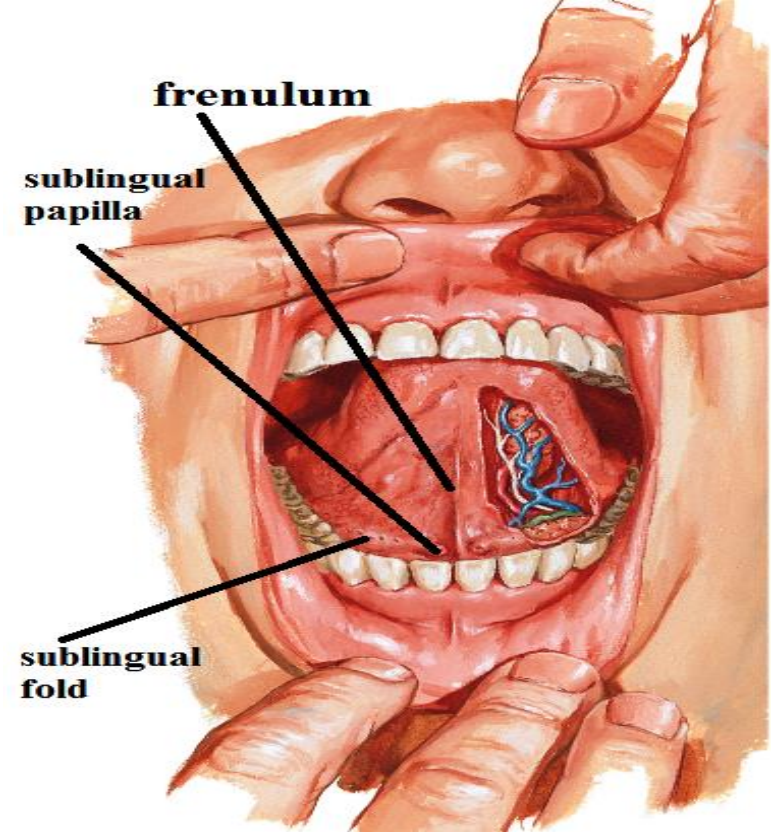
midline fold of mucous membrane connects the floor with the undersurface of tongue.

- **Sublingual papilla**

on the side of lingual frenulum at its attachment to the floor. for opening of submandibular duct

- **Sublingual fold:**

just lateral to the papilla, it is raised by sublingual salivary gland and receives the openings of most of the ducts of the gland.



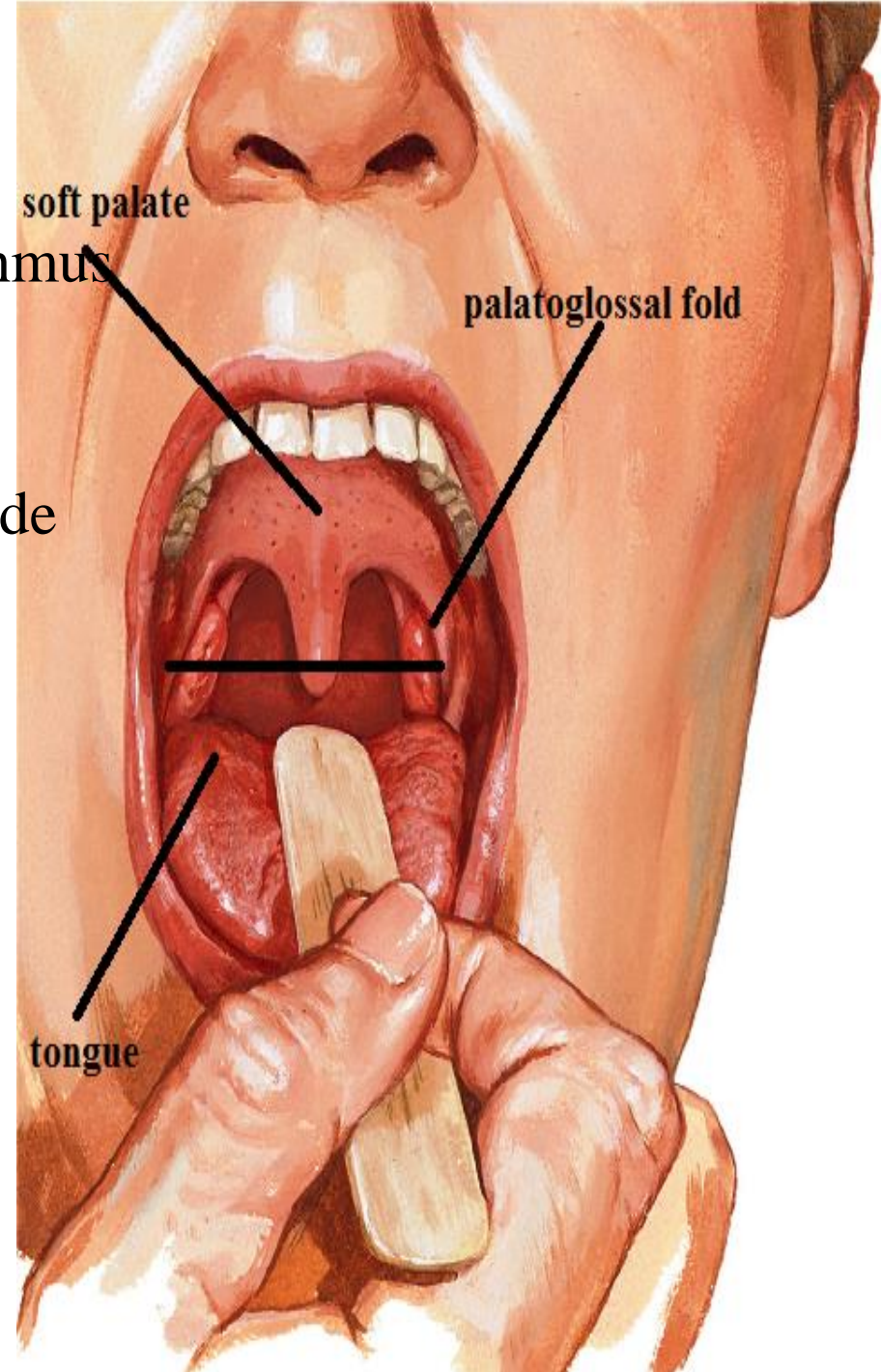
ORAL CAVITY

Boundaries:

Posterior opening = oropharyngeal isthmus
open into the oropharynx

bounded by:

- Palatoglossal arch (fold): on each side
- Soft palate above,
- Tongue below,



ORAL CAVITY

Parts

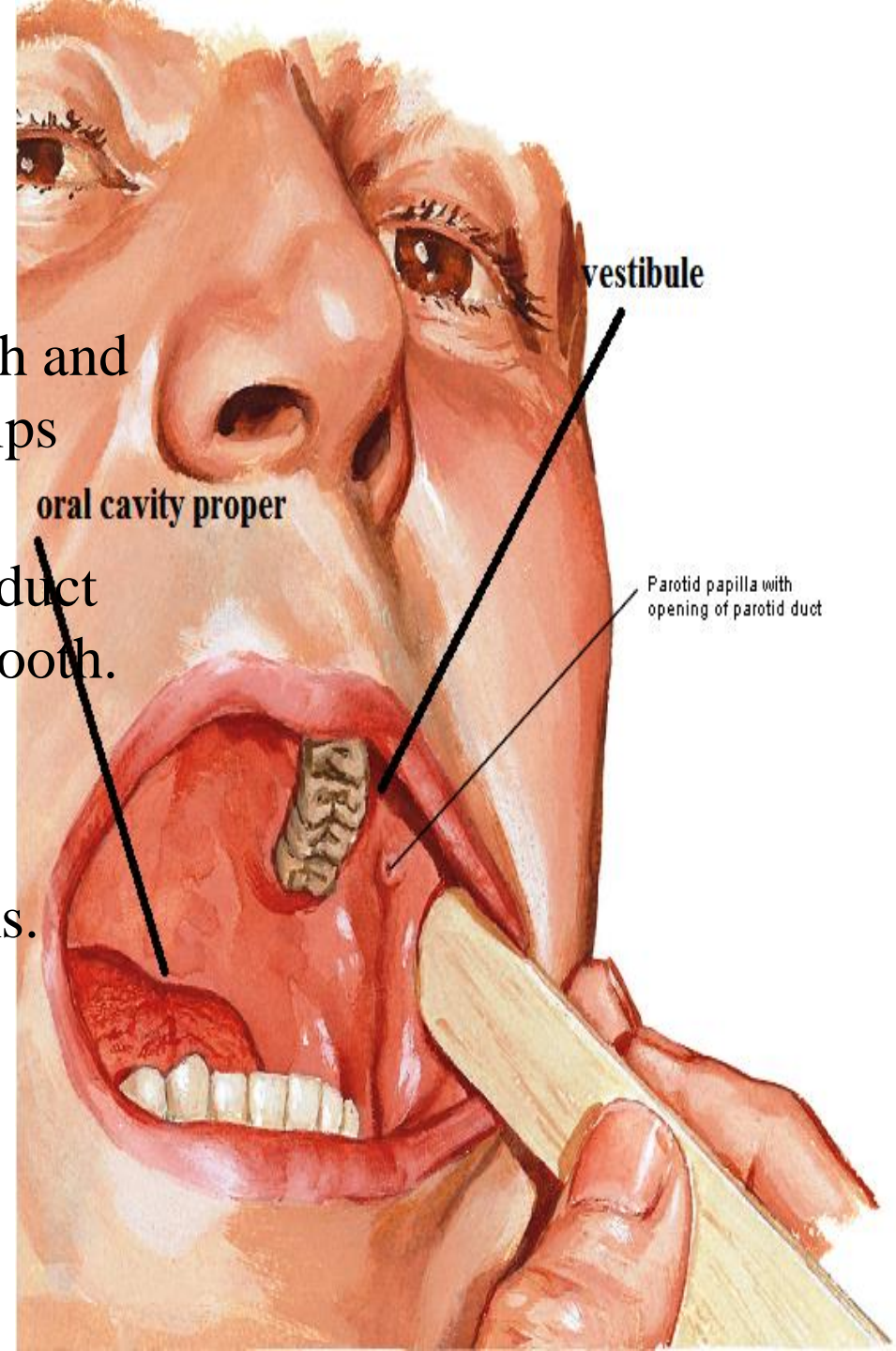
1- Vestibule:-

- the part of the cavity between teeth and gums internally and cheeks and lips externally.
- It receives the opening of parotid duct opposite the upper second molar tooth.

2- Oral cavity proper:

rest of oral cavity

i.e the part internal to teeth and gums.

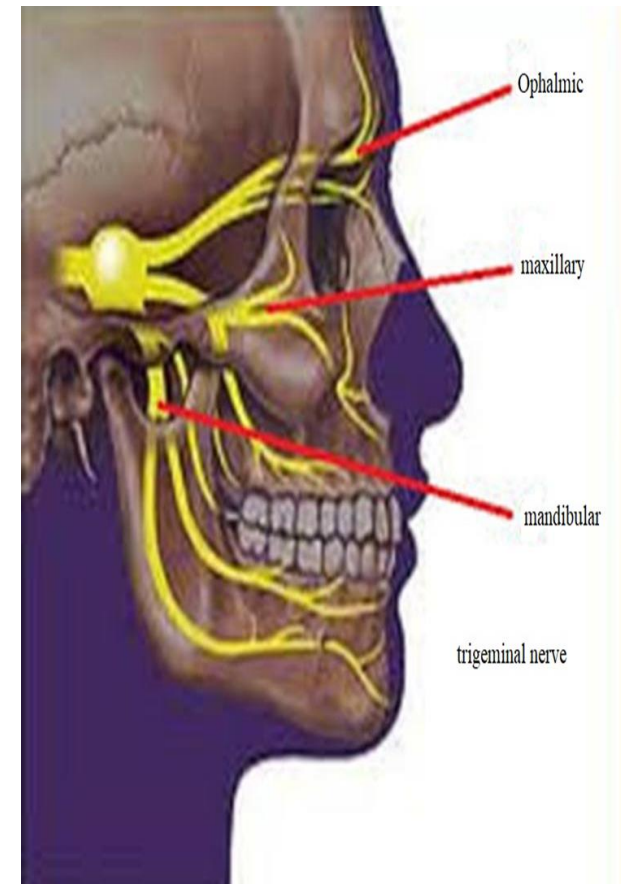


ORAL CAVITY

Sensory nerve supply:-

the general sensation is carried by the trigeminal nerve as follows:-

- the upper part including the palate and upper teeth :- maxillary nerve
- the lower part including the oral part of the tongue and lower teeth :- mandibular nerve



PALATE

Soft palate

Def.:- it is a fold of mucous membrane filled with muscle extending posteriorly from hard palate.

Surfaces and borders:

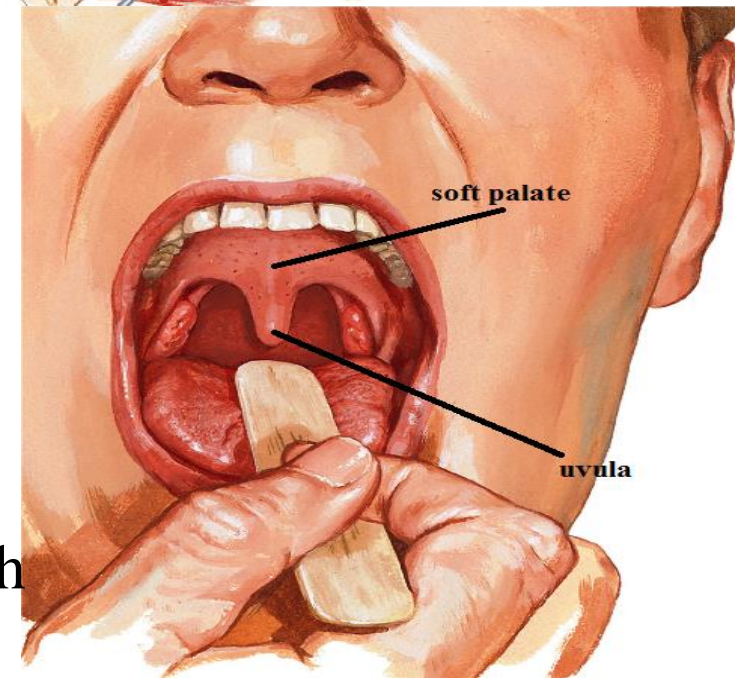
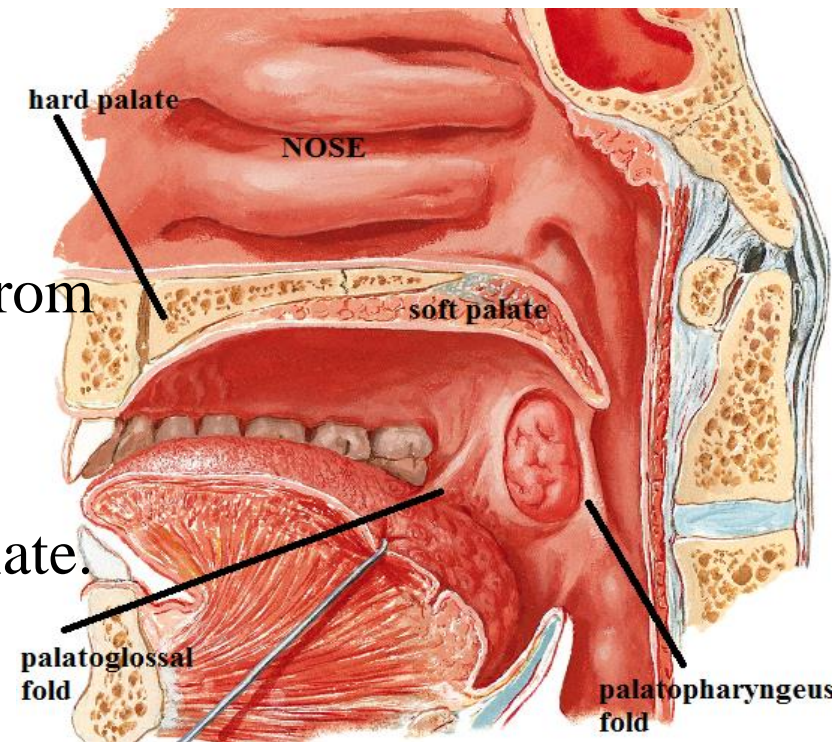
Attached ant. Border: attached to hard palate.

Free posterior (posteroinferior) border:

shows the uvula at midline, the uvula is a conical projection that hangs from the posterior border in midline,

Upper surface: its mucous membrane continuous with that of floor of nose.

Inferior surface: its mucous membrane is continuous with that covering hard palate, Palatoglossal arch and palatopharyngeal arch start at this surface.



PALATE

Muscles of soft palate 5 pairs of muscles

1- Tensor palati:

O.: - Scaphoid fossa

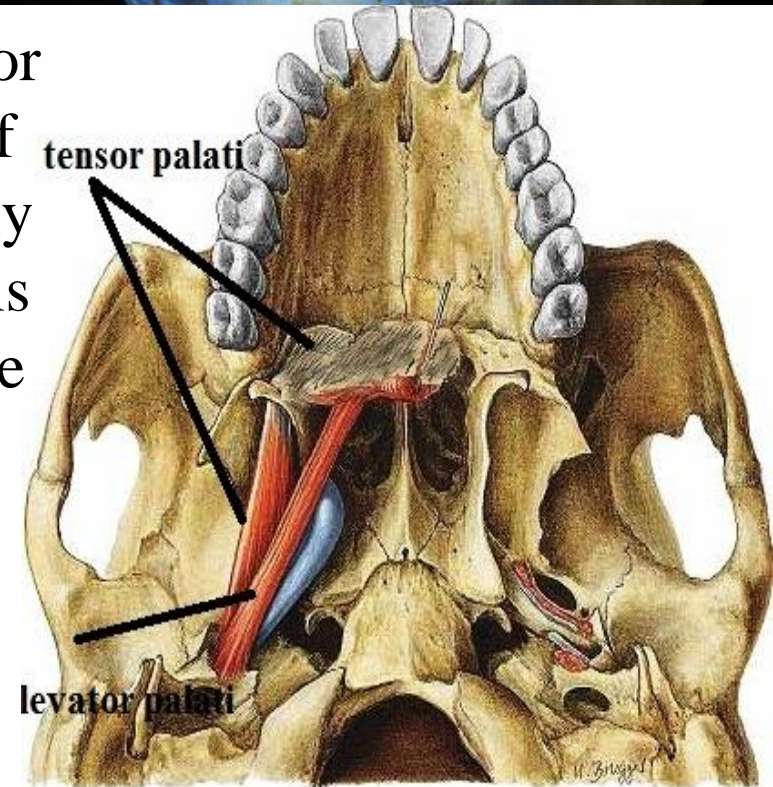
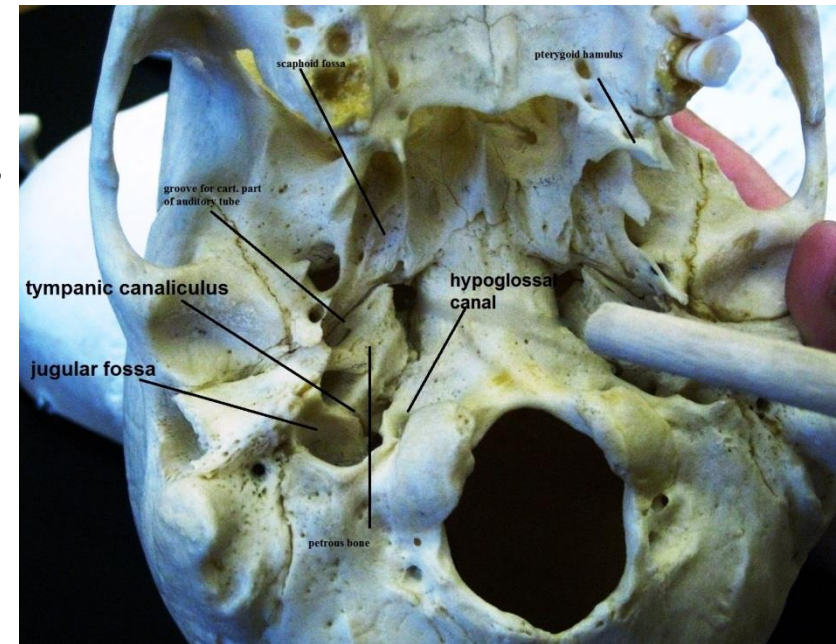
- Cartilaginous part of auditory tube.

I.: by a palatine aponeurosis into post. border of hard palate

Palatine aponeurosis: Muscle fibres of tensor palati form a slender tendon at lateral side of pterygoid hamulus, the tendon turns medially and expands to form the palatine aponeurosis which forms the basic structure of soft palate to which are inserted or from which-arise other structures of the palate

Action:-tensor for soft palate.

-opening of auditory tube.



PALATE

2-Levator palati muscle.

O.: - petrous bone

- Cartilaginous part of auditory tube.

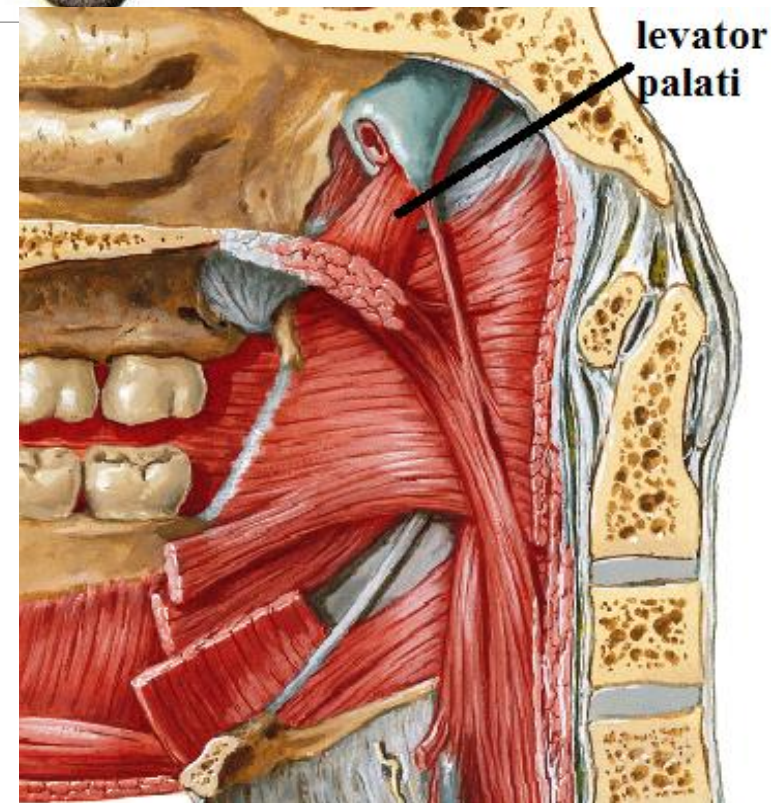
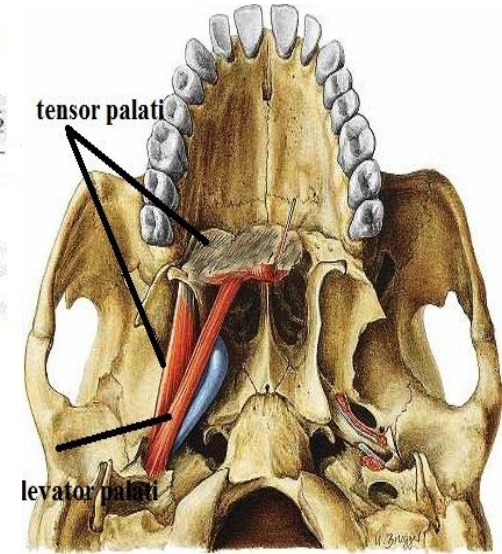
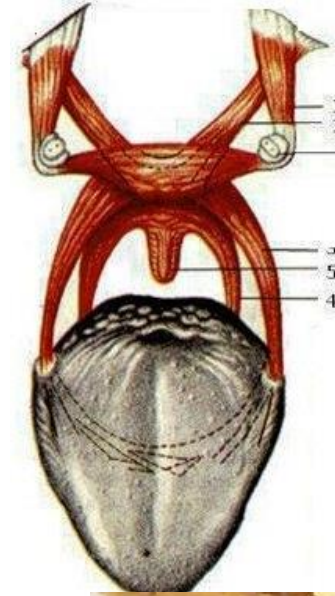
I.: - upper surface of palatine aponeurosis

Action: - elevates the palate.

-open auditory tube (little effect)

-Both actions of tensor palati and levator palati leads to elevation of soft palate to be applied to post, wall of pharynx closing the pharyngeal isthmus, this occurs during swallowing to prevent regurge of food to nasal cavity.

N.B.: - to test the levator palati
ask the patient to say (AH)



PALATE

3-Palatoglossus muscle:

4-Palatopharyngeus muscle: .

5-Musculus uvulae:

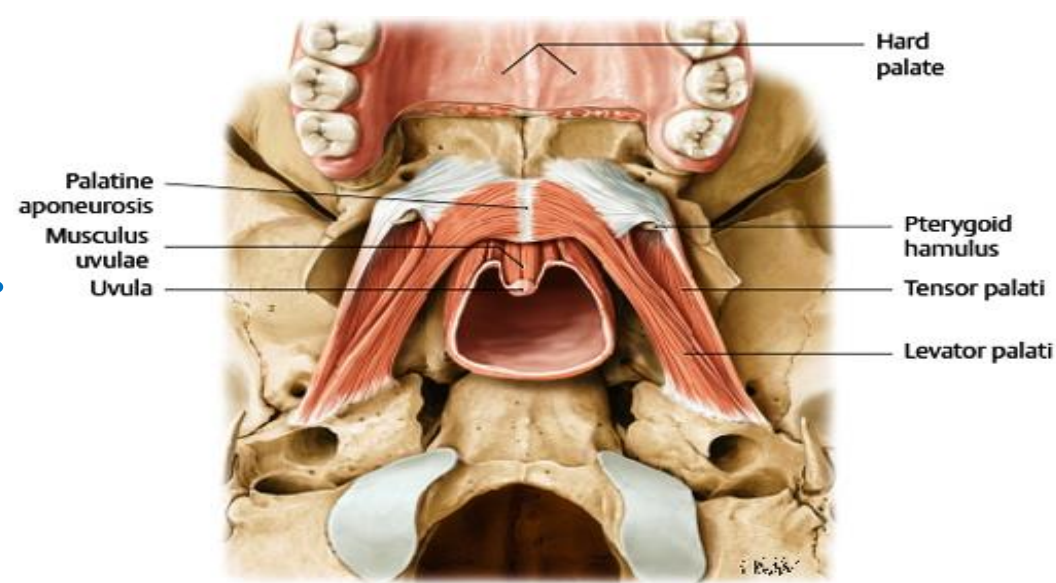
O.: post. nasal spine.

I.: mucous membrane of uvula.

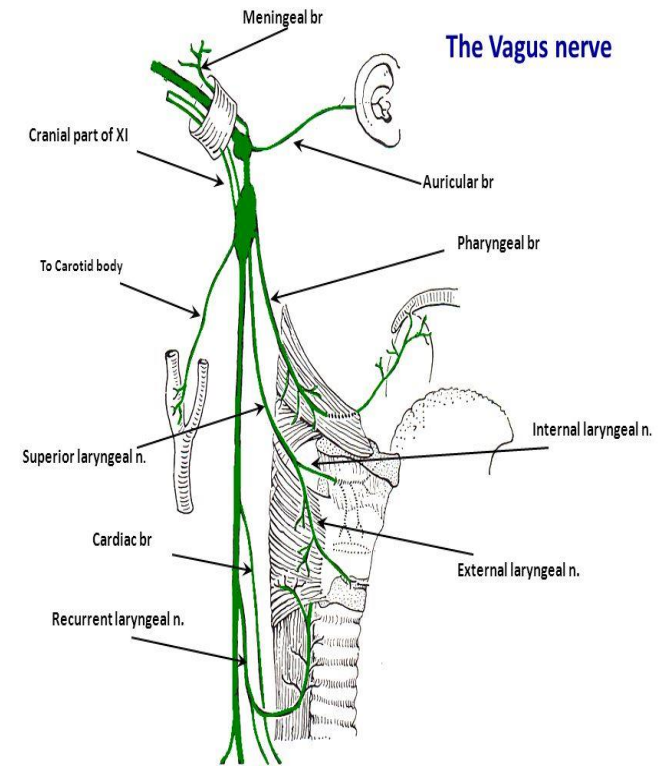
Action: pull uvula to its own side.

Nerve supply of palate

Motor: all muscles of palate are supplied by cranial part of accessory nerve through vagus except tensor palati which is supplied by mandibular branch of the trigeminal nerve



Inferior View of Hard and Soft Palate



PALATE

Nerve supply of palate

Sensory:

Lesser palatine nerves: of pterygopalatine ganglion.

Tonsillar branch of Glossopharyngeal n.

Blood supply:

Arteries:-

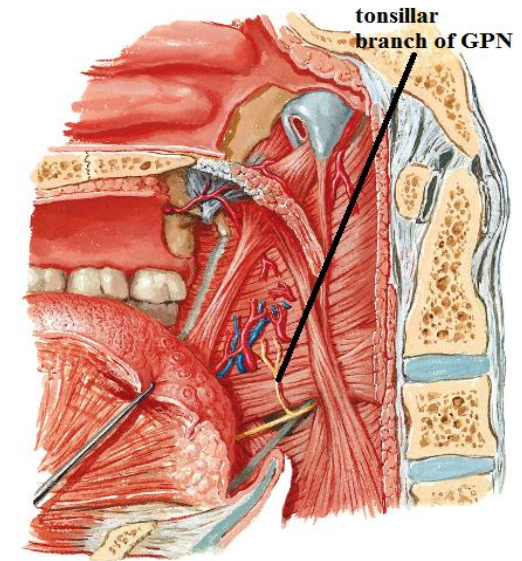
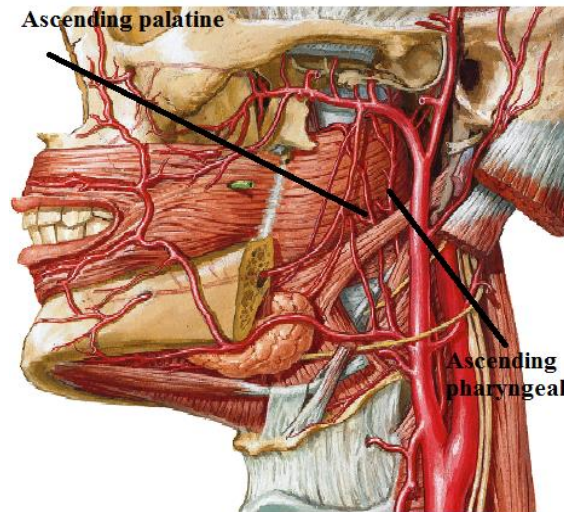
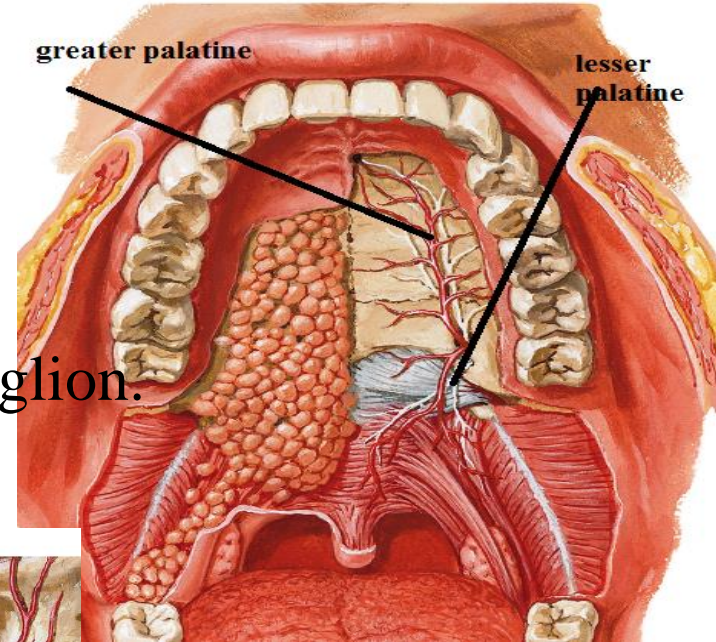
greater palatine art.

Ascending palatine art.

Ascending pharyngeal art.

Veins:

-Accompanying veins end in: pterygoid and pharyngeal venous plexuses



PALATE

N.B.:- Function of soft palate:-

1- during respiration: -

relax to allow air to pass () nasopharynx & oropharynx

2- during swallowing:-

stretched by tensor palati & elevated by levator palati to close pharyngeal isthmus to prevent regurge of food into nasopharynx

THANQ