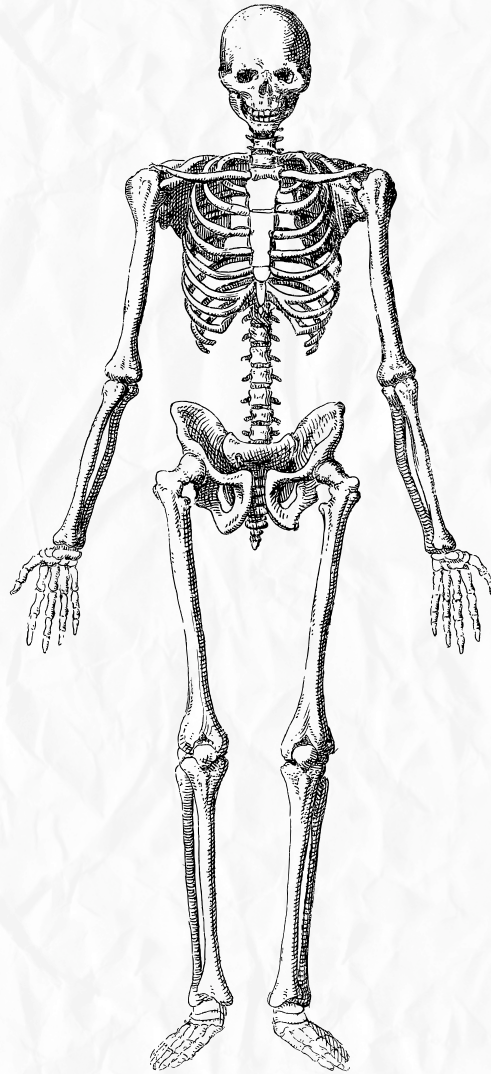


# Anatomy

Quiz time



Upper limb muscle

Done by: Lana Rasheed

?Which of the following is not true as regard the Brachial plexus

It's root lie in the neck

It's cords lie in the axilla

Formed of 5 nerves

It's trunks lie behind the clavicle

Ans:D

?Concerning the medial cord of the Brachial plexus all correct except

1 Gives origin to the ulnar nerve

2 form part of the median nerve

3 continues fibers of the fifth cervical nerve

4 give a branch to radial

Ans:3

The brachial plexus originates specifically from the anterior rami of five spinal nerve levels. Which specific level is considered the most inferior root of this network

A.T2

B.C7

C.T1

D.C8

Ans:C

Which anatomical structure is formed by the union of the C5 and C6 roots as they exit between the scalene muscles

A.Middle Trunk

B.Lateral Cord

C.Posterior Division

D.Superior Trunk

Ans:D

In the 'Great Divide' of the plexus, what is the primary functional destination for nerves arising from the anterior divisions

A.Extensor compartments of the arm and forearm

B.The deltoid and teres minor muscles

C.Cutaneous innervation of the posterior hand

D.Flexor compartments of the arm and forearm

Ans:D

The three cords of the brachial plexus are named based on their physical relationship to which central structure

- A. Clavicle
- B. Scalene Muscles
- C. Humerus
- D. Axillary Artery

Ans: D

The Posterior Cord is unique in its formation compared to the Lateral and Medial cords. How is it constituted

- A. The union of the superior and middle anterior divisions
- B. The union of C8 and T1 roots
- C. Convergence of all three posterior divisions
- D. Direct continuation of the inferior trunk's posterior division

Ans: C

Which terminal nerve is formed by contributions from both the Lateral and Medial cords

- A. Musculocutaneous Nerve
- B. Radial Nerve
- C. Ulnar Nerve
- D. Median Nerve

Ans: D

A patient presents with a loss of sensation on the lateral aspect of the forearm. Which nerve is most likely compromised

- A. Axillary Nerve
- B. Median Nerve
- C. Musculocutaneous Nerve
- D. Radial Nerve

Ans: C

Which nerve would be affected by a fracture at the surgical neck of the humerus due to its tight looping around that specific bone landmark

- A. Axillary Nerve
- B. Radial Nerve
- C. Ulnar Nerve
- D. Median Nerve

Ans: A

If a patient cannot flex their thumb or index finger and has lost sensation on the palmar surface of those digits, which nerve is damaged

- A. Median Nerve
- B. Ulnar Nerve
- C. Musculocutaneous Nerve
- D. Radial Nerve

Ans:A

?Which of the following describes a 'Dermatomal Distribution' of sensory mapping

- A. The physical path a nerve takes as it passes through the axilla
- B. A motor map identifying which spinal roots innervate specific muscle groups
- C. An area of skin supplied by sensory neurons originating from a single spinal nerve root
- D. An area of skin supplied by a single peripheral nerve branch containing fibers from multiple roots

Ans:c

The Radial Nerve is the primary nerve for the entire posterior compartment of both the arm and forearm. From which cord does it originate

- A. Superior Trunk
- B. Posterior Cord
- C. Medial Cord
- D. Lateral Cord

Ans:B

?What is the root composition of the Ulnar Nerve according to the provided schematics

- A. C7-T1
- B. C8-T1 only
- C. C5-C7
- D. C5-T1

Ans:A

Which nerve is responsible for the motor control of the hypothenar eminence and the intrinsic hand muscles known as lumbricals 3 and 4

- A. Radial Nerve
- B. Median Nerve
- C. Ulnar Nerve
- D. Axillary Nerve

Ans:C

According to the detailed anatomical diagram, which nerve arises directly from the roots themselves rather than from a trunk or cord

- .A. Suprascapular N
- .B. Lateral pectoral N
- .C. Axillary N
- .D. Dorsal scapular N

Ans: D

The Median nerve provides sensory innervation to which specific part of the hand

- A. Superior portion of the lateral arm
- B. Medial half of digit 4 and all of digit 5
- C. Lateral dorsum of the hand
- D. Medial palmar side and digits 1 through 3, and exactly half of digit

Ans: D

Which cord of the brachial plexus is essentially a direct continuation of the anterior division of the inferior trunk

- A. Posterior Cord
- B. Middle Trunk
- C. Lateral Cord
- D. Medial Cord

Ans: D

The 'Long thoracic N.' is visible in the detailed diagram. From which spinal roots does it receive contributions

- A. C4 and C5
- B. C5 and C6 only
- C. C8 and T1
- D. C5, C6, and C7

Ans: D

A lesion to the C6 spinal root would most likely affect sensation in which cutaneous field, despite the root fibers being split among multiple nerves

- A. The thumb and lateral forearm
- B. The superior shoulder (deltoid area)
- C. The pinky finger and medial hand
- D. The middle finger only

Ans: A

?Which of the following nerves carries fibers originating from the most spinal roots (C5 through T1)

- A.Axillary Nerve
- B.Musculocutaneous Nerve
- C.Radial Nerve
- D.Ulnar Nerve

Ans:C

?What is the primary motor function of the Axillary Nerve

- A.Innervates the biceps brachii and brachialis
- B.Controls the fine movements of the thumb
- C.Innervates the deltoid and teres minor muscles
- D.Innervates all muscles of the posterior arm (triceps)

Ans:C

?Where does the Brachial Plexus physically originate in the body

- A.Directly behind the clavicle bone
- B.Inside the axilla (armpit)
- C.Posterior triangle of the neck
- D.Between the bicep and tricep muscles

Ans:C

Which nerve is described as the 'terminal branch' of the Medial Cord that does not contribute to the 'M' shape of the median nerve'

- .A.Medial pectoral N
- B.Radial Nerve
- C.Axillary Nerve
- D.Ulnar Nerve

Ans:D

:The 'Middle Trunk' of the plexus is unique because

- .A.It does not contribute to the posterior cord
- .B.It gives rise to the axillary nerve directly
- .C.It contains only posterior division fibers
- D.It is a direct continuation of the
- .C7 root

Ans:D

?In the context of 'The Great Divide', which compartment do posterior divisions ultimately serve

- A. Rotators
- B. Extensors
- C. Flexors
- D. Adductors

Ans: B

The 'Medial pectoral N.' and 'Medial brachial cutaneous N.' are branches of which part of the plexus  
?architecture

- A. Inferior Trunk
- B. Medial Cord
- C. Anterior Division of the Middle Trunk
- D. Posterior Cord

Ans: B

?Which nerve is formed by the anterior divisions of the Superior and Middle trunks

- A. Medial Cord
- B. Posterior Cord
- C. Lateral Cord
- D. Median Nerve

Ans: C

?dermatome, which part of the limb are they examining

- A. The medial forearm and 5th digit
- B. The middle finger and central hand
- C. The lateral aspect of the shoulder and upper arm
- .D  
The lateral aspect of the hand and thumb

Ans: C

?from which section of the brachial plexus

- A. Superior Trunk
- B. Roots
- C. Medial Cord
- D. Divisions

Ans: A

Which nerve provides sensory supply to the 5th digit (pinky) and exactly half of the 4th digit (ring finger)?

- A. Ulnar Nerve
- B. Radial Nerve
- C. Musculocutaneous Nerve
- D. Median Nerve

Ans: A

30 /

?What happens to the Inferior Trunk as it approaches the clavicle

- .A. It merges with T2 to form the intercostobrachial nerve
- .B. It directly becomes the ulnar nerve
- .C. It splits into an anterior and a posterior division
- .D. It joins with the middle trunk to form the lateral cord

Ans: C

طب الأسنان

”أنت فردٌ من أفراد هذه الأمة  
وجزءٌ من أجزائها، فنهوضك  
نهوضها وسقوطك سقوطها،  
والأمة -كما تعلم- هي الفرد  
المتكرّر والواحدُ الدائر،  
فأنت الأمة والأمة أنت“