

Small and Large Intestinal pathology, part 2

Dr. Omar Hamdan

Gastrointestinal and liver pathologist

Mutah University

School of Medicine-Pathology Department

Undergraduate Lectures 2025



Diseases of the intestines

- ▶ Intestinal obstruction
- ▶ Vascular disorders
- ▶ Malabsorptive diseases and infections
- ▶ **Inflammatory bowel disease.**
- ▶ Polyps and neoplastic diseases

INFLAMMATORY INTESTINAL DISEASE

- ▶ **Sigmoid Diverticulitis**
- ▶ **Chronic Inflammatory bowel diseases (CIBD):** Crohn disease and Ulcerative colitis

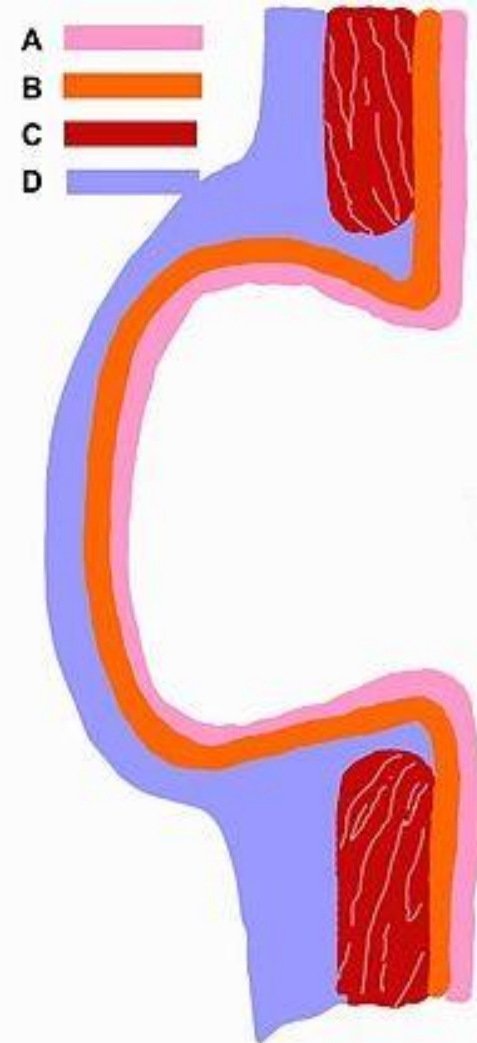
Sigmoid Diverticulitis

- ▶ **Acquired.**
- ▶ Elevated intraluminal pressure in the sigmoid colon
- ▶ Exaggerated peristaltic contractions,
- ▶ Low fiber diet and constipation.

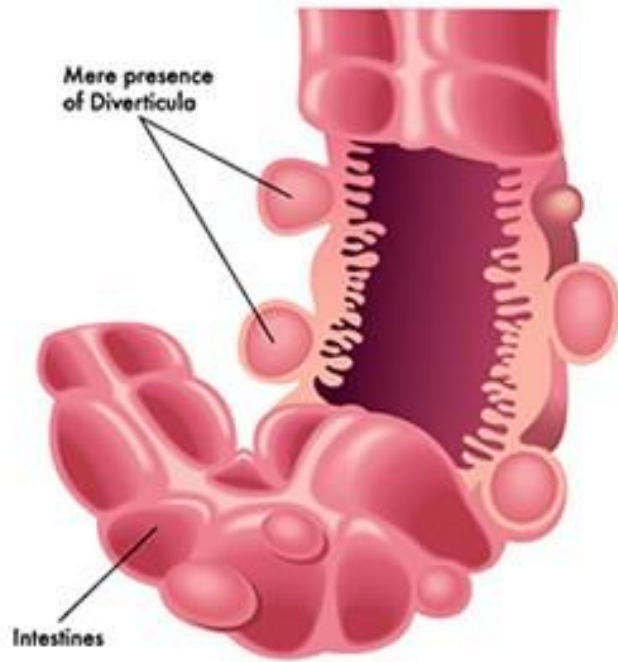
- ▶ Pseudodiverticulae
- ▶ Outpouchings of colonic mucosa and submucosa

MORPHOLOGY

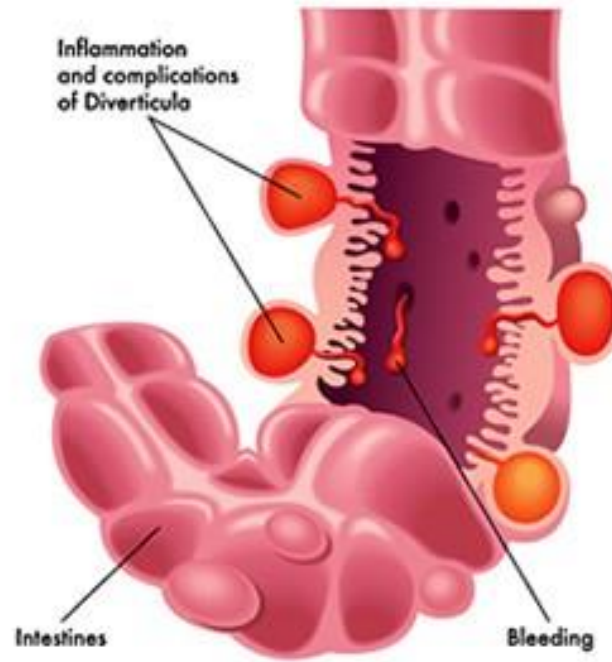
- ▶ Flasklike outpouchings
- ▶ **Mostly in sigmoid colon.**
- ▶ Thin wall (atrophic mucosa, compressed submucosa)
- ▶ Attenuated or absent muscularis.
- ▶ Obstruction leads to diverticulitis.
- ▶ Risk of perforation.
- ▶ Recurrent diverticulitis leads to strictures.

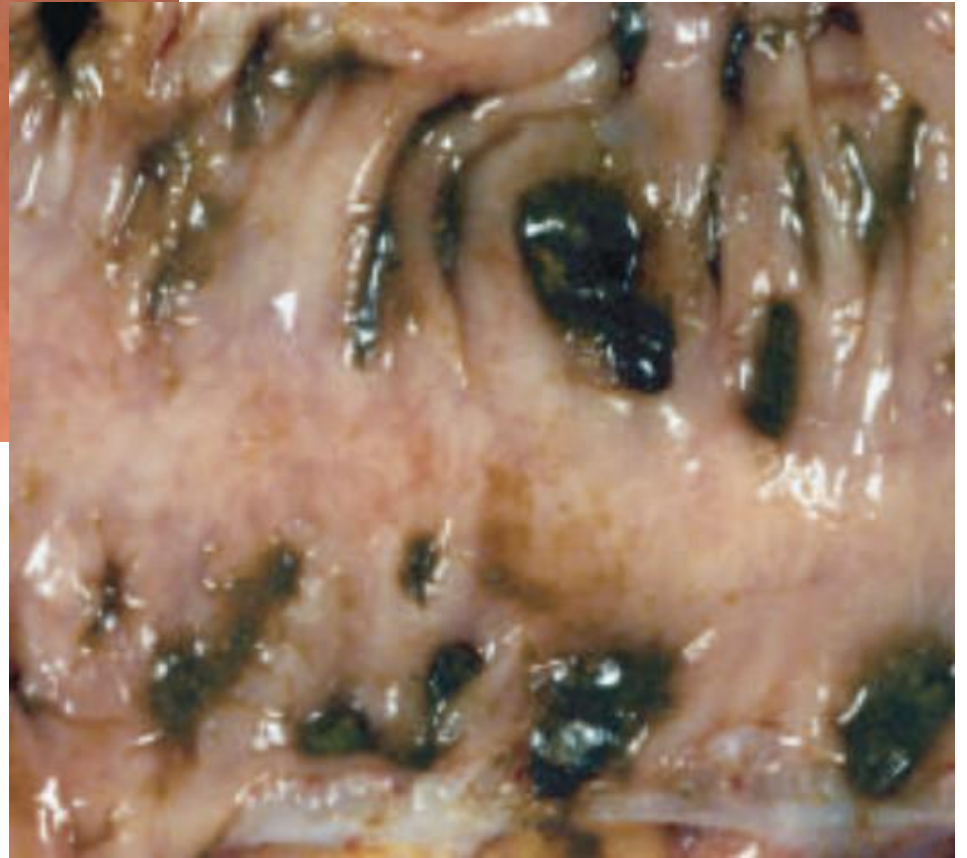
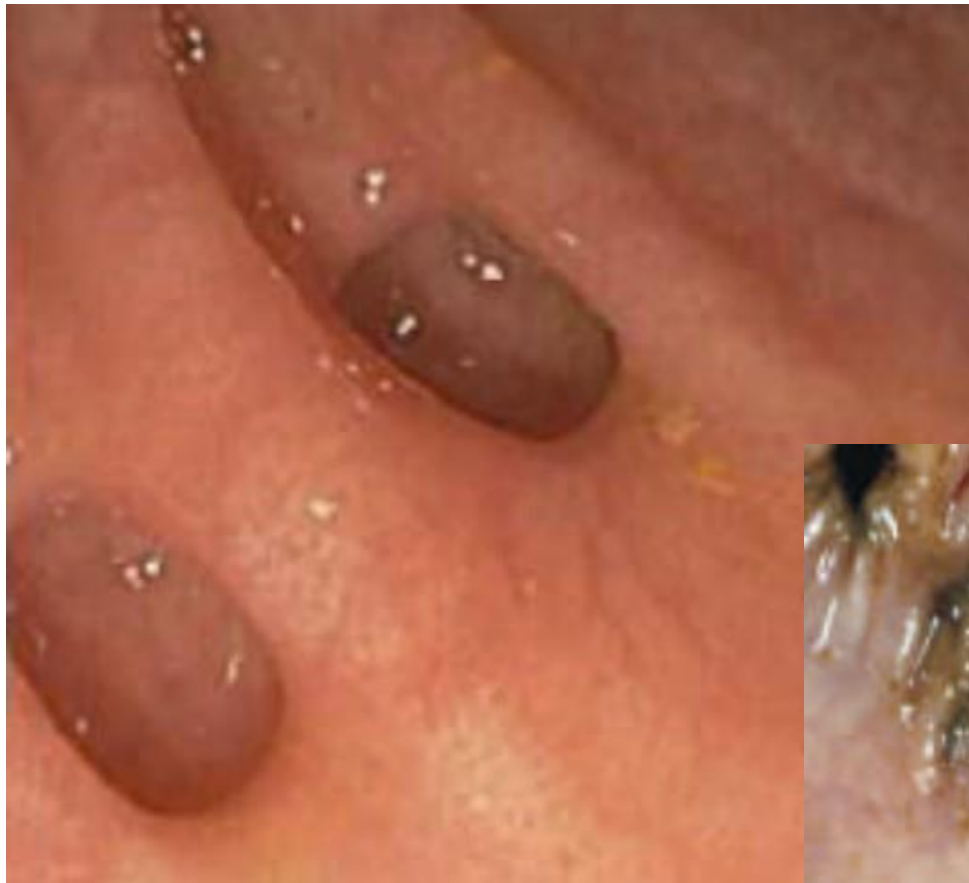

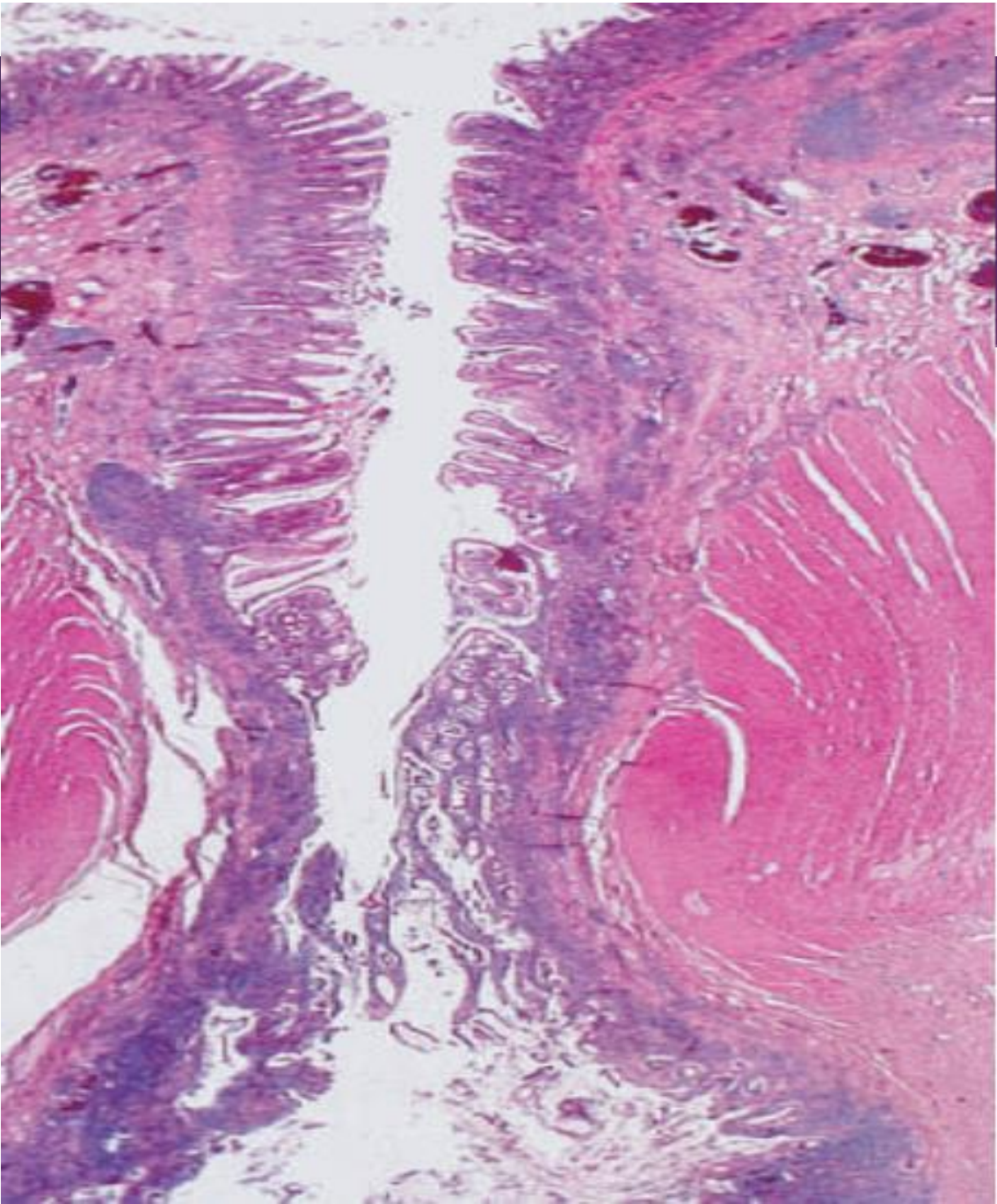
Diverticulosis



Diverticulitis







Clinical Features

- ▶ Mostly asymptomatic.
- ▶ Intermittent lower abdominal pain
- ▶ Constipation or diarrhea.

- ▶ Tx:

High fiber diet.

Antibiotics in diverticulitis.

Surgery.

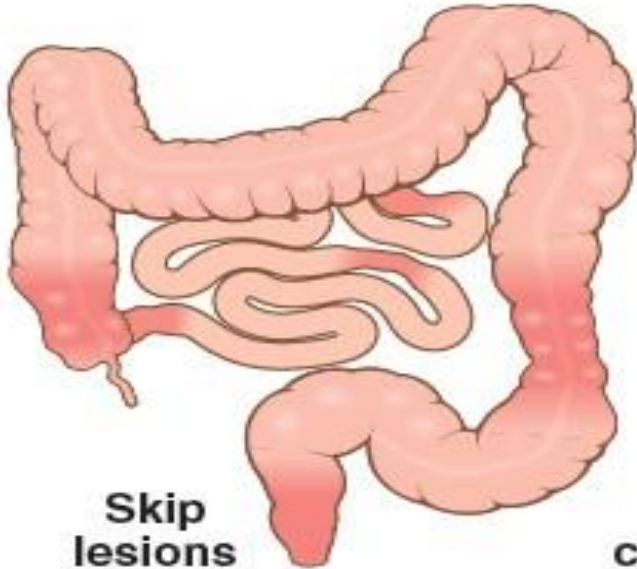Inflammatory Bowel Disease

- ▶ Chronic IBD.
- ▶ Genetic predisposition.
- ▶ Inappropriate mucosal damage.

- ▶ *Ulcerative colitis: limited to the colon and rectum, extends only into mucosa and submucosa.*

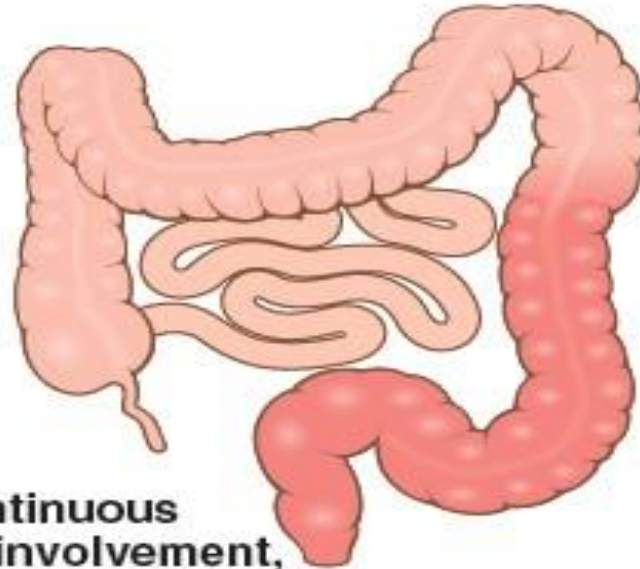
- ▶ *Crohn disease: regional enteritis, frequent ileal involvement, affect any area in GIT, frequently transmural.*

CROHN DISEASE

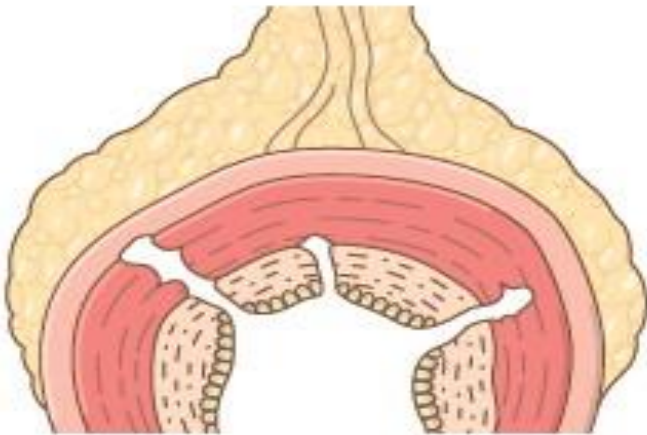


Skip lesions

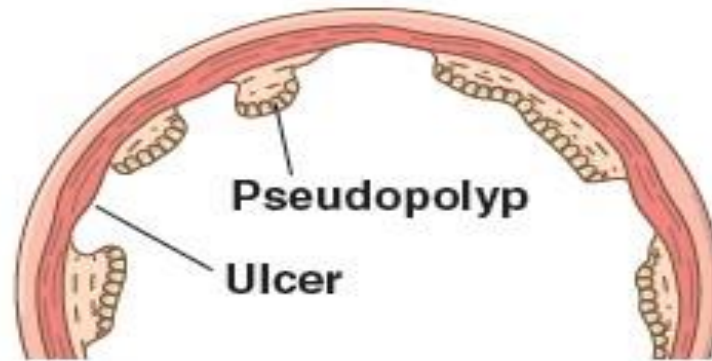
ULCERATIVE COLITIS



Continuous colonic involvement, beginning in rectum



**Transmural inflammation
Ulcerations
Fissures**



**Pseudopolyp
Ulcer**

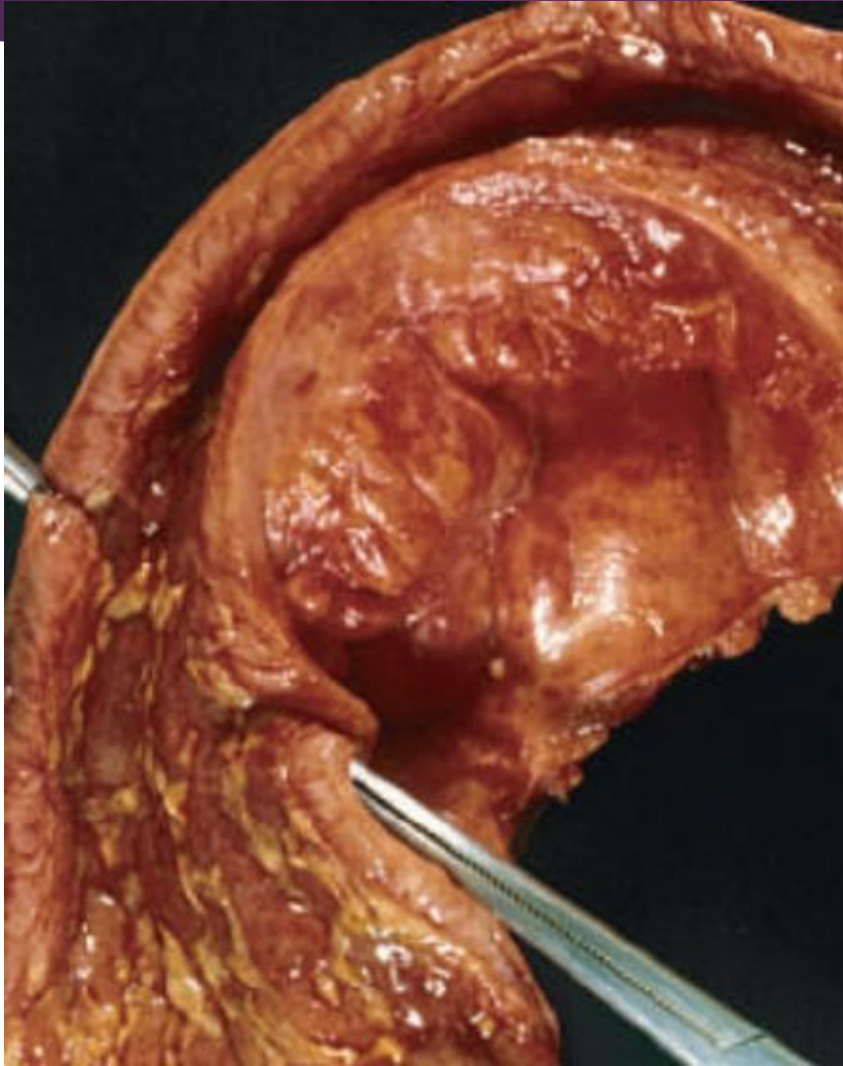
Epidemiology


- ▶ Adolescence & young adults
- ▶ 2nd peak in fifth decade.
- ▶ Geographic variation.
- ▶ **Hygiene hypothesis**: *childhood exposure to environmental microbes prevents excessive immune system reactions. Firm evidence is lacking!!!.*

Crohn Disease Morphology

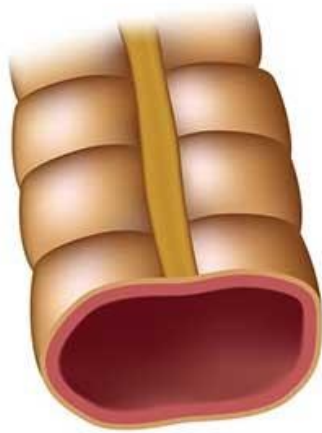- ▶ Macroscopic:
- ▶ Regional enteritis.
- ▶ **Any area of GIT.**
- ▶ Most common sites: terminal ileum, ileocecal valve, and cecum.
- ▶ Small intestine alone 40%
- ▶ Small intestine and colon 30%
- ▶ Colon only 30%
- ▶ **Skip lesions**
- ▶ Strictures common

Small bowel stricture.

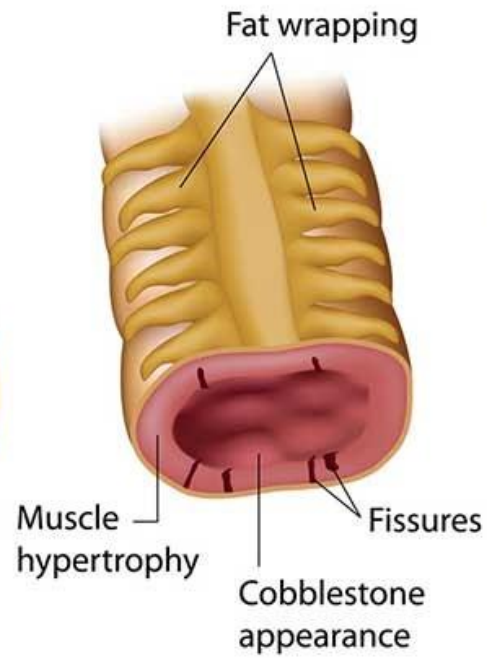


- 
- ▶ Earliest lesion: aphthous ulcer
 - ▶ Elongated, serpentine ulcers.
 - ▶ Edema , loss of bowel folds.
 - ▶ Cobblestone appearance
 - ▶ Fissures, fistulas, perforations.
 - ▶ Thick bowel wall (transmural inflammation, edema, fibrosis, hypertrophic MP)
 - ▶ Creeping fat

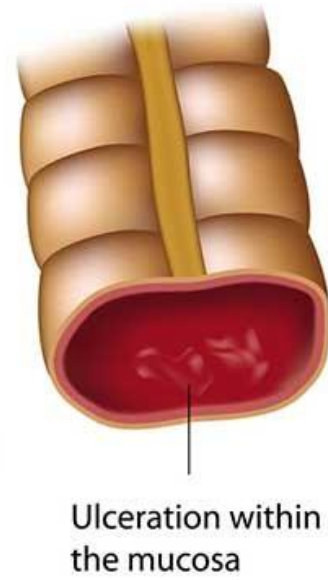
Healthy

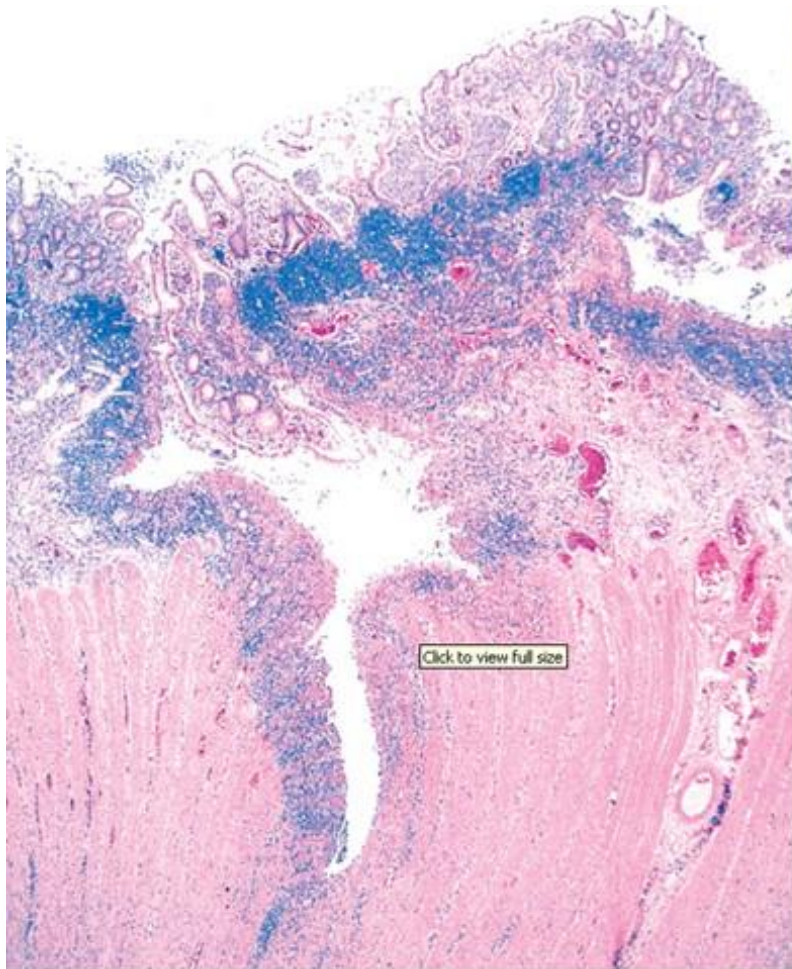


Crohn's disease



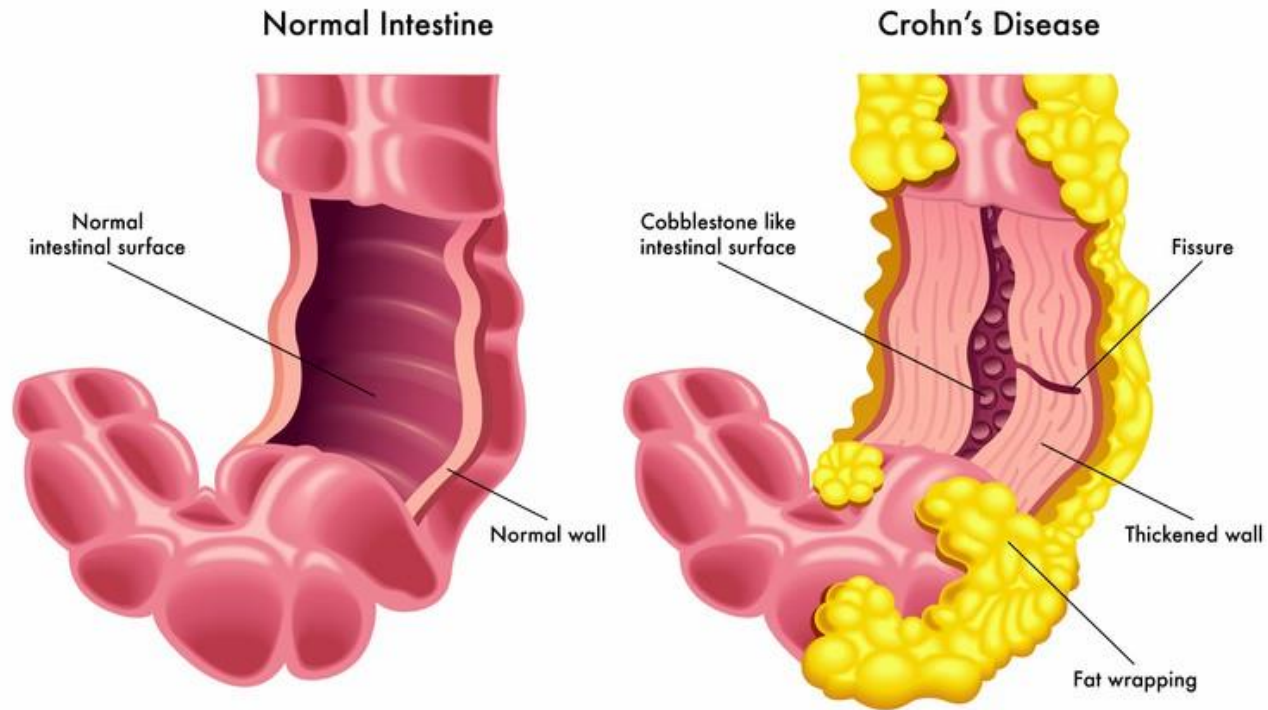
Ulcerative colitis





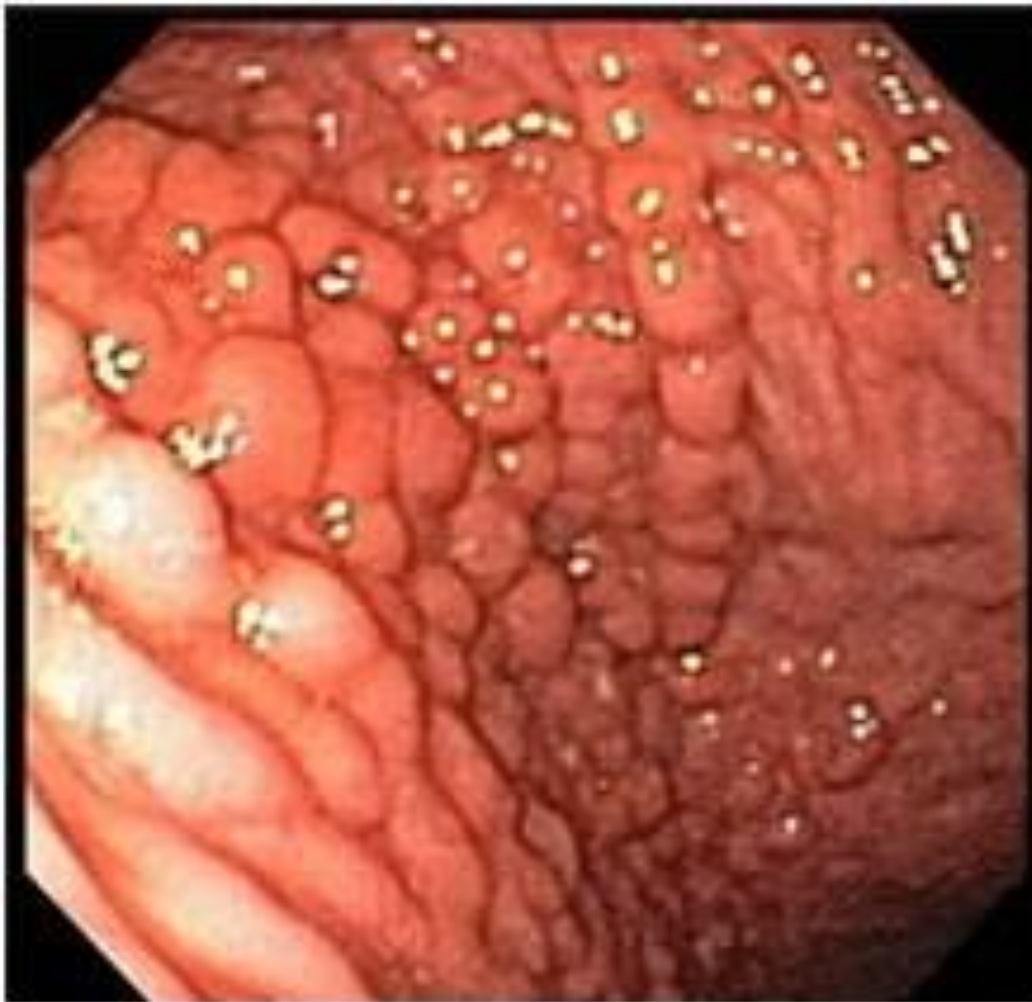Crohn disease of the colon showing a deep fissure extending into the muscle wall, a second, shallow ulcer (upper right), and relative preservation of the intervening mucosa. Abundant lymphocyte aggregates are present, evident as dense blue patches of cells at the interface between mucosa and submucosa

Creeping fat



Cobblestone appearance





[ResearchGate](#)



► Microscopic:

Neutrophils in active disease.

Crypt abscesses.

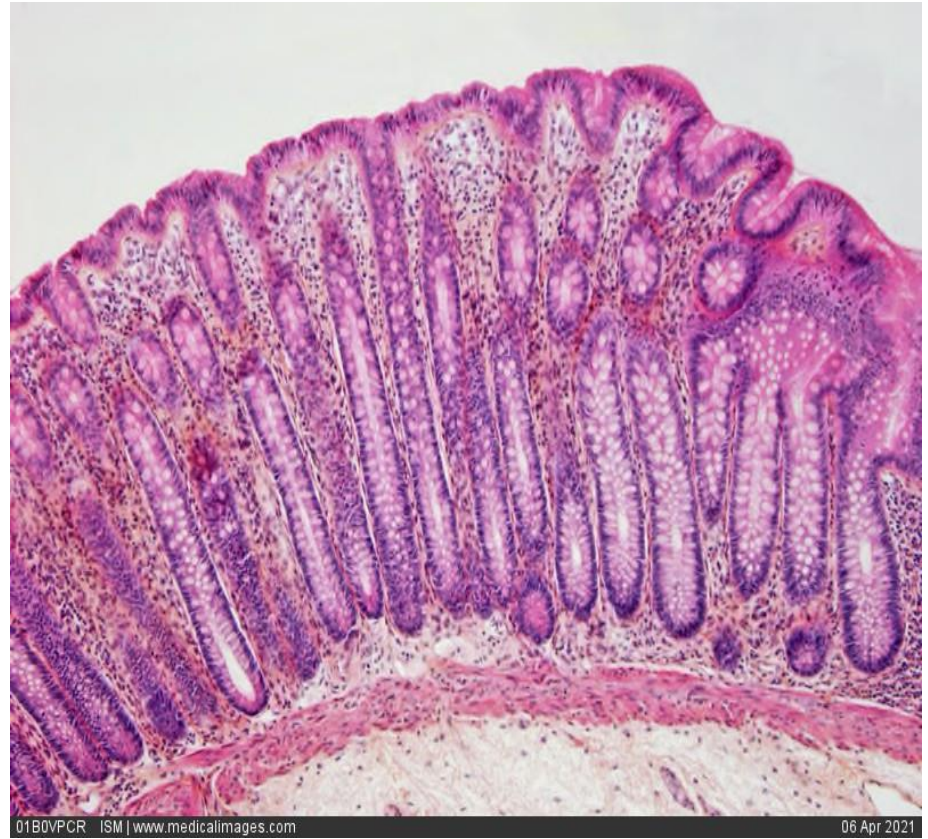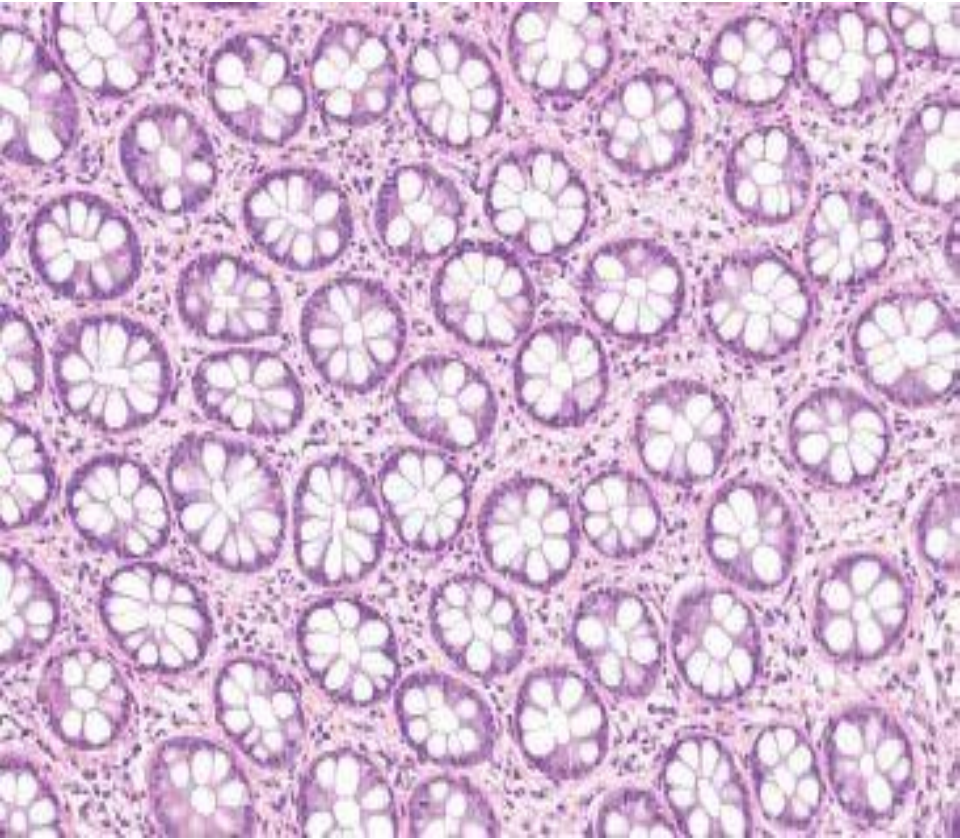
Ulceration.

Distortion of mucosal architecture

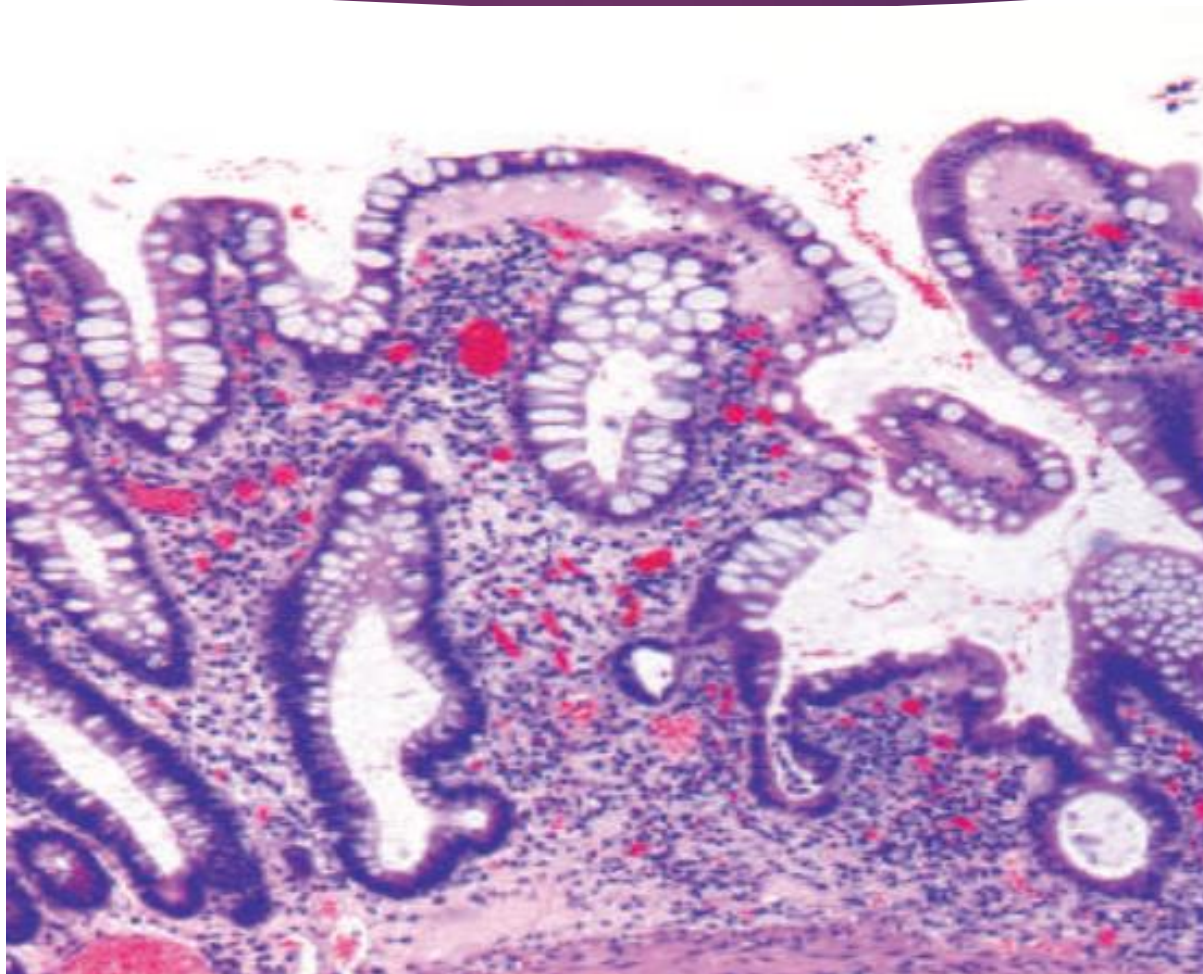
Paneth cell metaplasia in left colon

Mucosal atrophy.

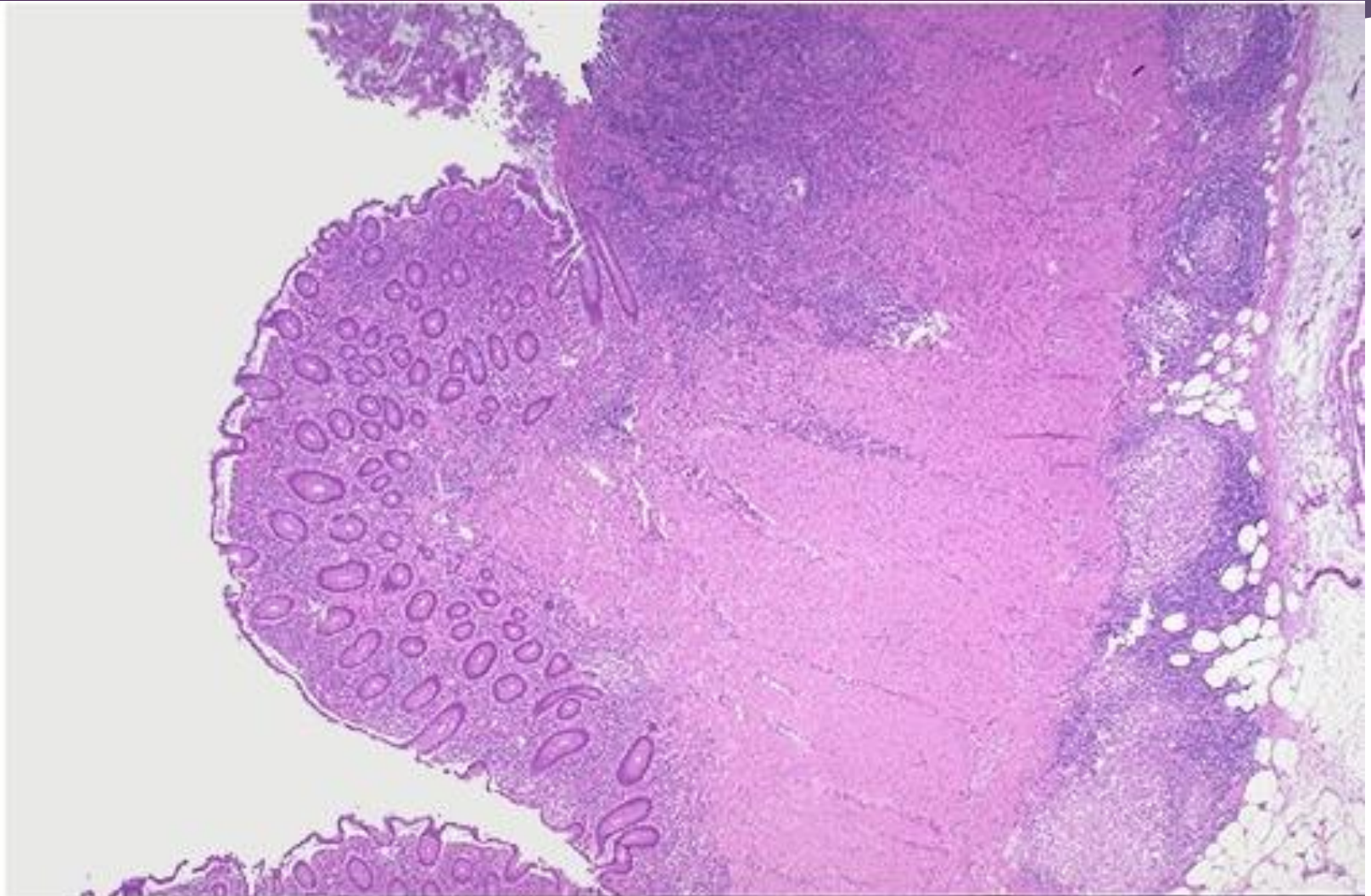
Noncaseating granulomas (hallmark) only in 35% of cases. Where??????



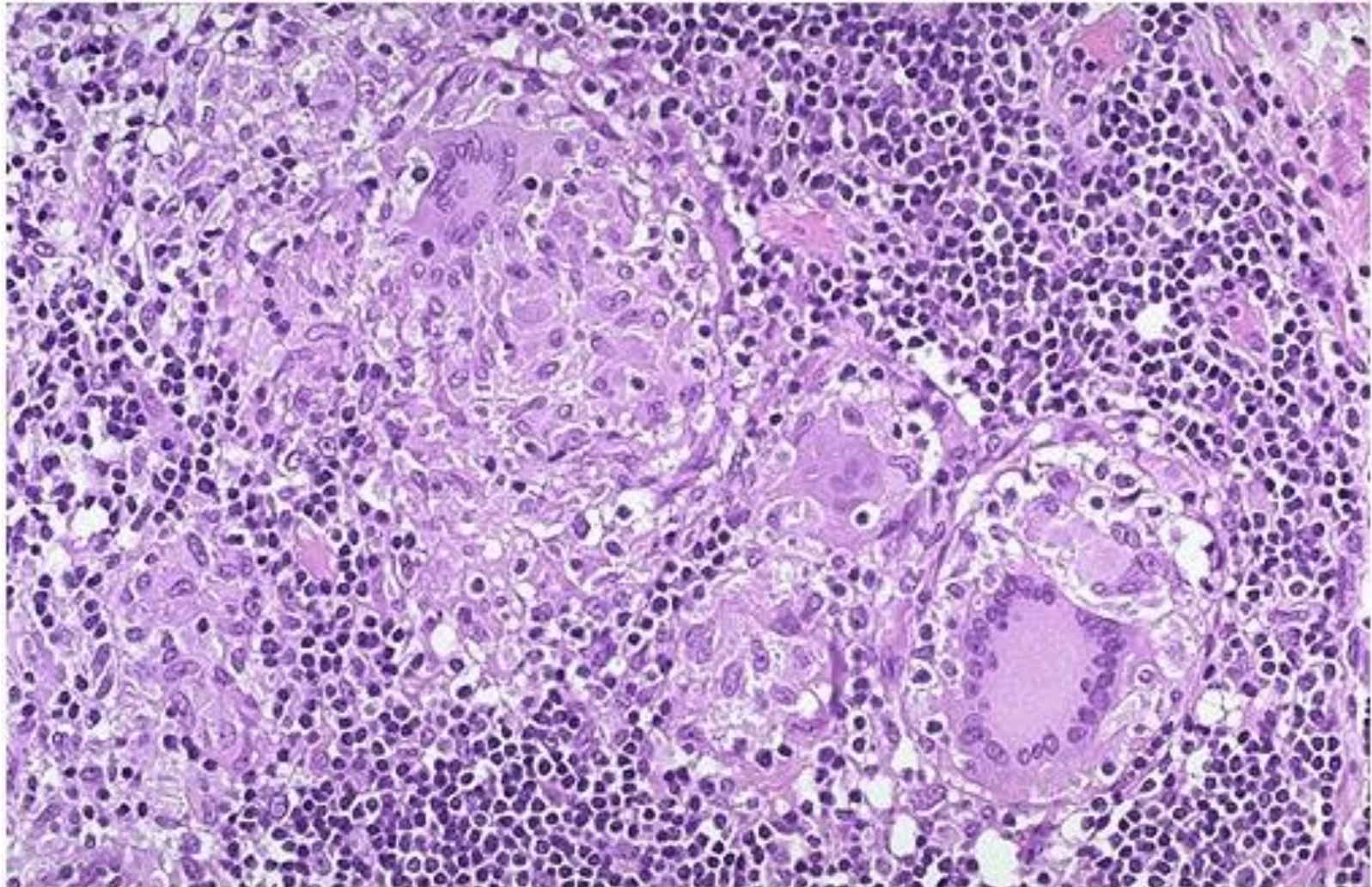
Haphazardly arranged crypts



Transmural inflammation.



Non-caseating granuloma.



Clinical Features

- ▶ Intermittent attacks of mild diarrhea, fever, and abdominal pain.
- ▶ Acute right lower-quadrant pain and fever (20%)
- ▶ Bloody diarrhea and abdominal pain (colonic disease)
- ▶ Asymptomatic intervals (weeks to months)
- ▶ Triggers: physical or emotional stress, specific dietary items, NSAID use, and cigarette smoking.



► Complications:

Iron-deficiency anemia

Hypoproteinemia and hypoalbuminemia,
malabsorption of nutrients, vitamin B12 and bile
salts

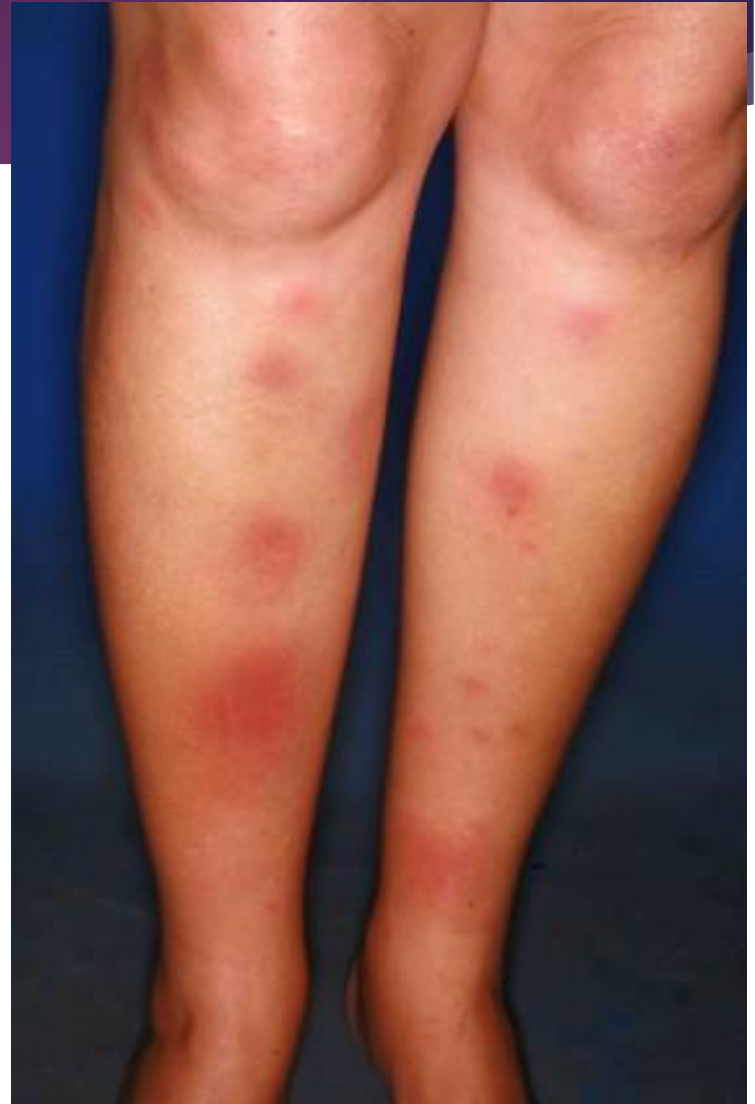Fistulas, peritoneal abscesses, strictures

Risk of colonic adenocarcinoma

Extra intestinal manifestations

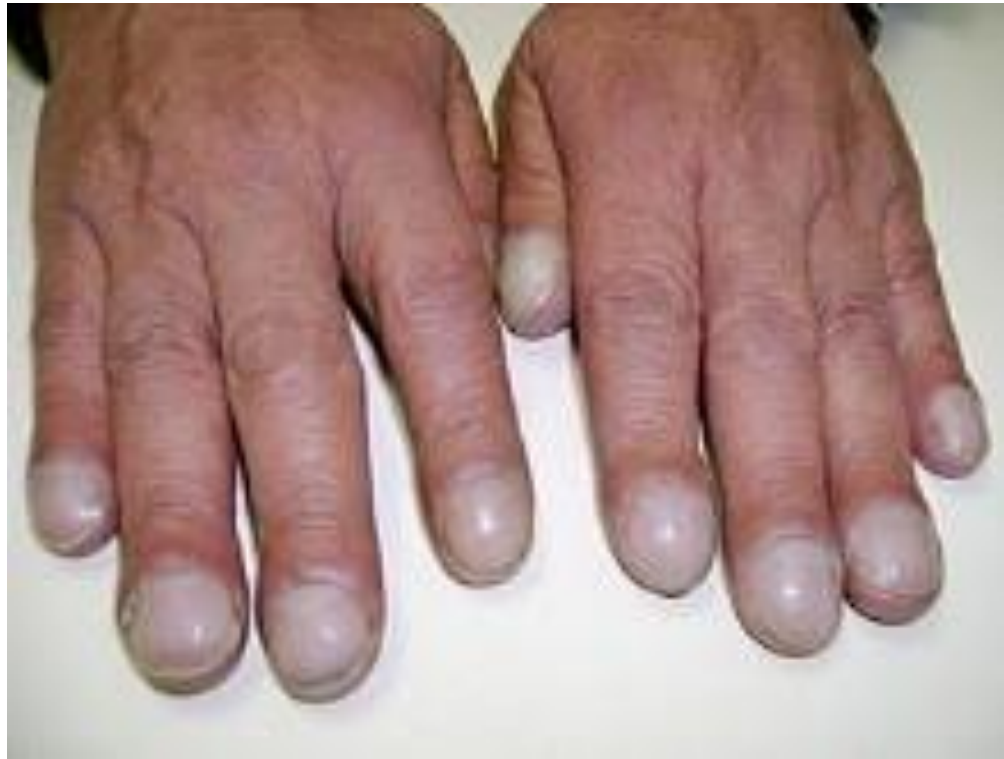- ▶ Uveitis
- ▶ Migratory polyarthritis,
- ▶ Sacroiliitis,
- ▶ Ankylosing spondylitis,
- ▶ Erythema nodosum
- ▶ Clubbing of the fingertips
- ▶ Primary sclerosing cholangitis (more with UC)

Erythema nodosum



Neurology

Clubbing



[Wikipedia](#)

Ulcerative Colitis

Morphology

- ▶ Always involves the rectum
- ▶ Extends proximally in continuous pattern.
- ▶ Pan colitis.
- ▶ Occasionally focal appendiceal or cecal inflammation.
- ▶ Ulcerative proctitis or ulcerative proctosigmoiditis
- ▶ Small intestine is normal (except in backwash ileitis)



► **Macroscopic:**

Broad-based ulcers.

Pseudopolyps

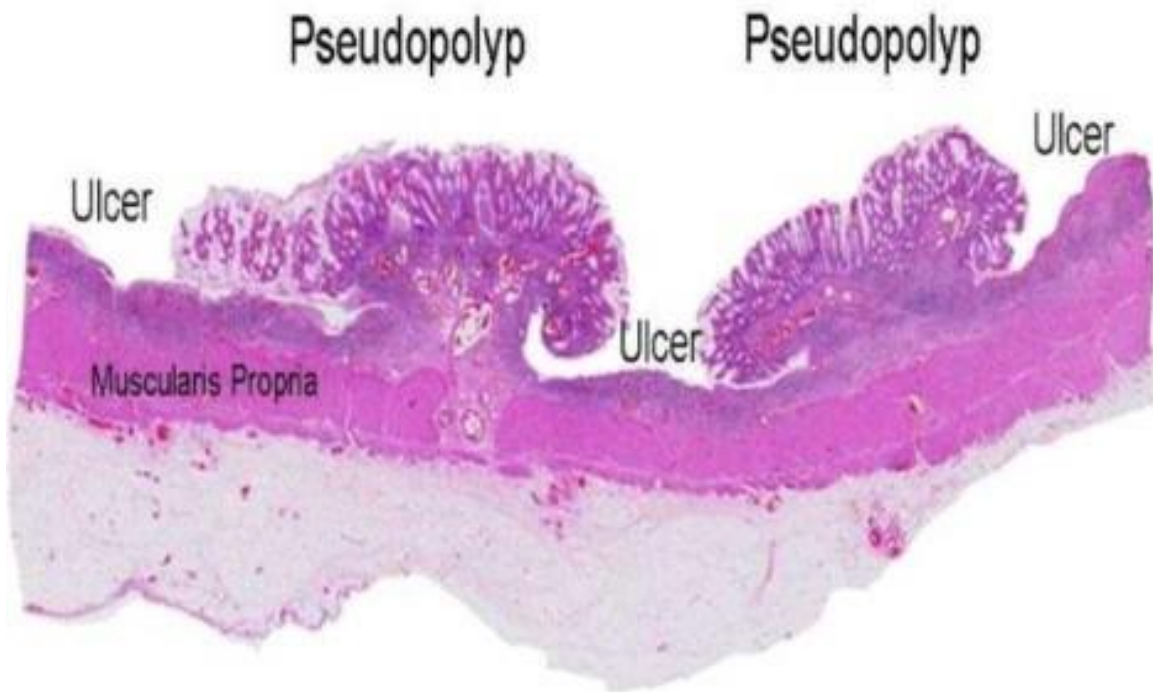
Mucosal atrophy in long standing

Mural thickening absent

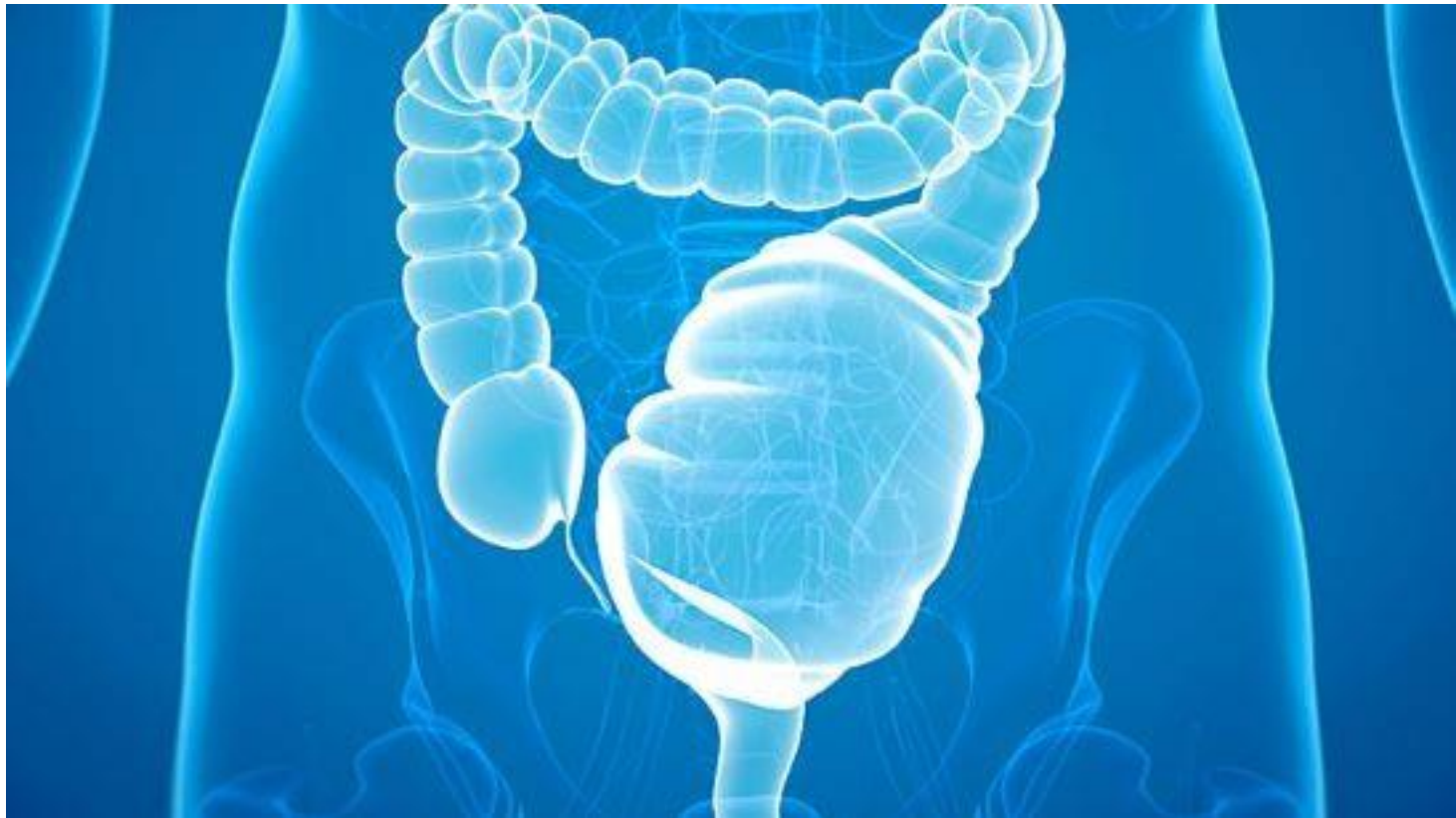Serosal surface normal

No strictures

Toxic megacolon



Toxic megacolon





► Microscopic:

Inflammatory infiltrates

Crypt abscesses

Crypt distortion

Epithelial metaplasia

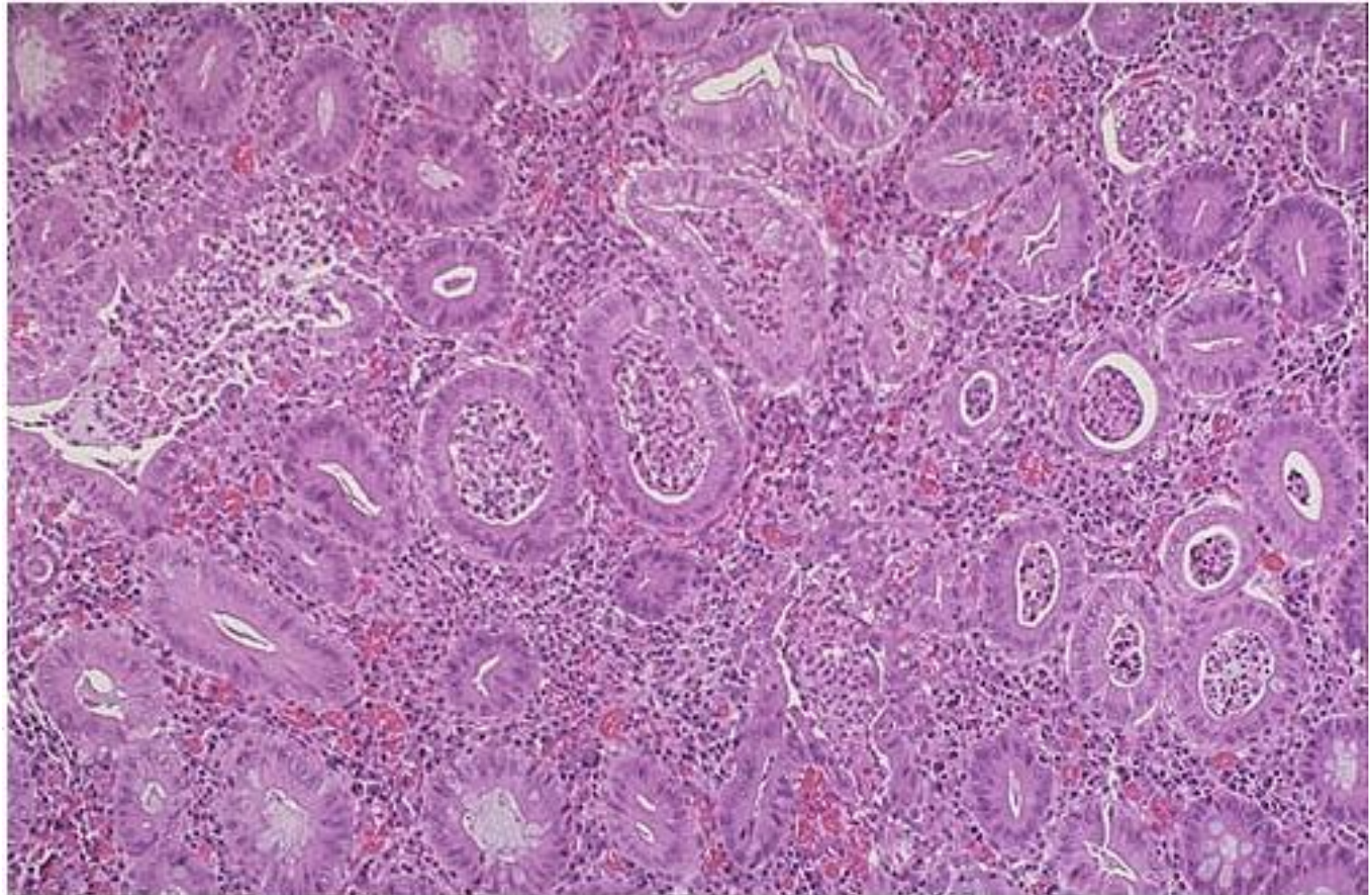
Submucosal fibrosis

\Inflammation limited to mucosa and submucosa.

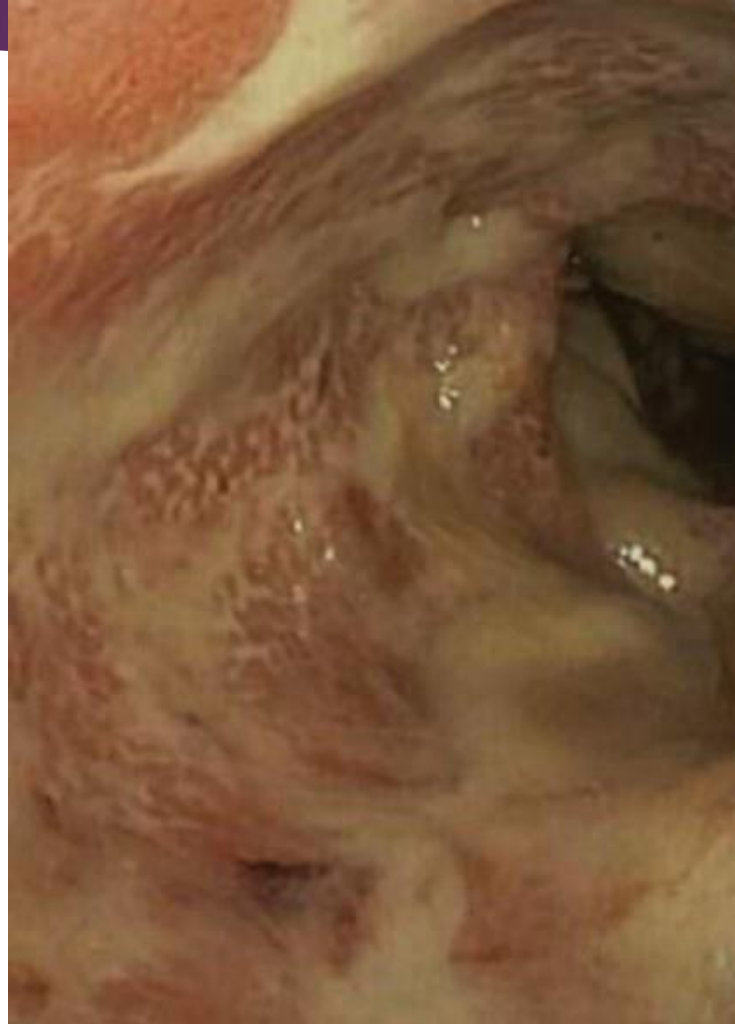No skip lesions

No granulomas.

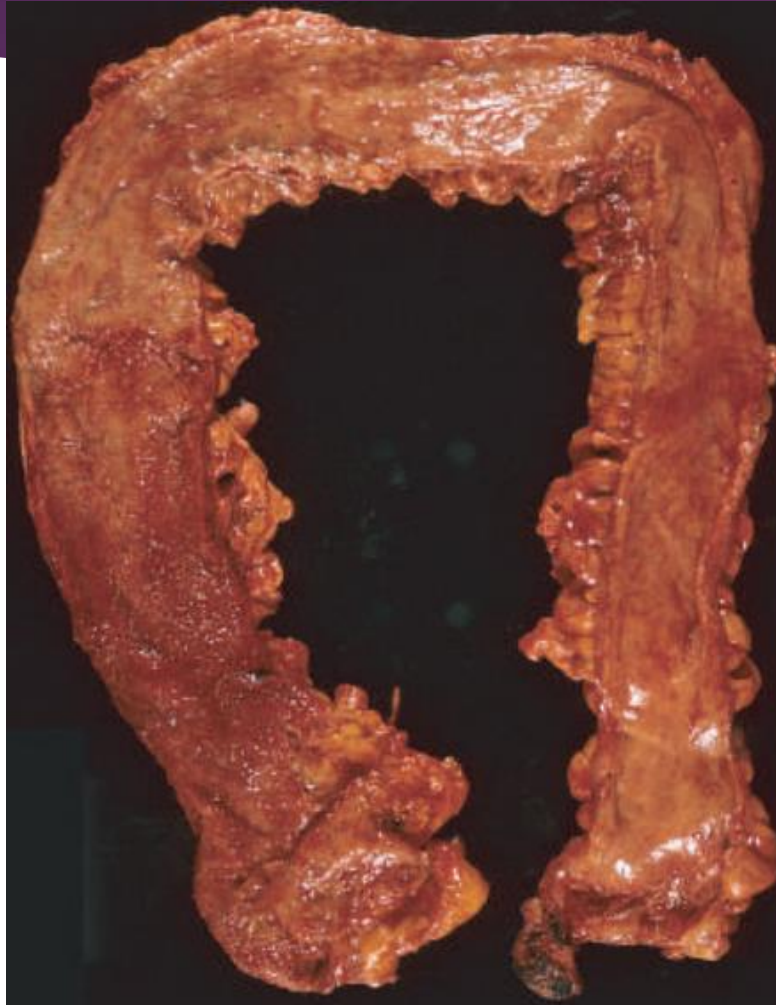Crypt abscesses.



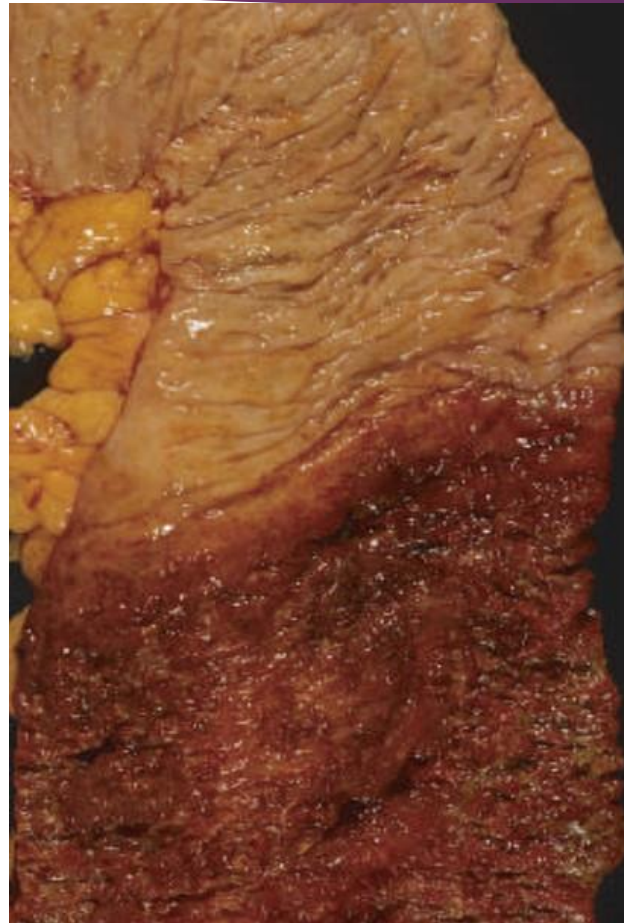Mucopurulent material and
ulcers.



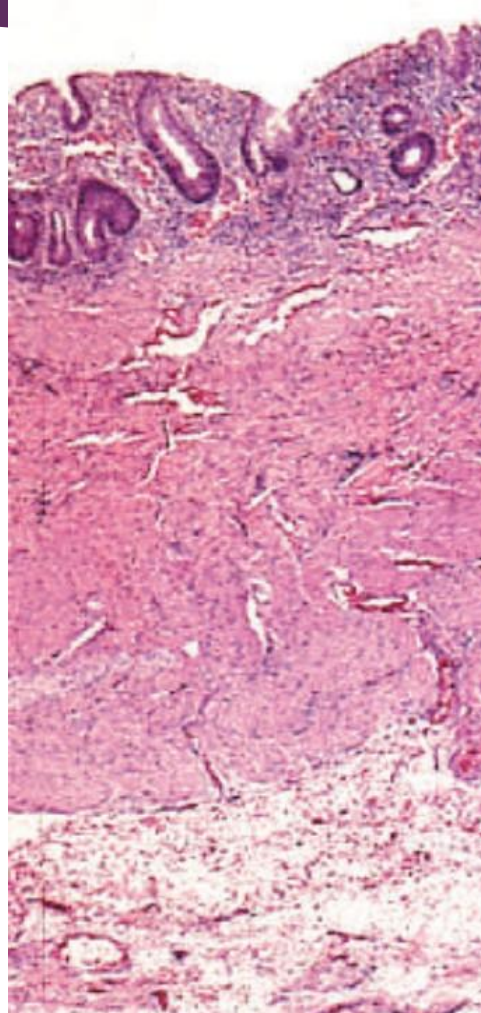
Pancolitis.



Abrupt transition b/w normal
and disease segment.



Limited to mucosa



Clinical Features

- ▶ Relapsing remitting disorder
- ▶ Attacks of bloody mucoid diarrhea +lower abdominal cramps
- ▶ Temporarily relieved by defecation
- ▶ Attacks last for days, weeks, or months.
- ▶ Asymptomatic intervals.
- ▶ Infectious enteritis may trigger disease onset, or cessation of smoking.
- ▶ Colectomy cures intestinal disease only

Feature	Crohn Disease	Ulcerative Colitis
Macroscopic		
Bowel region affected	Ileum ± colon	Colon only
Rectal involvement	Sometimes	Always
Distribution	Skip lesions	Diffuse
Stricture	Yes	Rare
Bowel wall appearance	Thick	Thin
Inflammation	Transmural	Limited to mucosa and submucosa
Pseudopolyps	Moderate	Marked
Ulcers	Deep, knifelike	Superficial, broad-based
Lymphoid reaction	Marked	Moderate
Fibrosis	Marked	Mild to none
Serositis	Marked	No
Granulomas	Yes (~35%)	No
Fistulas/sinuses	Yes	No

Feature	Crohn Disease	Ulcerative Colitis
Clinical		
Perianal fistula	Yes (in colonic disease)	No
Fat/vitamin malabsorption	Yes	No
Malignant potential	With colonic involvement	Yes
Recurrence after surgery	Common	No
Toxic megacolon	No	Yes

NOTE: Not all features may be present in a single case.

Colitis-Associated Neoplasia

- ▶ Long standing UC and CD.
- ▶ Begins as dysplasia >>>> carcinoma.
- ▶ **Risk depends on**
 - ▶ **Duration of disease:** increase after 8-10 years .
 - ▶ **Extent of involvement:** more with pancolitis.
 - ▶ **Inflammation:** frequency and severity of active disease with neutrophils.