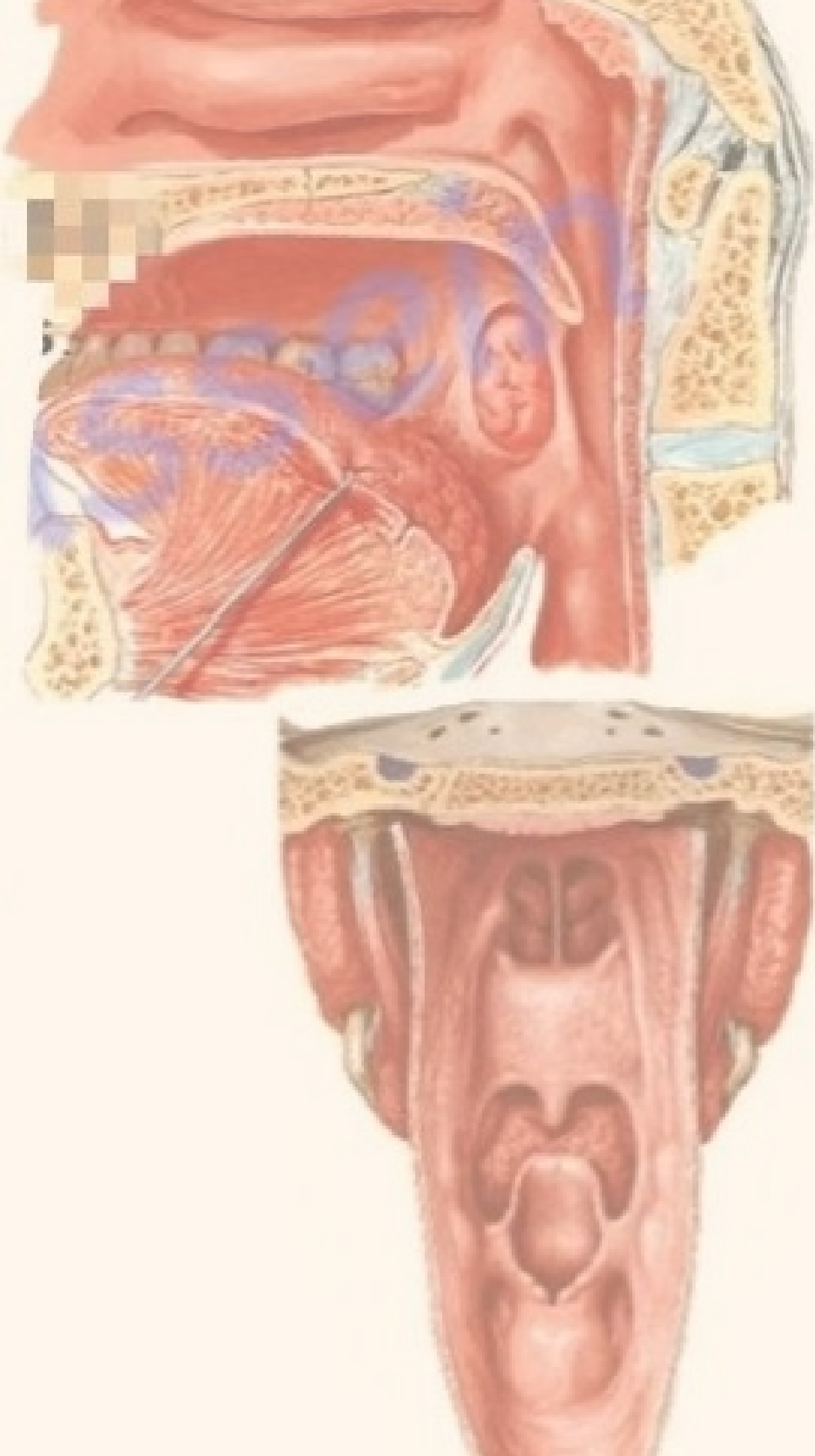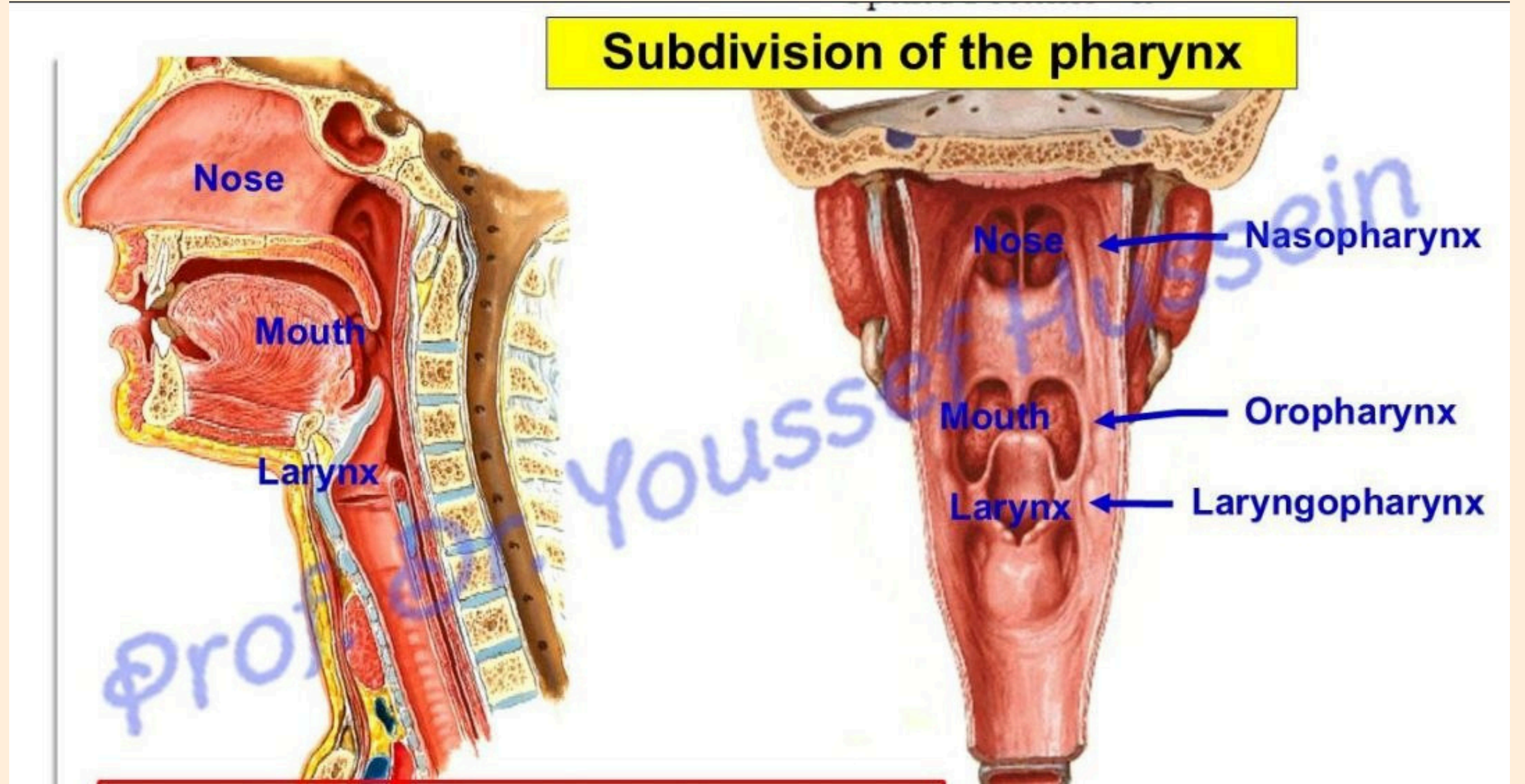
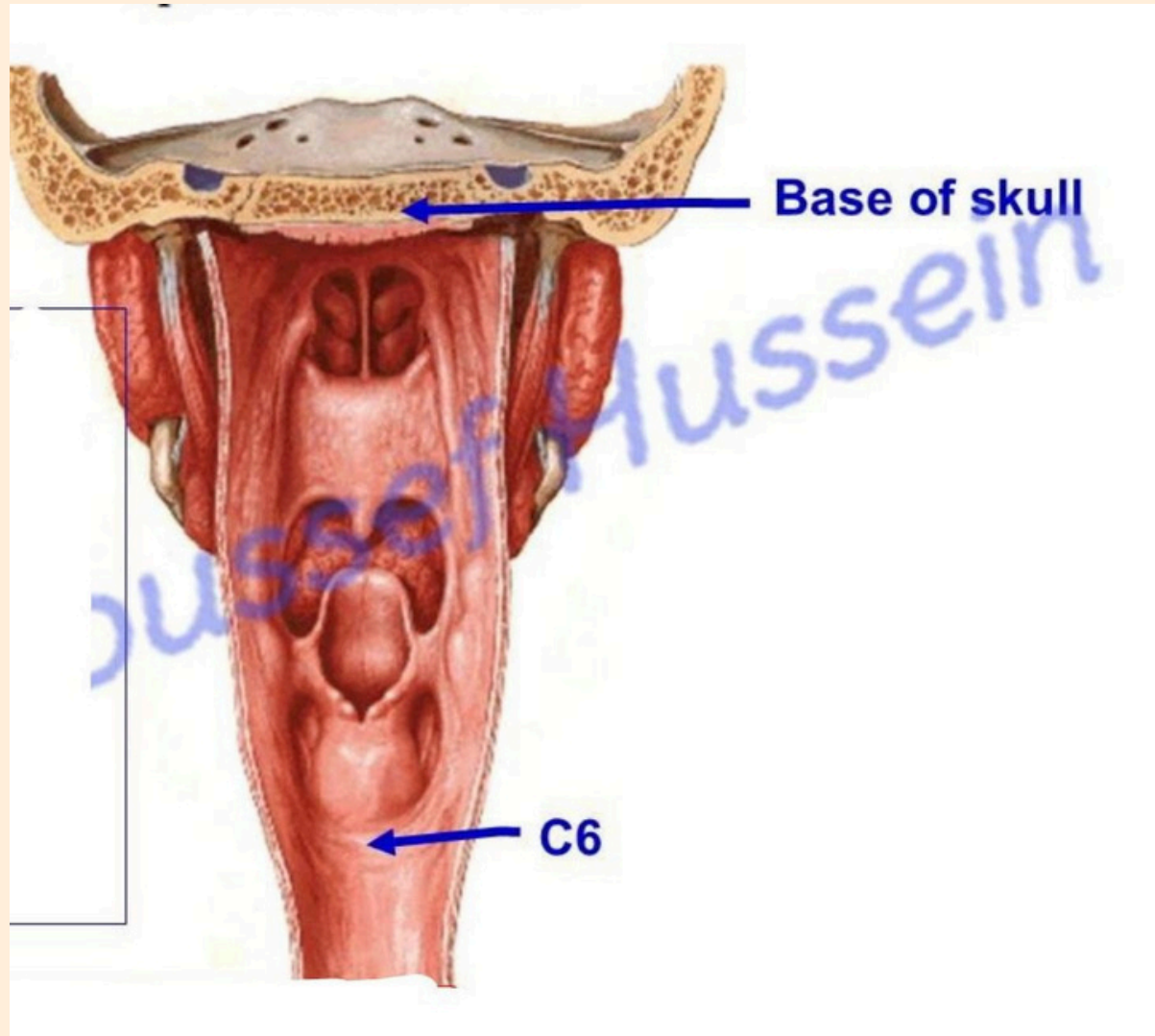



Anatomy

LAB 5





Posterior border of
Medial pterygoid plate

Pterygoid Hamulus

Pterygomandibular
ligament

**Posterior end of
mylohyoid line**

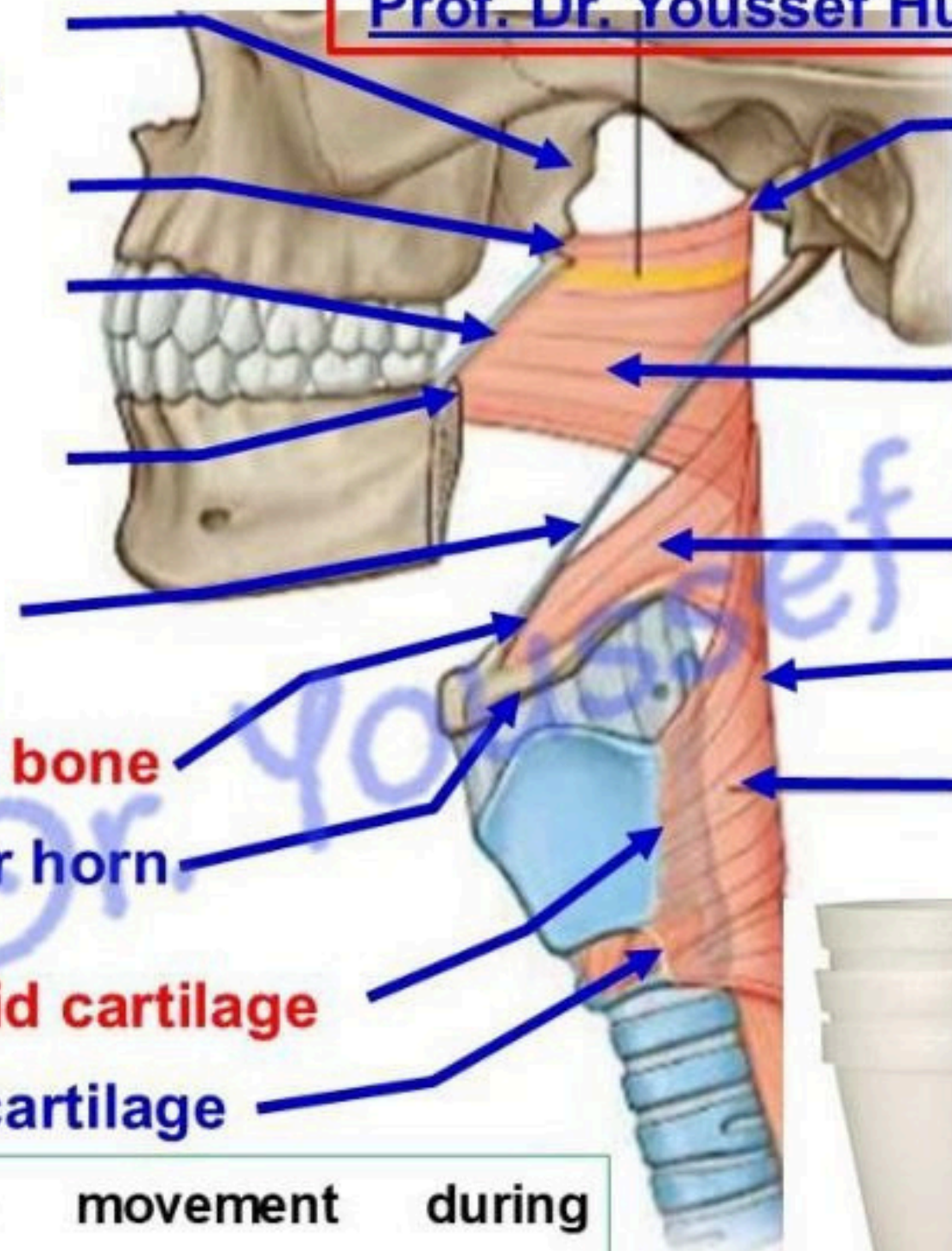
Lower part of
Stylohyoid ligament

Lesser horn of hyoid bone

Upper part of Greater horn
of hyoid bone

Oblique line of thyroid cartilage

Side of cricoid cartilage



Pharyngeal tubercle

Superior constrictor

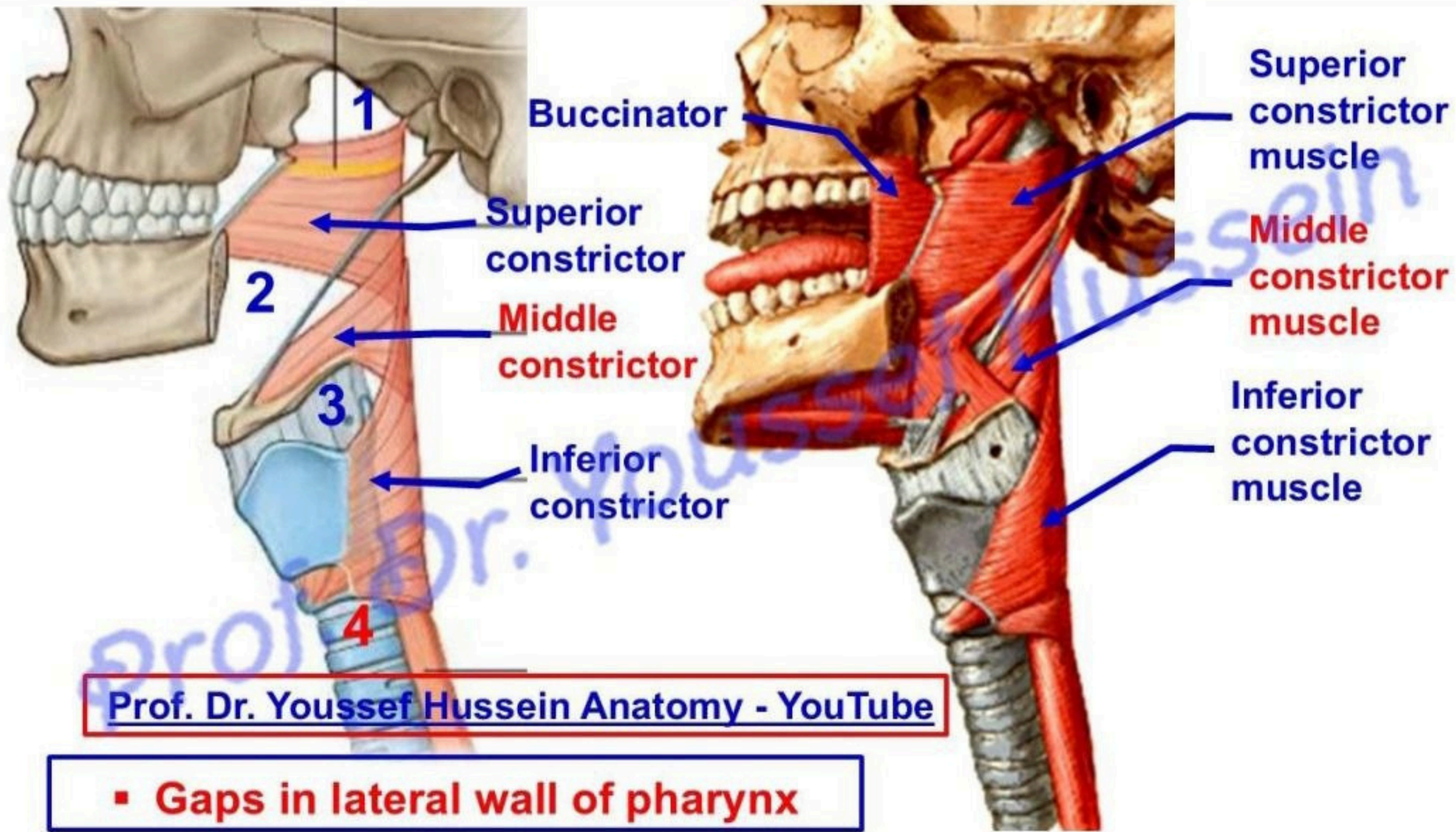
Middle constrictor

Pharyngeal Raphe

Inferior constrictor

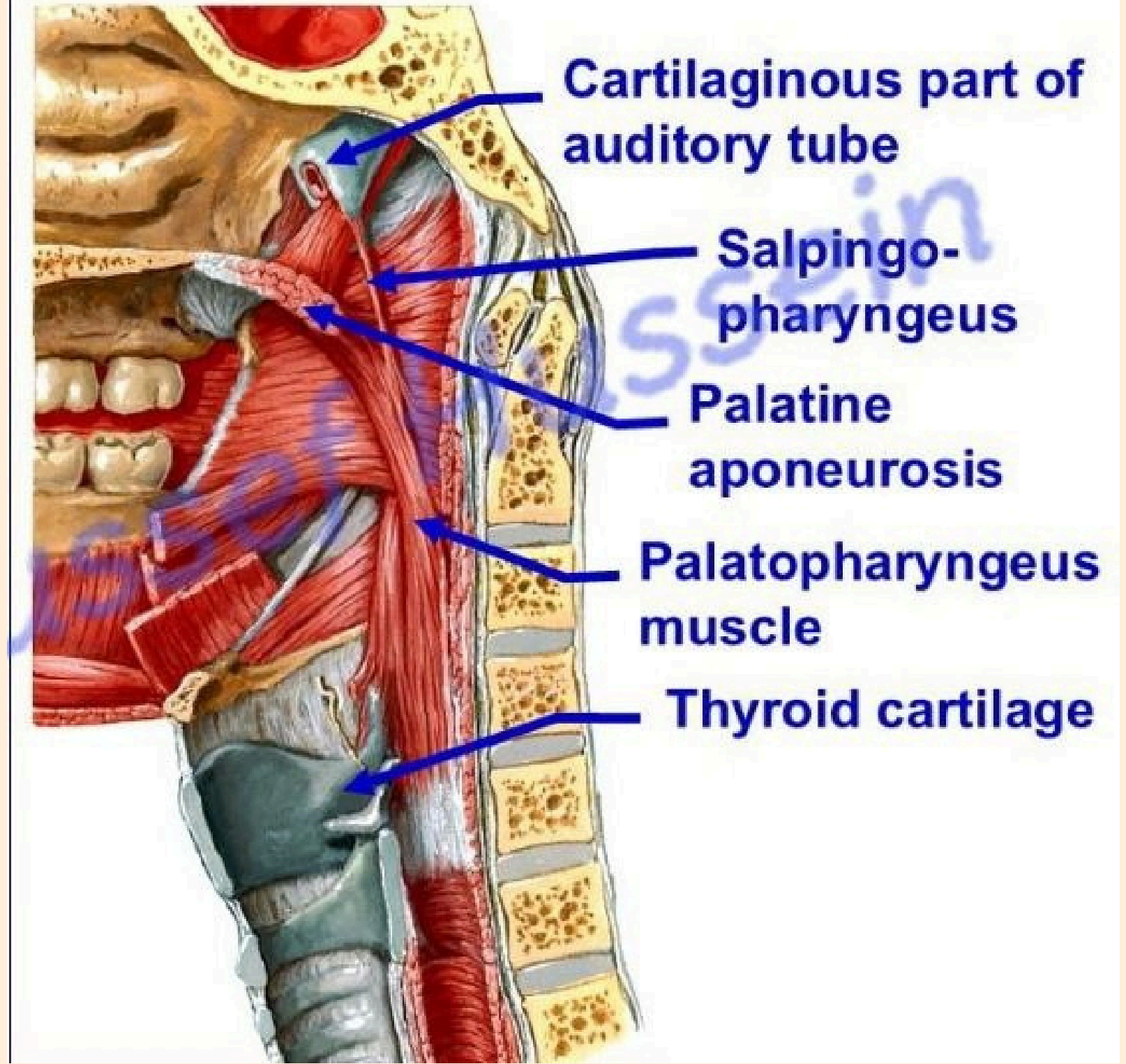
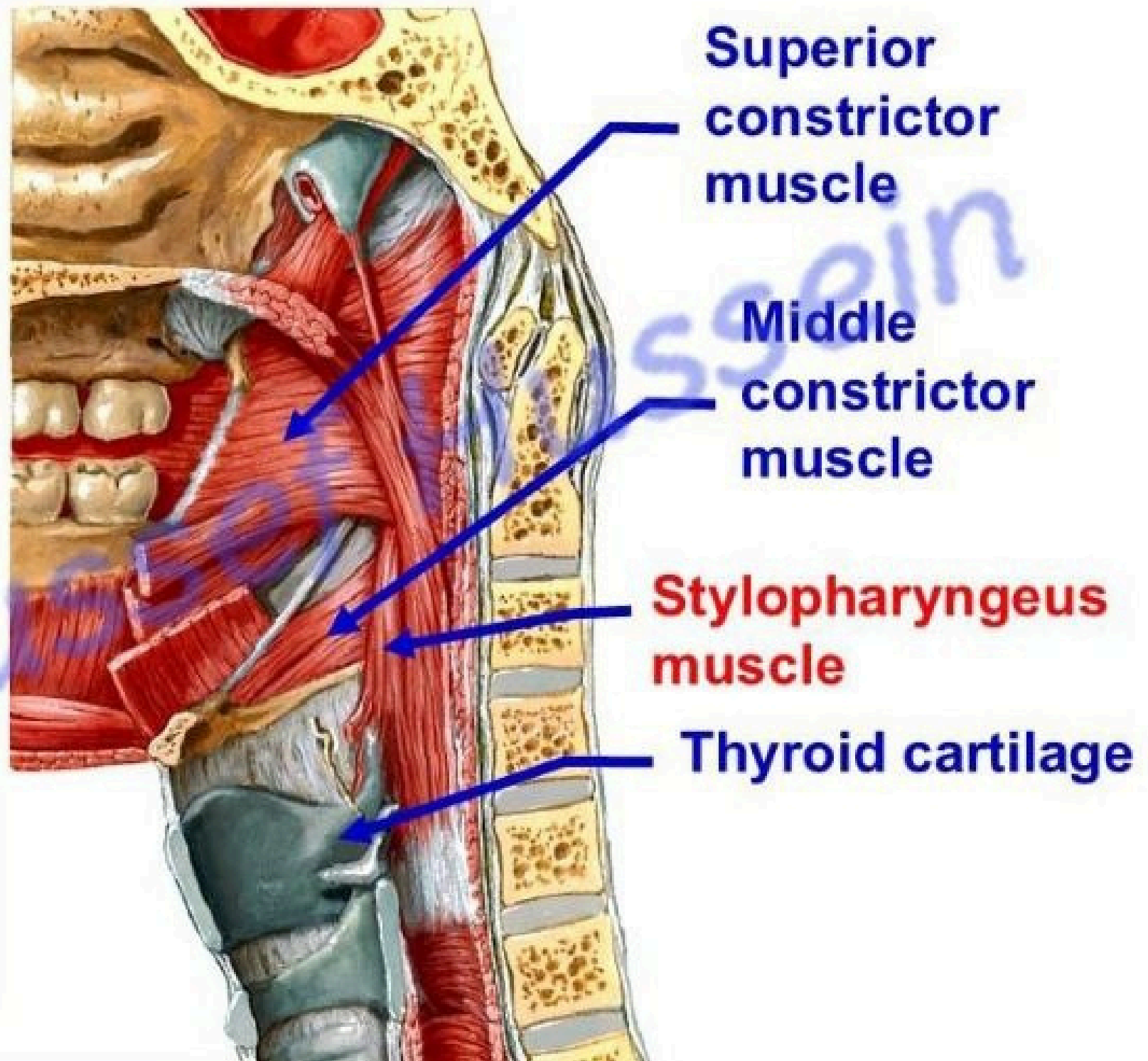
Insertion: into a median fibrous pharyngeal raphe extending from the pharyngeal tubercle of base of skull to the cricoid cartilage below.

- Actions, peristaltic movement during swallowing.

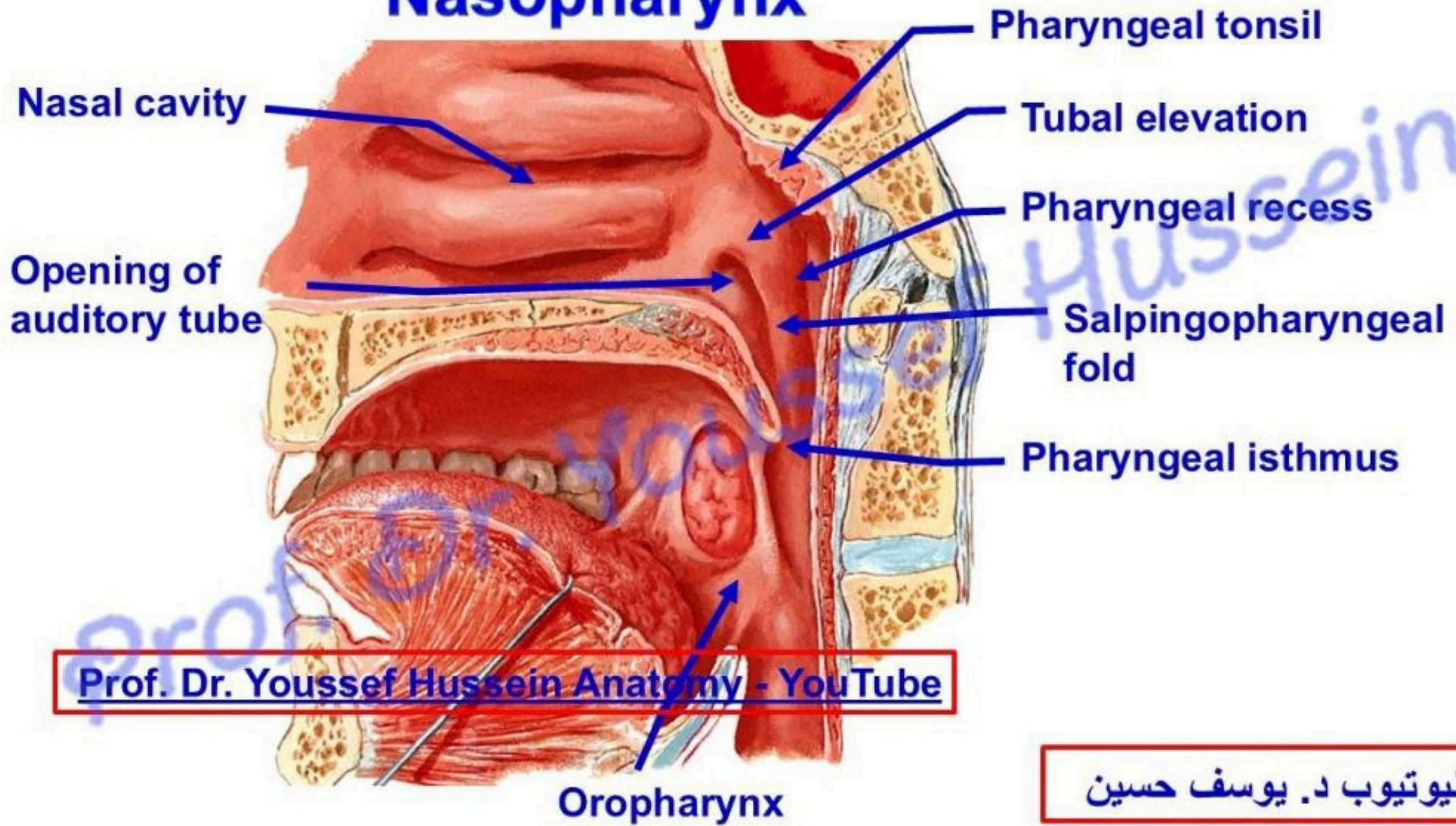


Prof. Dr. Youssef Hussein Anatomy - YouTube

▪ Gaps in lateral wall of pharynx

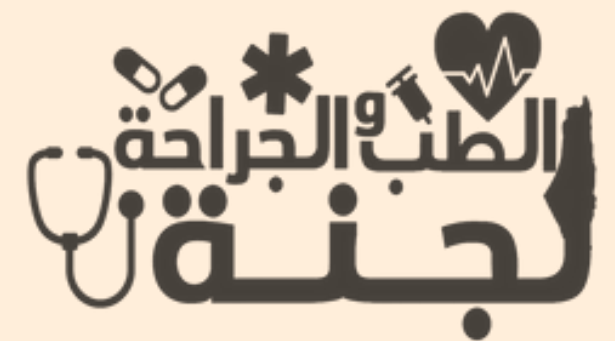

Nasopharynx

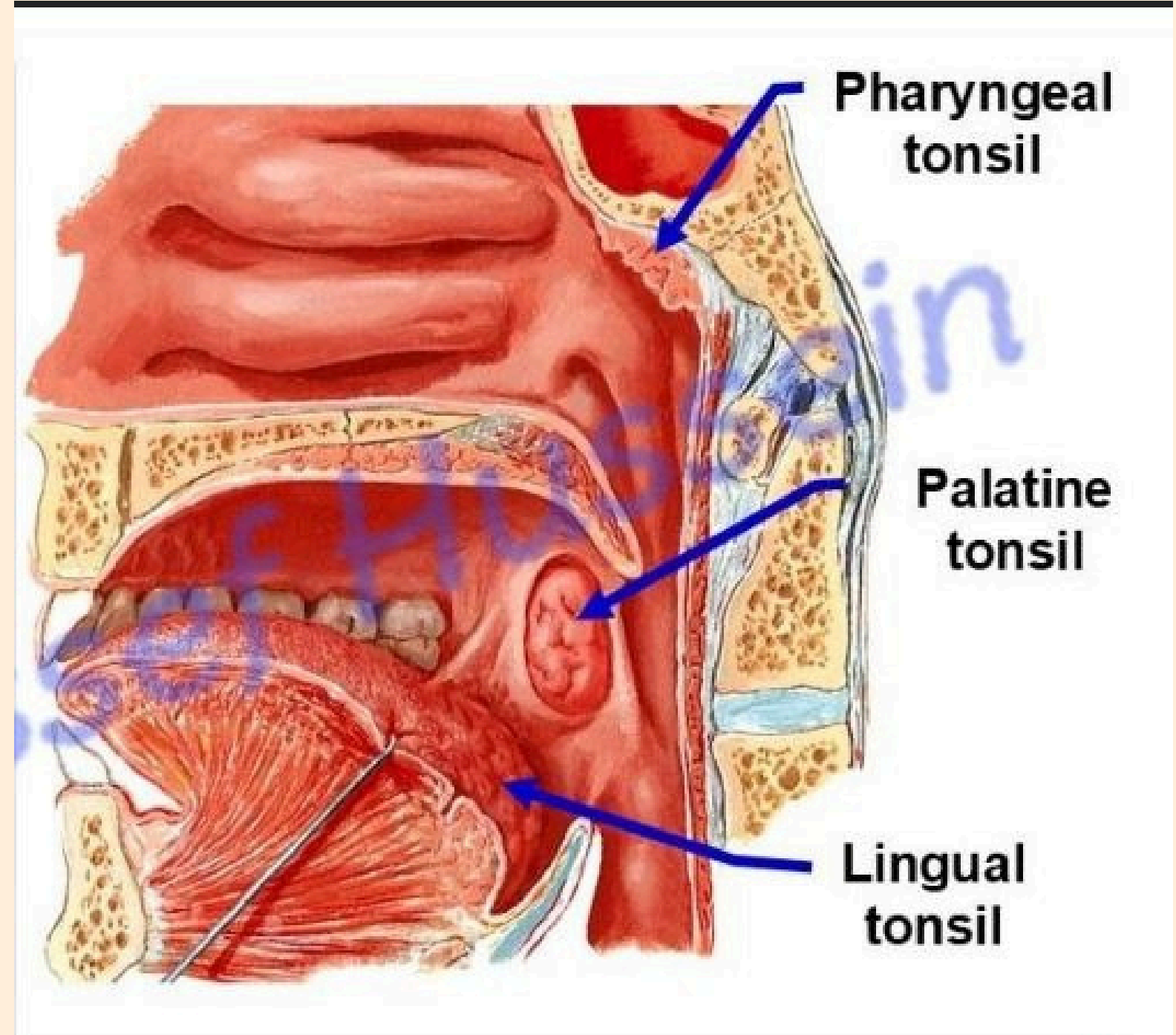
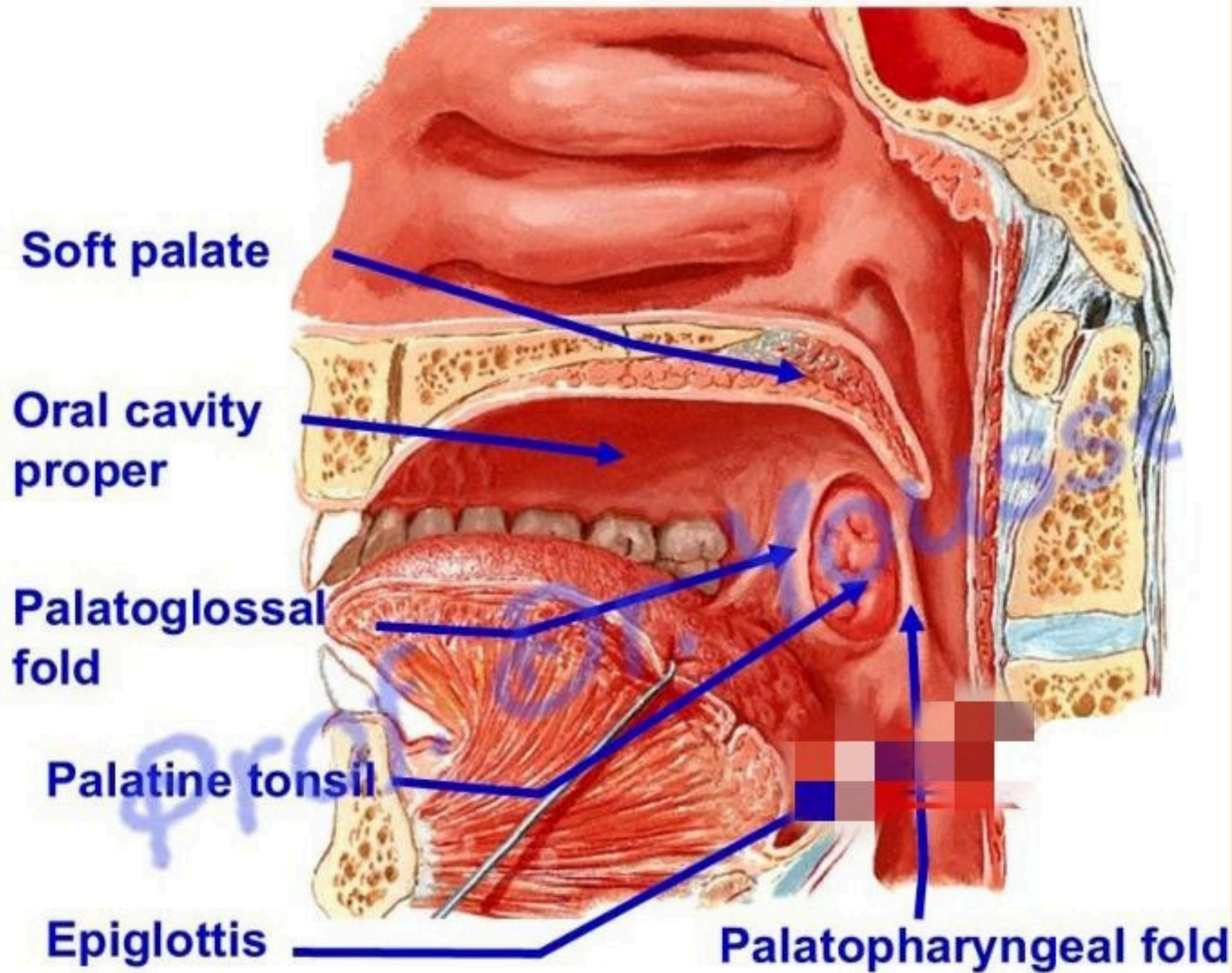


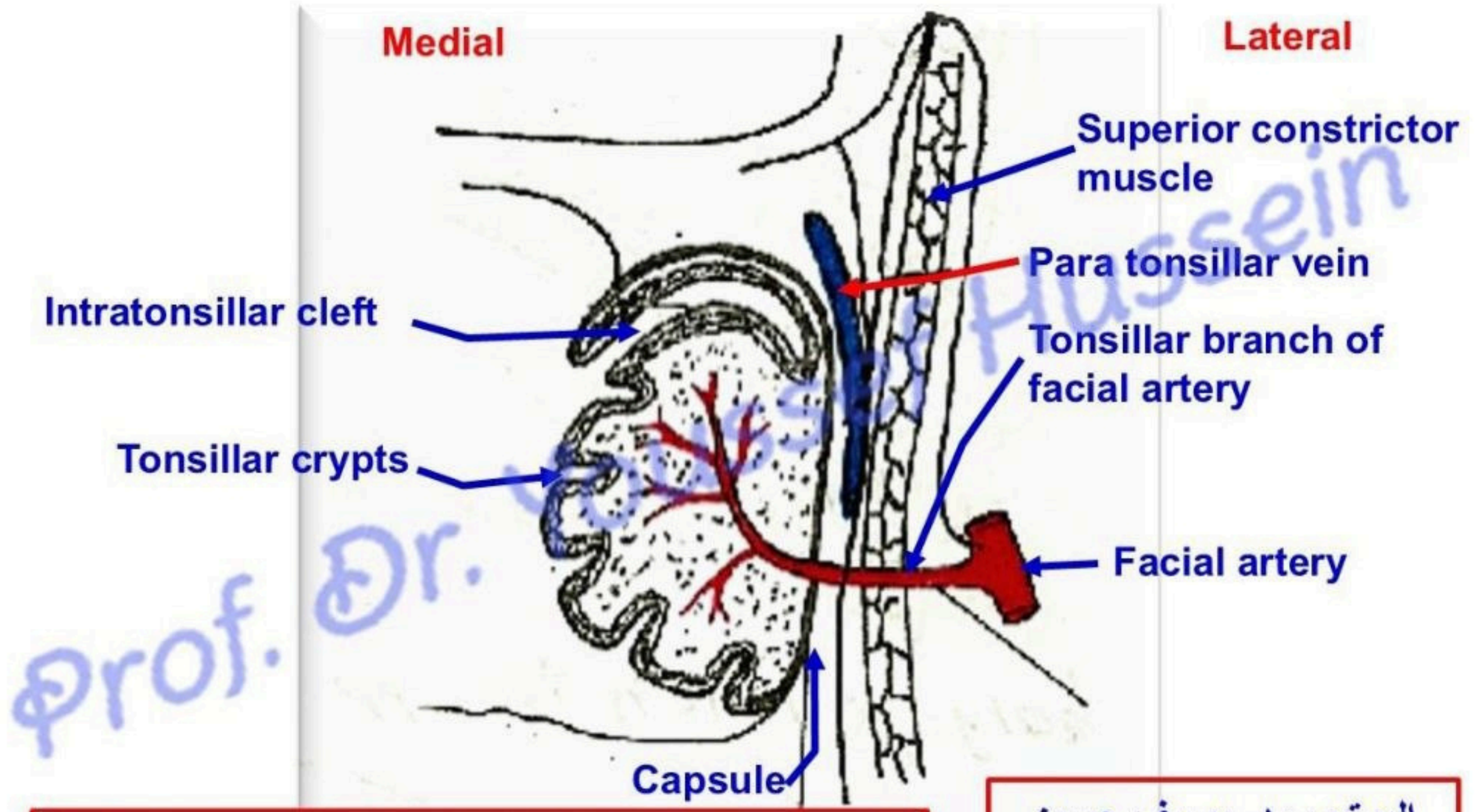
Prof. Dr. Youssef Hussein Anatomy - YouTube

اليوتيوب د. يوسف حسين



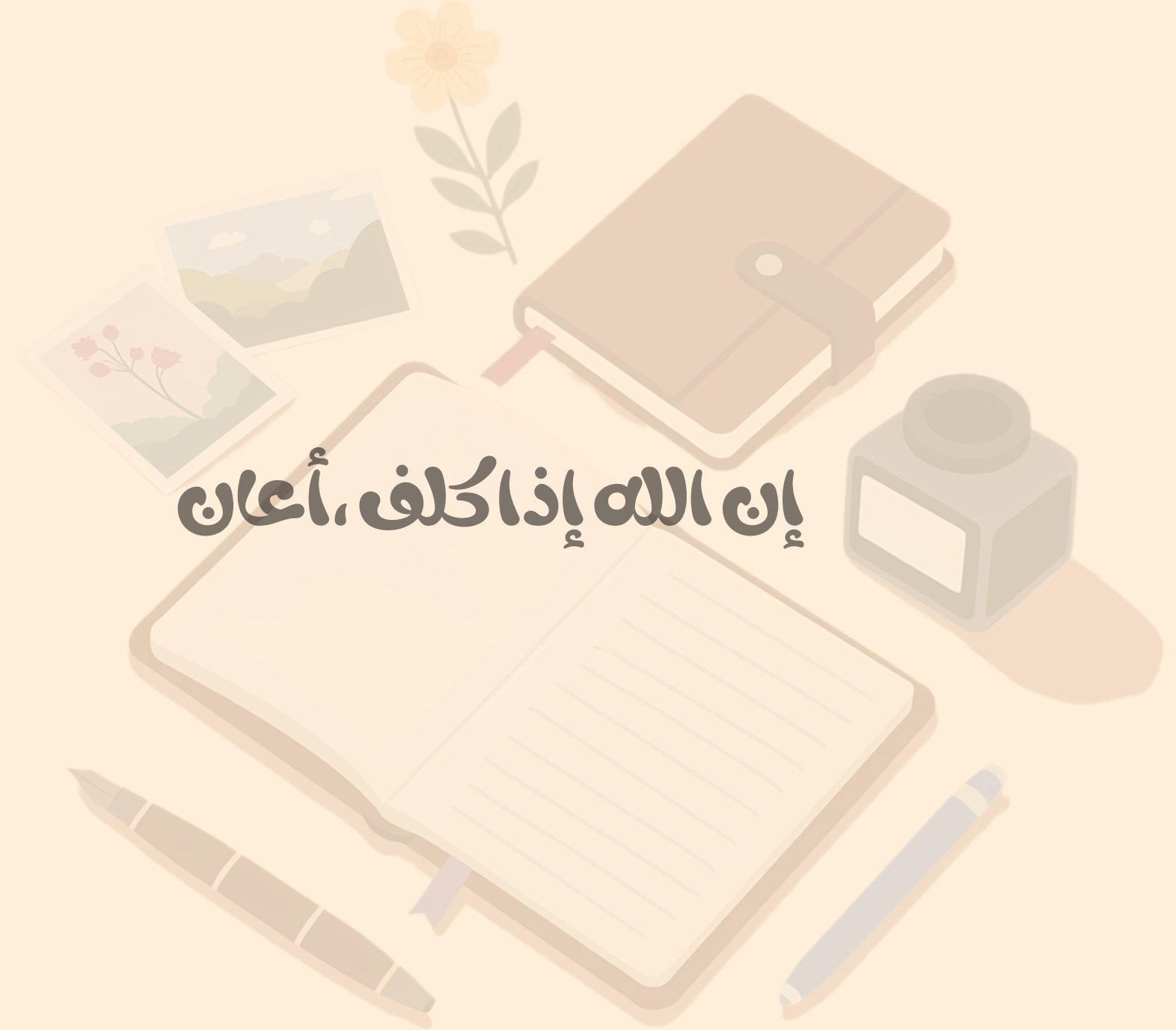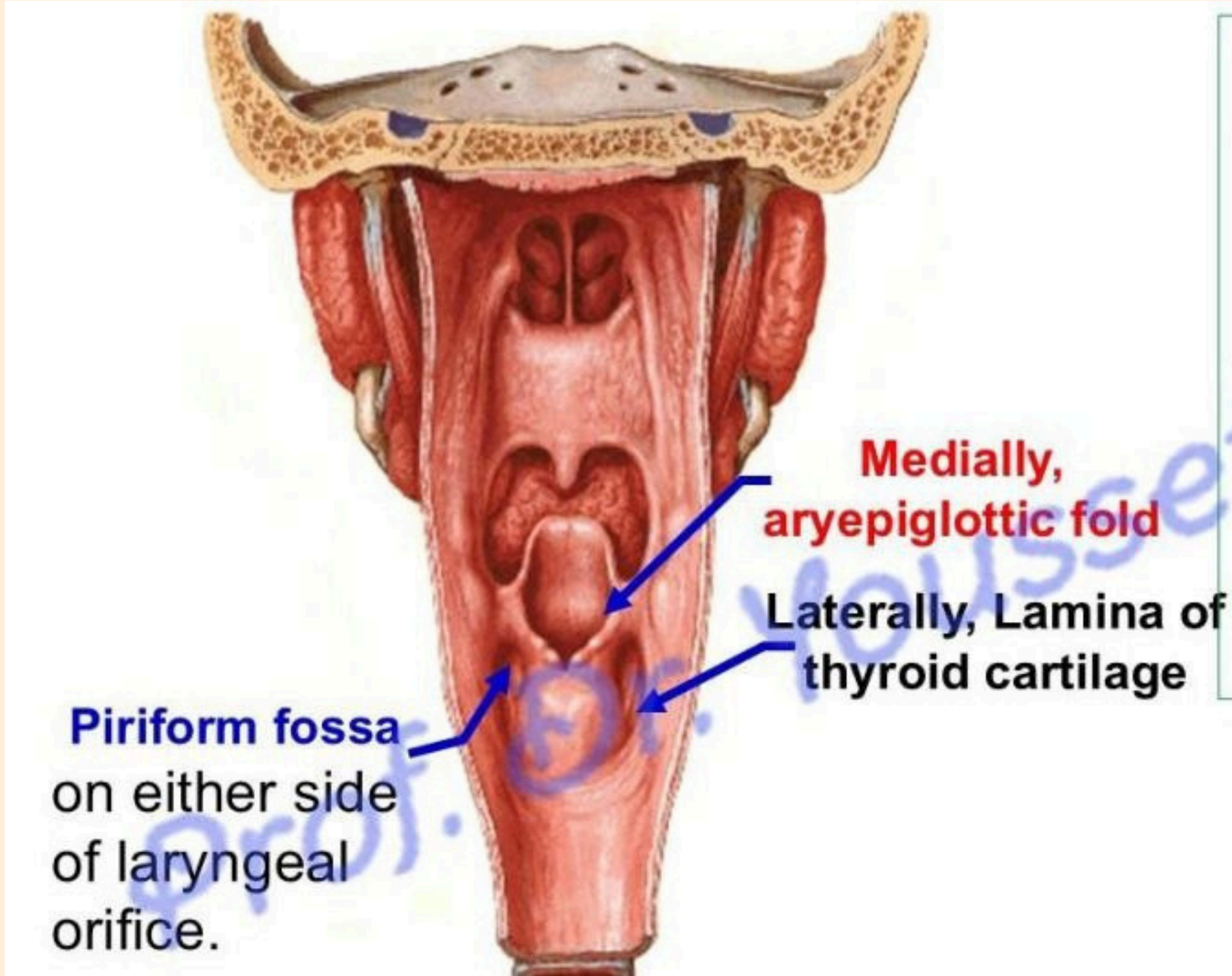
Oropharynx



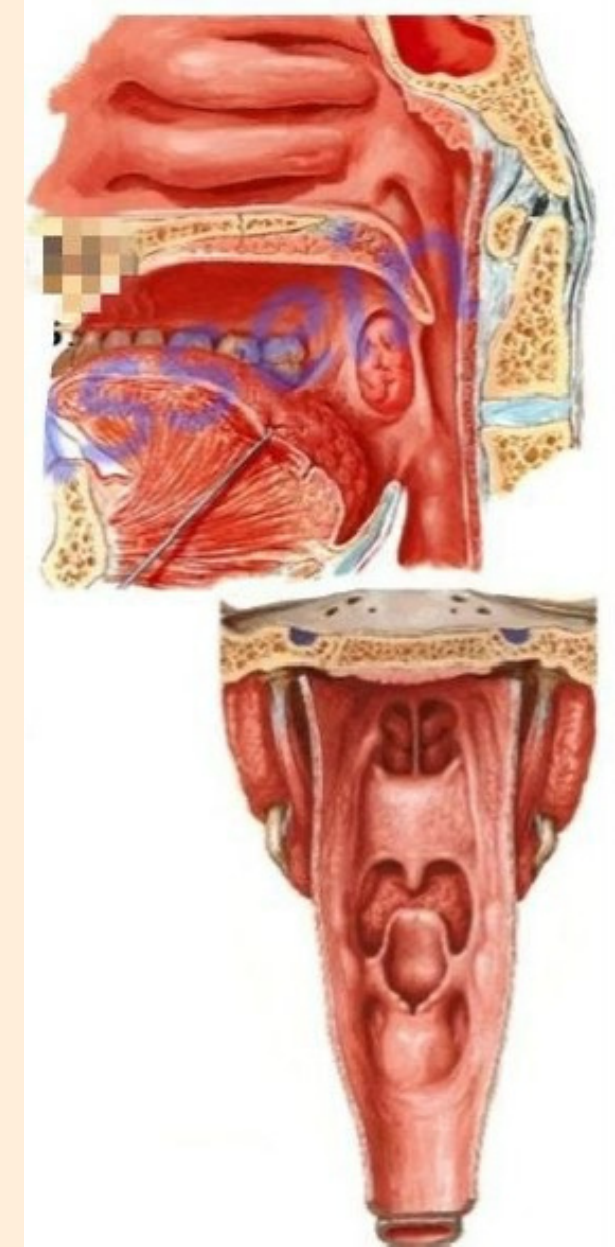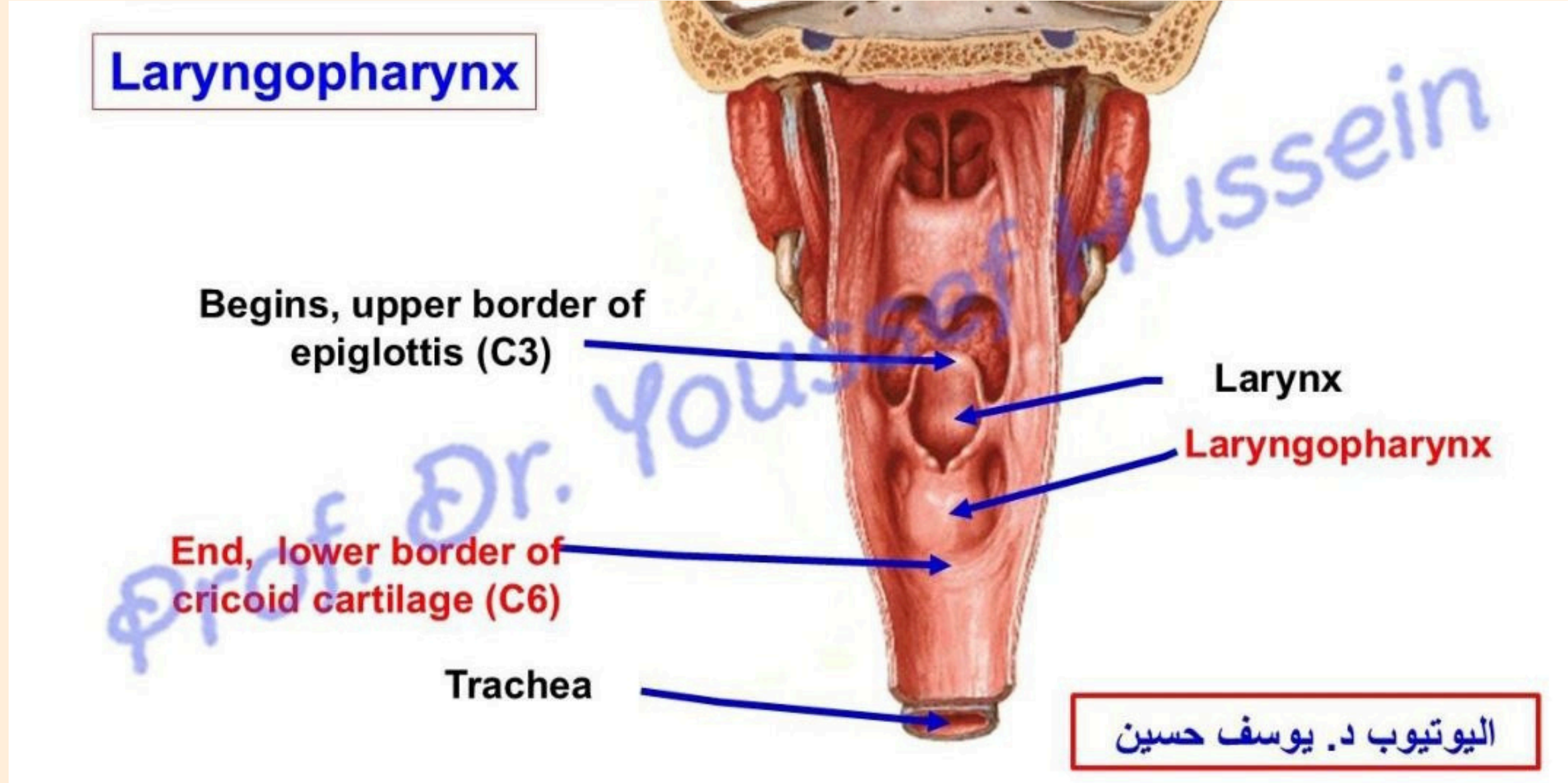
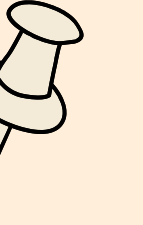


[Prof. Dr. Youssef Hussein Anatomy - YouTube](https://www.youtube.com/channel/UC...)

اليو تيوب د. يوسف حسين



ملاحظة هذه الصور ضمن سلايدات لم يطالب الدكتور بها



بالتوفيق... لا تنسونا من صالح دعائكم

الطب الجراحة
لجنة