patient with dendritic ulcer, and recurrent stomatitis, what is the least likely cause of the recurrence of ulcer?

topical steroids
systemic steroids
topical antibiotics
UV Light
Concurrent with systemic disease

child presents with eyelid laceration, what i your management?

Refer to ophthalmologist

All can cause cicatricial conjunctivitis except?

bullous pemphoid
Stevens Johnson syndrome
chemical burn
trachoma
bacterial conjunctivitis

Q18) The patient can't read and climp down the stairs , the affected gaze is :

A. upward paralysis
B. downward
C. horizontal
D. vertical
E. mixed

ANSWER : B

Q16) Patient presented with blurry vision , diagnosed with cataract , surgery was performed , all of the following are complication of cataract surgery except :

A. vitrous loss
B. glucoma
C. retinablastoma
D. astigmatism
E. endophthalamitis

ANSWER : C

Q9) A female patient presented woth this sign , CT imaging shows thickened extraoccular muscles , the most likely cause of her condition :

ANSWER : dysthyroid disease

(MCQ)

Q17) All of the following can cause cataract except :

A. trauma
B. DM
C. mixed astigmatism
D. uveitis
E. chemotherapy

ANSWER : C

Q4) a 66 years old male patient with history of HTN presented with sudden onset visual loss in the right eye , the best corrected visual acuity in the left eye was 6/6 and in the right eye no light perception , the fundoscopic examination revealed the following sign , what's the most likely cause of this case ?

ANSWER : central retinal artery occlusion

(written)

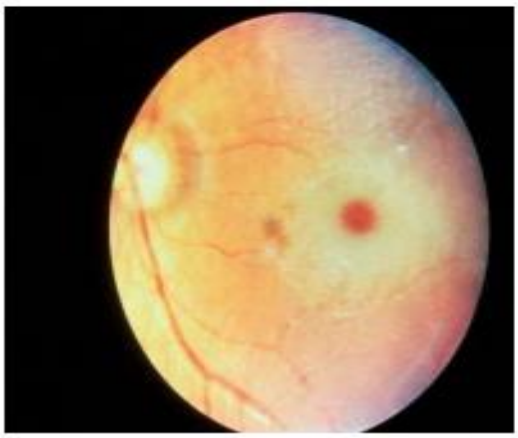

Diagnosis(mcq)
Keratoconus

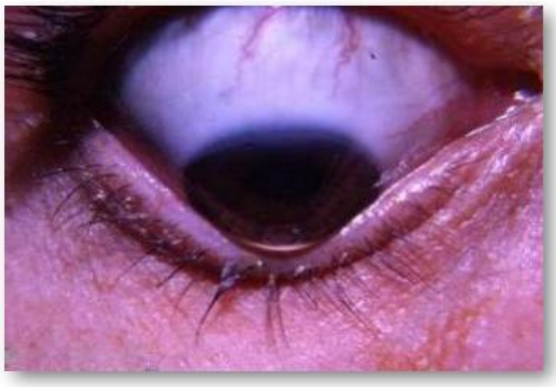

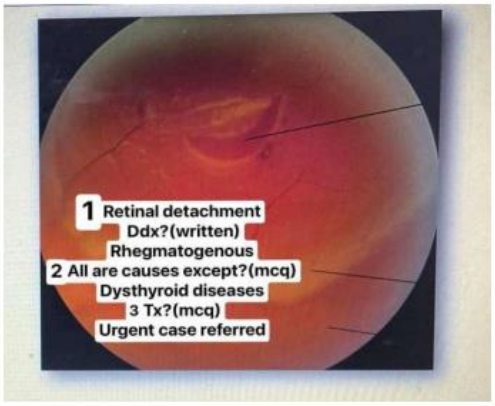

MCQ

ما بنقدر نحدد اذا صح او لأ, مش كل الخيارات موجودة



3.what is this pic?

Pic. Of rubeosis iridis

4. all are tru except?
give steroid
beta blocker
drug causes meiosis

السؤال دوائر

What is the diagnosis?
Nuclear cataract
What is the treatement?
Phacoemulsification

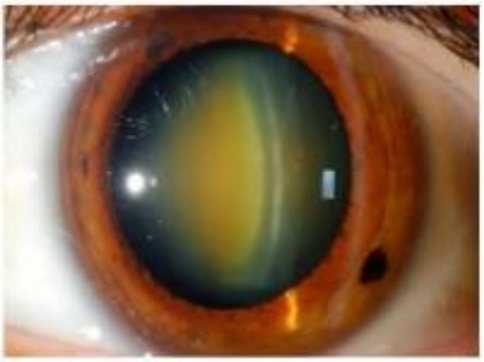

Nuclear cataract

bacterial keratitis

Pt with low back pain referred to ophthalmologist?

Posterior synechiae

What investigation to do for dx?

X ray

Dx? Ankylosing spondylitis

Case (mentioned that there is abruit heard),dx?

Cavernous sinus fistula

Dx?esotropia

Which of the following to do next? Cyclorrfraction

Dr covered the right eye and described her glasses, her father said that her vision become worse when she take off glsses, whatis your appointement?

1. Doctor covered the wrong eye
2. No benefit from glasss
3. The dicision of glasse is wrong from first
4. Prepare to sx after glasses using is failed

patient with dendritic ulcer, and recurrent stomatitis, what is the least likely cause of the recurrence of ulcer?

topical steroids
systemic steroids
topical antibiotics
UV Light
Concurrent with systemic disease

Match the following correctly

left monocular blindness --> left retrobulbar optic neuropathy

bitemporal hemianopia --> suprasellar aneurysm

right homonymous hemianopia --> left MCA stroke

left monocular nasal hemianopia --> left internal carotid artery atheroma

right homonymous hemianopia with macular sparing --> left PCA stroke

left central scotoma --> left age-related macular degeneration

left arcuate scotoma --> left eye glaucoma

Patient (contact lens wearer) resents with red painful eye and photopsia, what is the most likely diagnosis?

bacterial keratitis

what is the appropriate management?

give 4th generation fluoroquinolones

admit and give broad

spectrum iv antibiotics

give lubricants and refer to opthalmologist

Q12) A child presented withthis sign , all of the following about this condition are true except ?

A. it's caused by RB1 gene
B. it's begnin condition that dosen't require further intervention
C. plaque radiotherapy can be used for solitary cases
D. it may cause retinal detachment
E. trilateral form tend to be bilateral

ANSWER : 2

—All of the following
complications of cataract
except?
retinoblastoma
—All of the following can
lead to cataract except?
Mixed astigmatism

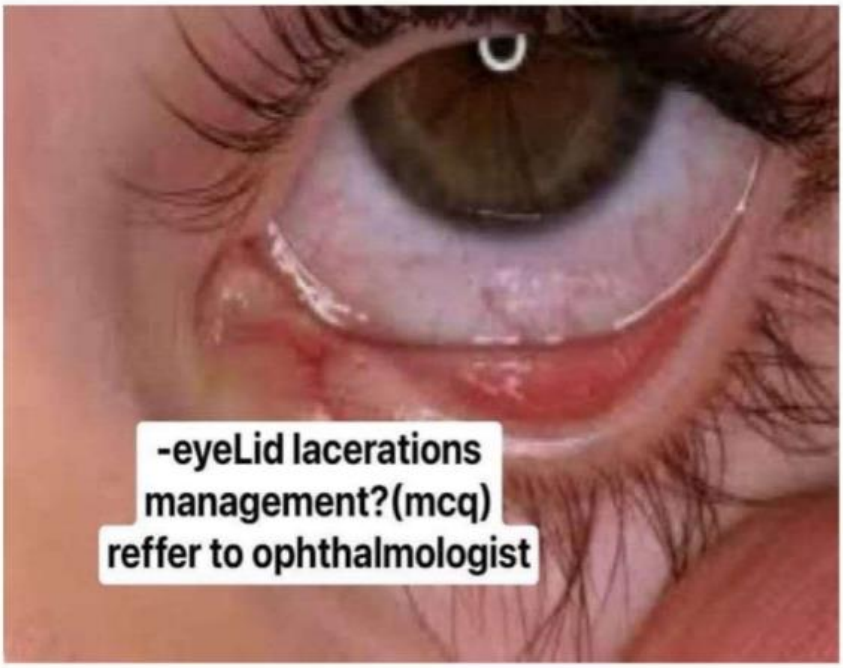
-eyeLid lacerations
management?(mcq)
reffer to ophthalmologist

2 question about congenital glaucoma

1) All true except :

1) Using Anesthesia can be delayed until 2nd year age and measure iop

2) Anesthesia use is mandatory for IOP measuring

3) Clear cornea doesn't exclude glaucoma

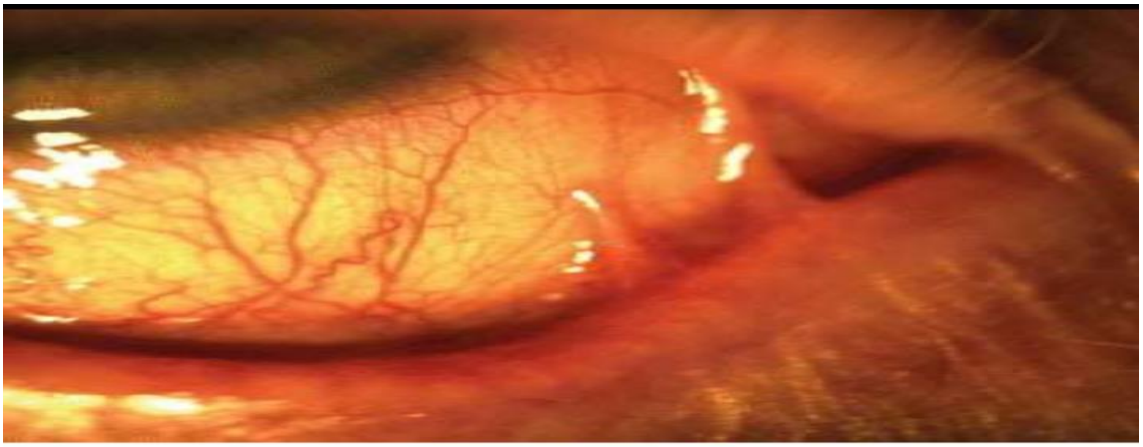

All can cause cicatricial conjunctivitis except?

bullous pemphoid

Stevens Johnson syndrome

chemical burn

trachoma

bacterial conjunctivitis

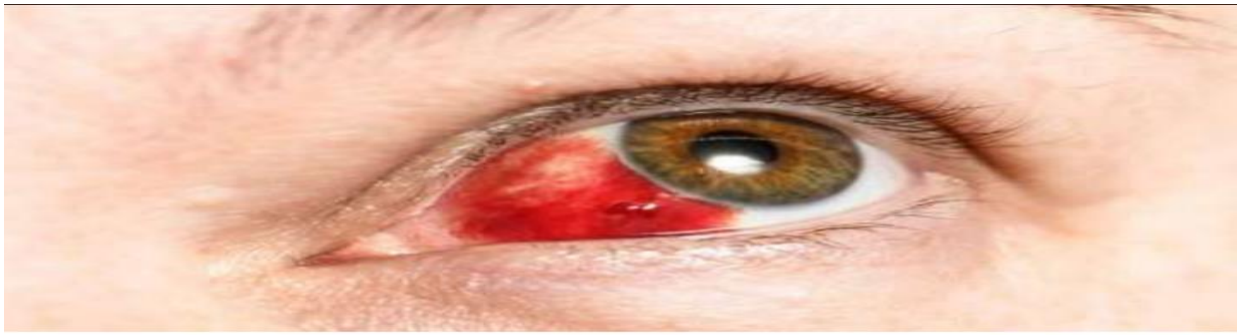

child presents with subconjunctival hemorrhage due to excessive rubbing of eyes, physician did not give the child any eye drops, but the parents insist that he should be given treatment, is the action of the physician true or false?

true

Cherry red spot
Seen in central retinal artery occlusion

+ orbital tumer

benign or malignant

1) 26 year old female pregnant lady presented with this sign , she has history of recurrent stomatitis , whats the most likely to be the cause of recurrence ?

A. topical steroids use

B. systemic steroids use

C. topical antibiotics use

ANSWER : A

2) Cicatrical infalmmatory symblepharon is caused by all of the following except :

A. bollous pemphegoid

B. chemical burns

C. steven johnson's syndrome

D. Trachoma

E. Bacterial conjunctivitis

ANSWER : E

3)

Patient came with runny nose and fever for 2 days, all of the following can cause this clinical presentation except?

viral conjunctivitis
trachoma
bacterial conjunctivitis
toxic reaction to eye drops
allergic conjunctivitis

4)

match each visual field defect with its cause

Notes	Typical lesions	Field defect	Blood supply	Locus of the visual pathway
	Optic neuritis Amaurosis fugax Optic atrophy Retrobulbar optic neuropathy Trauma	Ipsilateral monocular blindness	Ophthalmic artery	**Optic nerve**
	Central) (chiasm Pituitary adenoma Suprasellar aneurysm ------- Peripheral chiasm Internal carotid artery atheroma	Bitemporal hemianopia (central chiasm) ---------- Ipsilateral monocular nasal hemianopia (peripheral chiasm)	:Branches from Internal carotid Posterior communicating artery Anterior cerebral artery Anterior communicating artery	**Optic chiasm**
	MCA Stroke	Contralateral homonymous hemianopia	Middle cerebral artery (MCA)	**Optic tract**
	MCA Stroke	Contralateral homonymous quadrantanopia	Middle cerebral artery (MCA)	**Optic radiation**
	PCA, Posterior communicating artery	Contralateral homonymous hemianopia **with macular sparing**	Mostly by the PCA. The MCA also helps supply the anterior portion, which corresponds .to the macula	**Calcarine sulcus**
	PCA, Posterior communicating artery	Contralateral homonymous hemianopia **with macular sparing**	Mostly by the PCA. The MCA also helps supply the anterior portion, which corresponds .to the macula	**Occipital cortex**

7خيارات وكل خيار بعلامة

من موقع الدكتور خليل

Book Now

Match the following correctly 4)

left monocular blindness --> left retrobulbar optic neuropathy

bitemporal hemianopia --> suprasellar aneurysm

right homonymous hemianopia --> left MCA stroke

left monocular nasal hemianopia --> left internal carotid artery atheroma

right homonymous hemianopia with macular sparing --> left PCA stroke

left central scotoma --> left age-related macular degeneration

left arcuate scotoma --> left eye glaucoma

5) MCQ

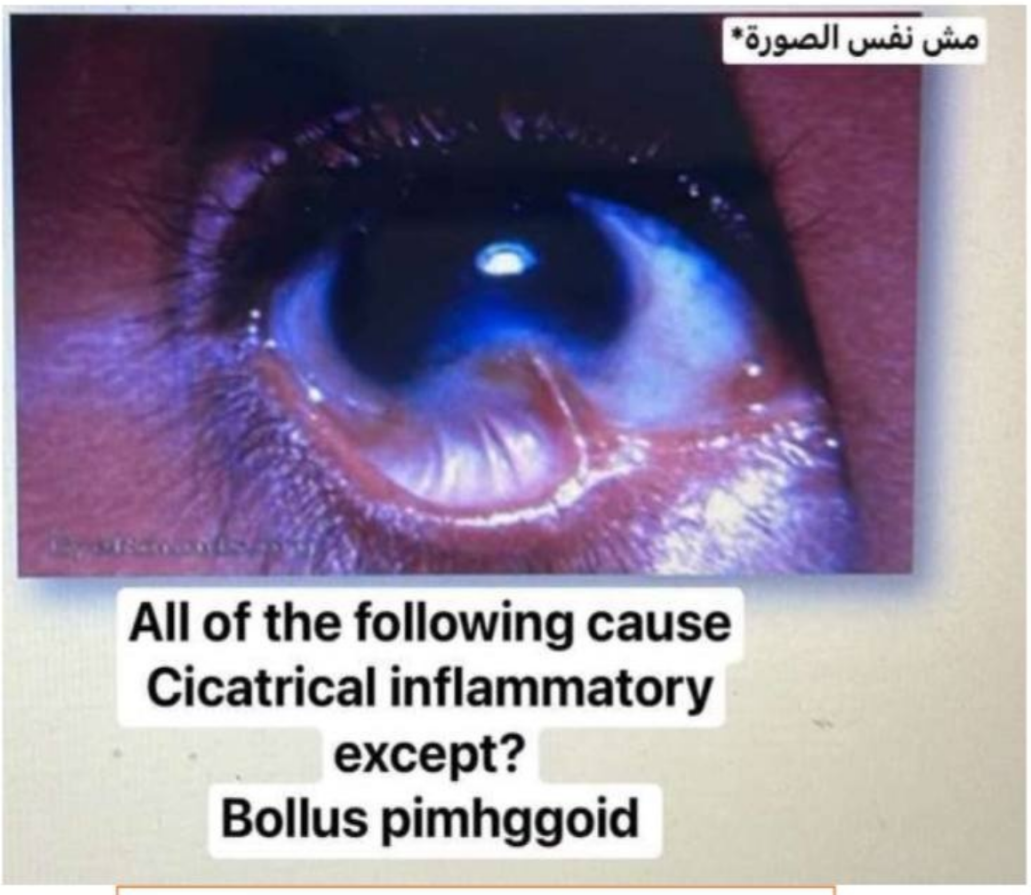

**Bacterial conjunctivitis

•dendritic ulcer ..**least** uncommon of these for recurrence : (MCQ)

b)

antibiotic use

•dendritic ulcer ..**least** uncommon of these for recurrence : (MCQ)

antibiotic use

نعبة في الانجليزي least uncommon = most common

مو متأكدين من الجواب ؟ مكرر كتير السؤال

الجواب Topical steroids عالأغلب

7) MCQ

ما بنقدر نحدد اذا صح او لأ, مش كل الخيارات موجودة

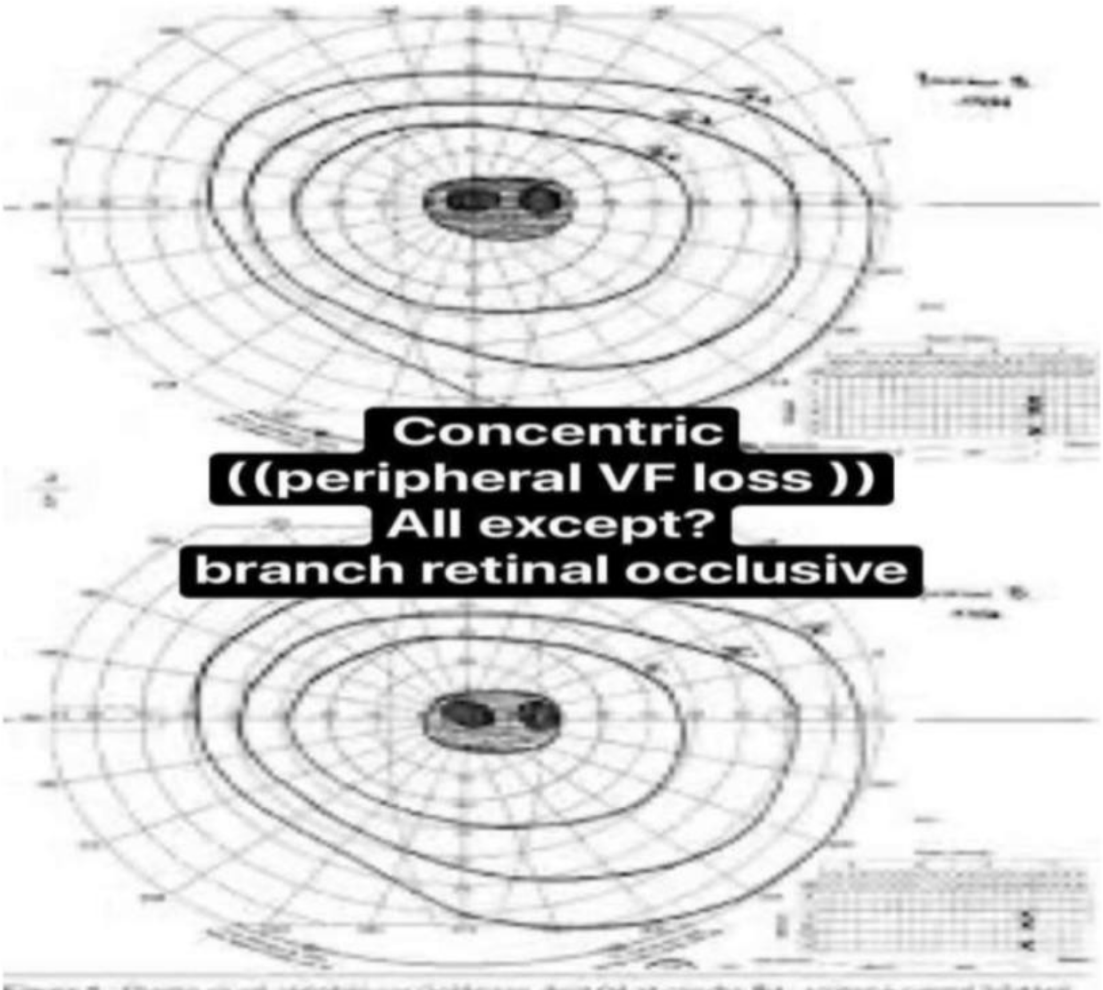

20 Not The same picture.

History :fever+ urethral Discharge + positive VDRL

8) name of the Sign:

Keratic perceptate

9)caused By -->Syphilis

10)Management--> steroid +IV ANTIBIOTIC

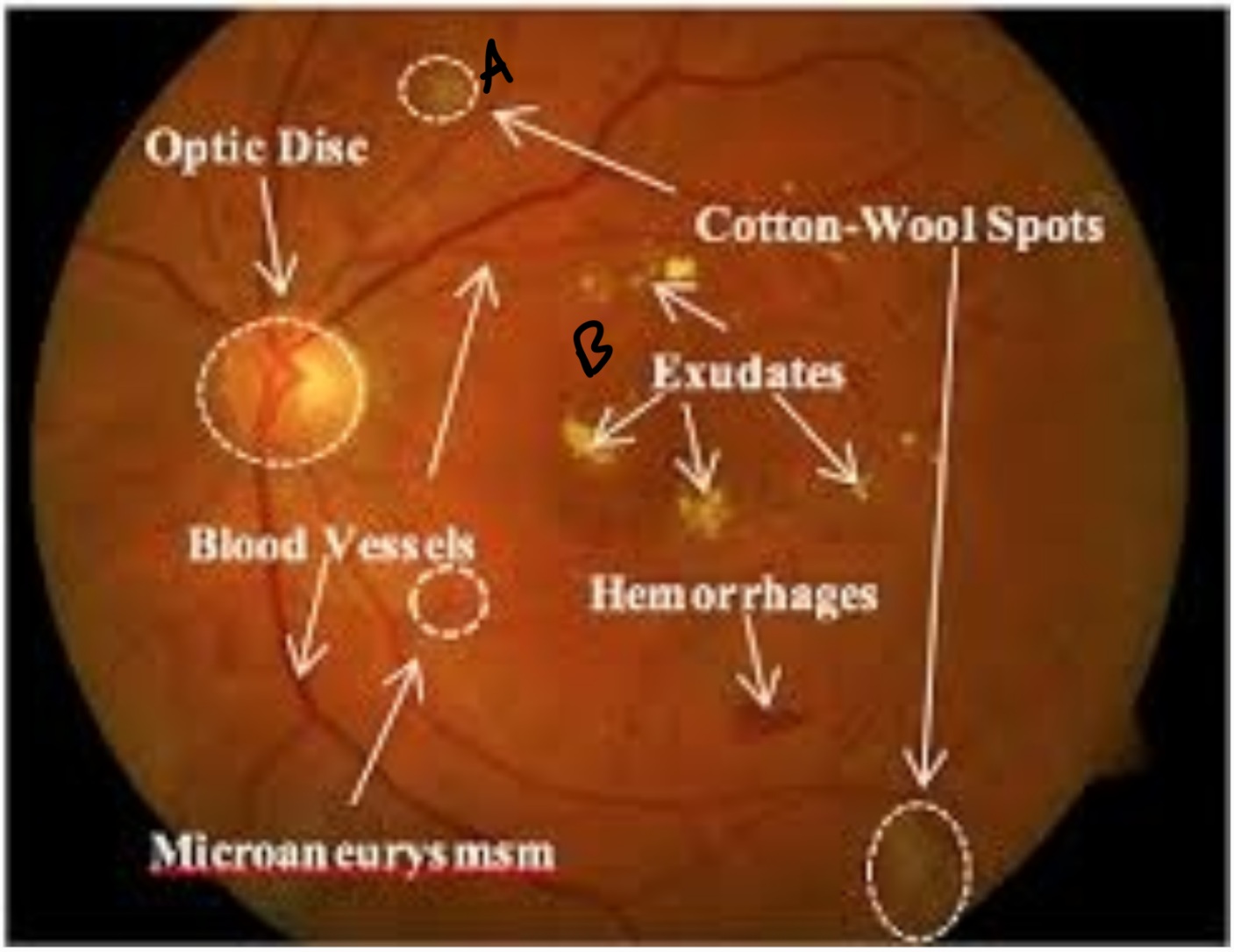

(11
A --> Nerve Fiber ischemia (cotton wall)
(12
B--> Hard exudate
13) Management -->pan retinal coagulation

14)what to do Next?
appointment for surgery
(congenital ptosis)

15) one of the following is false?
Myopic eye treated with convex lens

16) .all are tru except
cyclorefraction in children is not mandatory(not sure)

! "#$%$&’ (#)*&’ +,-. /)01’
2)34 !*5, / !6&-6&’

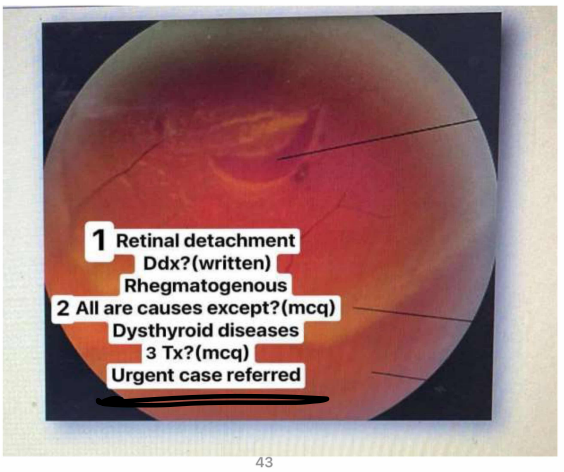
1 Retinal detachment
Ddx?(written)
Rhegmatogenous
2 All are causes except?(mcq)
Dysthyroid diseases
3 Tx?(mcq)
Urgent case referred

43


Concentric
((peripheral VF loss))
All except?
branch retinal occlusive

44

All of the following true
about this condition except?
Large chalazion lead to
astigmatism

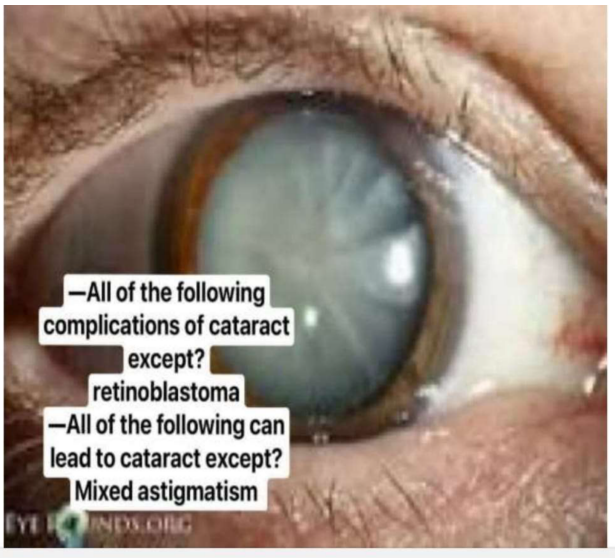

47

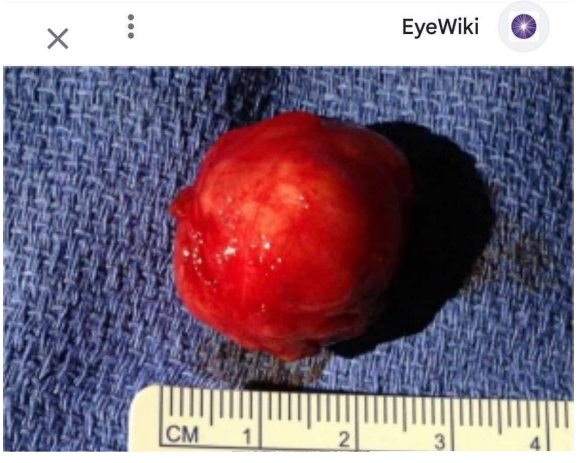

Type of tumor?

Pleomorphic adenoma

Malignant or benign? Benign.

Wateen Group 6

الامتحان كان 15 سؤال ضع دائرة و من ضمنهم ثلاث اسئلة صح وخطأ
و سؤالين توصيل : واحد ١٢ فرع والثاني ٧ افرع
ما بنعرف كيف تقسيمة العلامات بتصير 🙃

1

All of the following DDX except :
A. Congenital cataract
B. Retinoblastoma
C. Melanoma ✅

2

What is the management ?
A. Refer to ophthalmology clinic ✅

3

this neonate will have a <u>good</u> long-term prognosis for his visual field.
A. True
B. False

Patient (contact lens wearer) resents with red painful eye and photopsia

4 what is the most likely diagnosis?
A. bacterial keratitis ✅
B. Bacterial conjunctivitis

5 what is the appropriate management?
A. give 4th generation fluoroquinolones ✅
B. admit and give broad
C. spectrum iv antibiotics
D. give lubricants and refer to opthalmologist

---

6 Cause of A???

Nerve fiber layer ~~infection~~ infarction

7 Cause of B???
Lipid deposition

8 Best management???
Control hypertension and DM

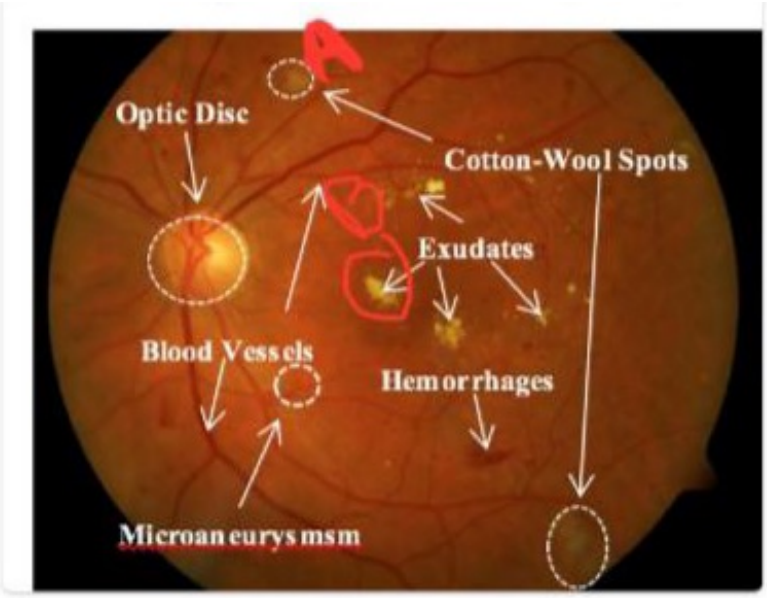

9

What you see??
Morton fat keratin precipitate

10

And what is the treatment?

Penicillin

11

If positive VDRL . What is your diagnosis ??
Syphilis

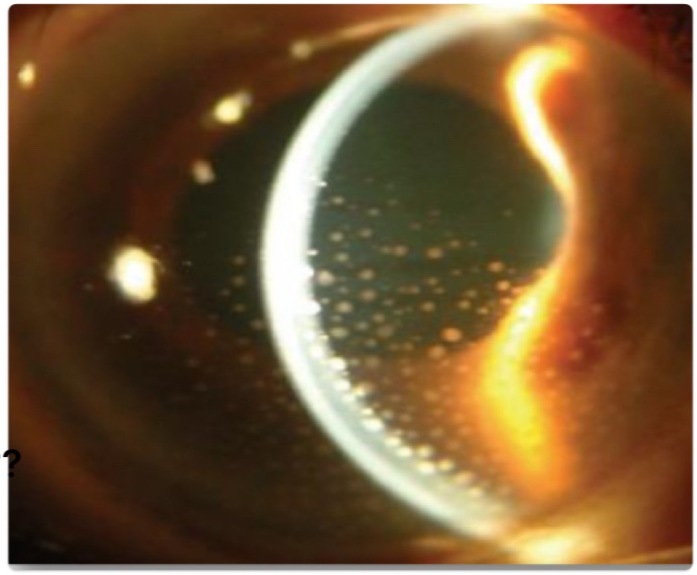

12

3 month old presents with excessive tearing, family doctor urged parents to do probing is this true of false?

False

13

child presents with subconjunctival hemorrhage due to excessive rubbing of eyes, physician did not give the child any eye drops, but the parents insist that he should be given treatment, is the action of the physician true or false?

true

14

Q8) A child fell off his bicke came to the ER with this presentaion , what's your managment :

A. reassure the parents that it will heal spontanuously

B. reffer to the ophthtalamologis for further managment

C. clean the wound an send home

D. suture the wound by yourself

ANSWER : B

---

15 **All true about hypermitrope except :**
Needs minus lens

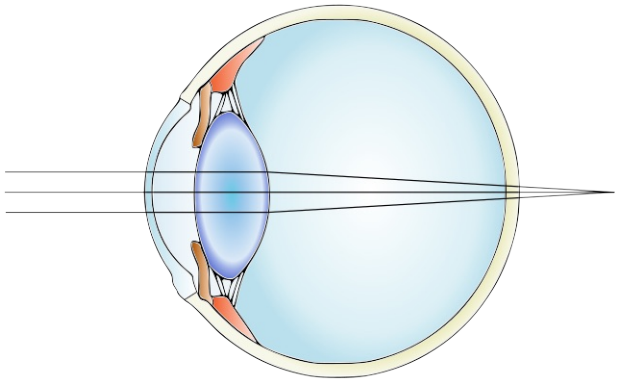

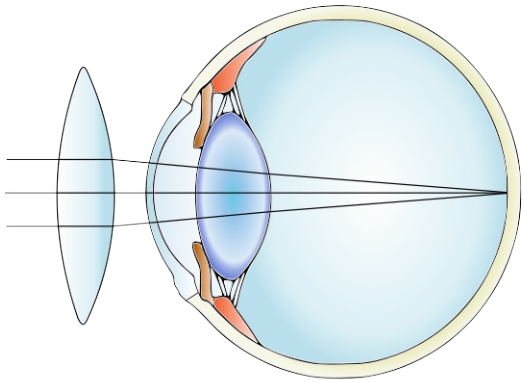

⬇️⬇️ سؤالين التوصيل

(16) **Match the following correctly**

left monocular blindness --> left retrobulbar optic neuropathy
bitemporal hemianopia --> suprasellar aneurysm
right homonymous hemianopia --> left MCA stroke
left monocular nasal hemianopia --> left internal carotid artery atheroma
right homonymous hemianopia with macular sparing --> left PCA stroke
left central scotoma --> left age-related macular degeneration
left arcuate scotoma --> left eye glaucoma

(17)

Q15) Match the following about direct and indirect ophthalmoscope
1) in direct ophthalmoscope the image is. > virtual and erect
2) direct ophthalmoscope magnification power > *15
3)indirect ophthalmoscope magnification power > 3-5
4) diameter of the field of observation in direct ophthalmoscope > about 10°
5)diameter of the field of observation in indirect ophthalmoscope is > greater than 37° degree
6) scleral indentaion can not be seen using > direct ophthalmoscope
7) visualisation in hazy media is poor using > direct ophthalmoscope due to low illumination
8) image in indirect ophthalmoscope is . > real and inverted
9) structures seen using direct ophthalmoscope are. > central retina only
10) structures seen using indirect ophthalmoscope are > central and peripheral retina
11) indirect ophthalmoscope has > high illumination
12) Stenosis can be achieved by > indirect ophthalmoscope

Indirect ophthalmoscopy	Direct Ophthalmoscopy	
times when a +13D condensing lens is used 5	About 15 times	**Magnification**
Wider (about 37° in diameter)	Smaller (about 10° in diameter)	**Diameter of the field of observationview**
There is relatively greater brightness	There is relatively low brightness	**Brightness**
Peripheral retina seen *(by using a scleral depressor in addition to the indirect ophthalmoscopy itself)*	Central retina only	**Structures seen**
Real & inverted image	Virtual & erect image	**Image of the fundus that is seen**
Binocular indirect ophthalmoscopy provides better stereopsis	Image formed is not stereoscopic	**Stereopsis**
Seen better	Not well seen (seen with difficulty)	**Retina anterior to the equator**
Can be easily done in binocular indirect ophthalmoscopy	Difficult	**Scleral indentation**
Better	Poor	**Visualization in hazy media**

(ولسوف يعطيك ربك فترضى)

Ophthalmology December archive
Batool frehat and lama

1)false about hypermetropia??
Need minus lens
2)one is false?? خيارات غريبه شوي
Cycloplegic refraction is not mandatory for children

Unilateral diplopia more common in astigmatism

3)not found in trachoma???

Ectropion

4)

3 month old presents with excessive tearing, family doctor urged parents to do probing is this true of false?
False

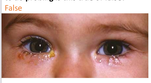

5)all true except ??
نفس الصوره اللي قبل

Minority resolve within 6 months

6)



7)

Patient came with runny nose and fever for 2 days, all of the following can cause this clinical presentation except?
viral conjunctivitis
trachoma
bacterial conjunctivitis
toxic reaction to eye drops
allergic conjunctivitis

8)

what is the best step of management?
refer to ophthalmologist for upper lid surgery

9)

Q11) All of the following causes homonymos hemonopia except :

A. optic tract lesion before ...
B. optic nerve
C. optic tract lesion after ...
D. optic radiation
E. calcarine sulcus

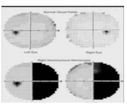

ANSWER : B

10)

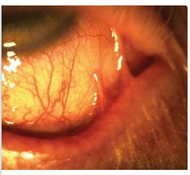

All can cause cicatricial conjunctivitis except?
bullous pemphoid
Stevens Johnson syndrome
chemical burn
trachoma
bacterial conjunctivitis

11) +12)+13)

Cause of A???

Nerve fiber layer infection

Cause of B???
Lipid deposition

Best management???
Control hypertension and DM

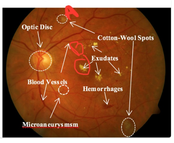

14) توصيل

Match the following correctly 4)
left monocular blindness --> left retrobulbar optic neuropathy
bitemporal hemianopia --> suprasellar aneurysm
right homonymous hemianopia --> left MCA stroke
left monocular nasal hemianopia --> left internal carotid artery atheroma
right homonymous hemianopia with macular sparing --> left PCA stroke
left central scotoma --> left age-related macular degeneration
left arcuate scotoma --> left eye glaucoma

15) least common for recurrence??

Antibiotics

•dendritic ulcer ..**least** uncommon of these for recurrence : (MCQ) b)
antibiotic use

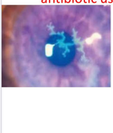

•dendritic ulcer ..**least** uncommon of these for recurrence : (MCQ)
antibiotic use

16)+17)+18)
What you see??
Morton fat keratin precipitate

And what is the treatment?

Penicillin

If positive VDRL . What is your diagnosis ?
Syphilis

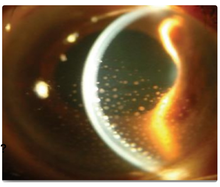

19)
Student with your age in mutah uni with positive RAPD diagnosed with optic neuritis

RAPD is common finding
Ring scotoma