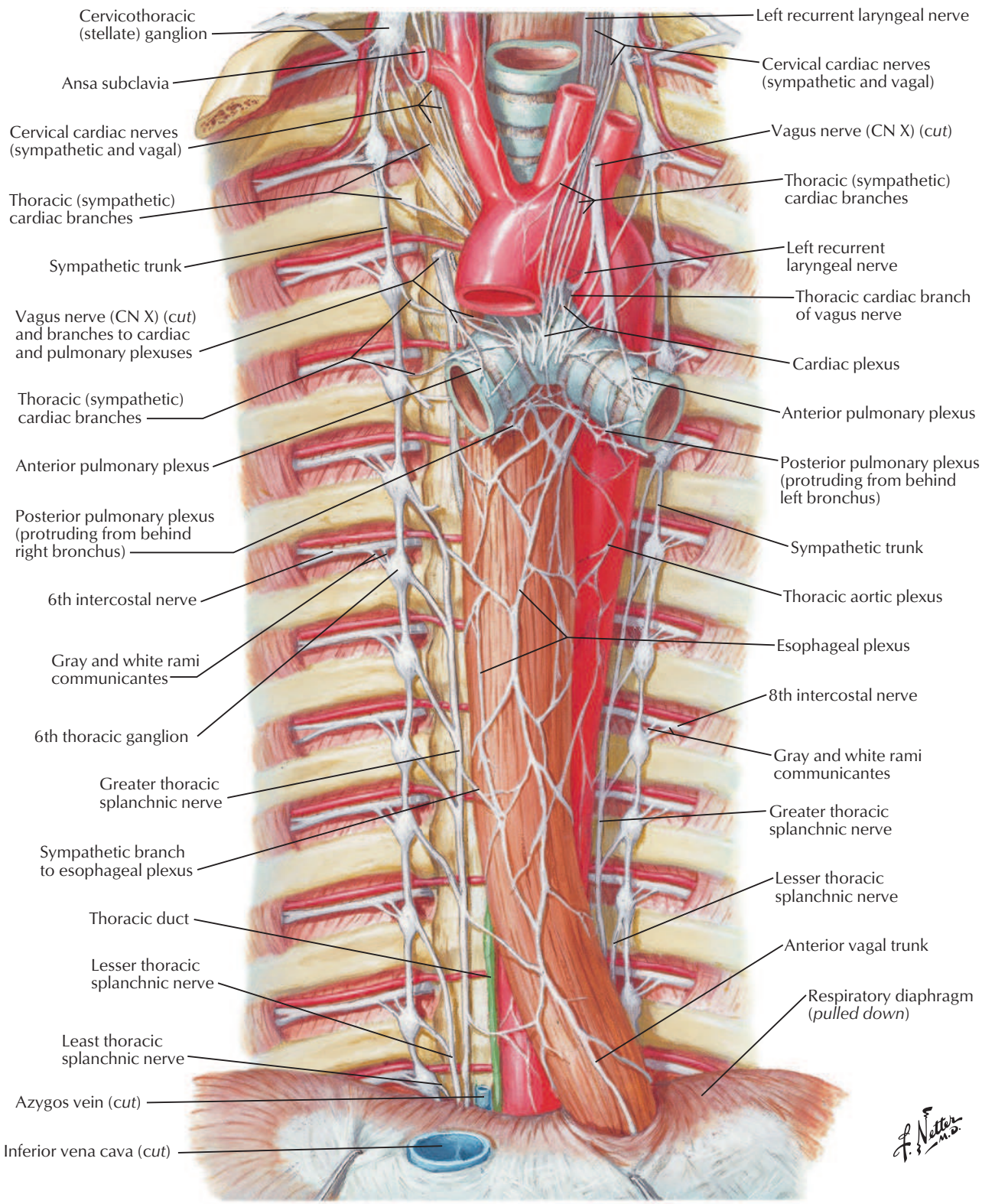
Cervicothoracic (stellate) ganglion
Ansa subclavia
Cervical cardiac nerves (sympathetic and vagal)
Thoracic (sympathetic) cardiac branches
Sympathetic trunk
Vagus nerve (CN X) (*cut*) and branches to cardiac and pulmonary plexuses
Thoracic (sympathetic) cardiac branches
Anterior pulmonary plexus
Posterior pulmonary plexus (protruding from behind right bronchus)
6th intercostal nerve
Gray and white rami communicantes
6th thoracic ganglion
Greater thoracic splanchnic nerve
Sympathetic branch to esophageal plexus
Thoracic duct
Lesser thoracic splanchnic nerve
Least thoracic splanchnic nerve
Azygos vein (*cut*)
Inferior vena cava (*cut*)
Left recurrent laryngeal nerve
Cervical cardiac nerves (sympathetic and vagal)
Vagus nerve (CN X) (*cut*)
Thoracic (sympathetic) cardiac branches
Left recurrent laryngeal nerve
Thoracic cardiac branch of vagus nerve
Cardiac plexus
Anterior pulmonary plexus
Posterior pulmonary plexus (protruding from behind left bronchus)
Sympathetic trunk
Thoracic aortic plexus
Esophageal plexus
8th intercostal nerve
Gray and white rami communicantes
Greater thoracic splanchnic nerve
Lesser thoracic splanchnic nerve
Anterior vagal trunk
Respiratory diaphragm (*pulled down*)
F. Netter M.D.

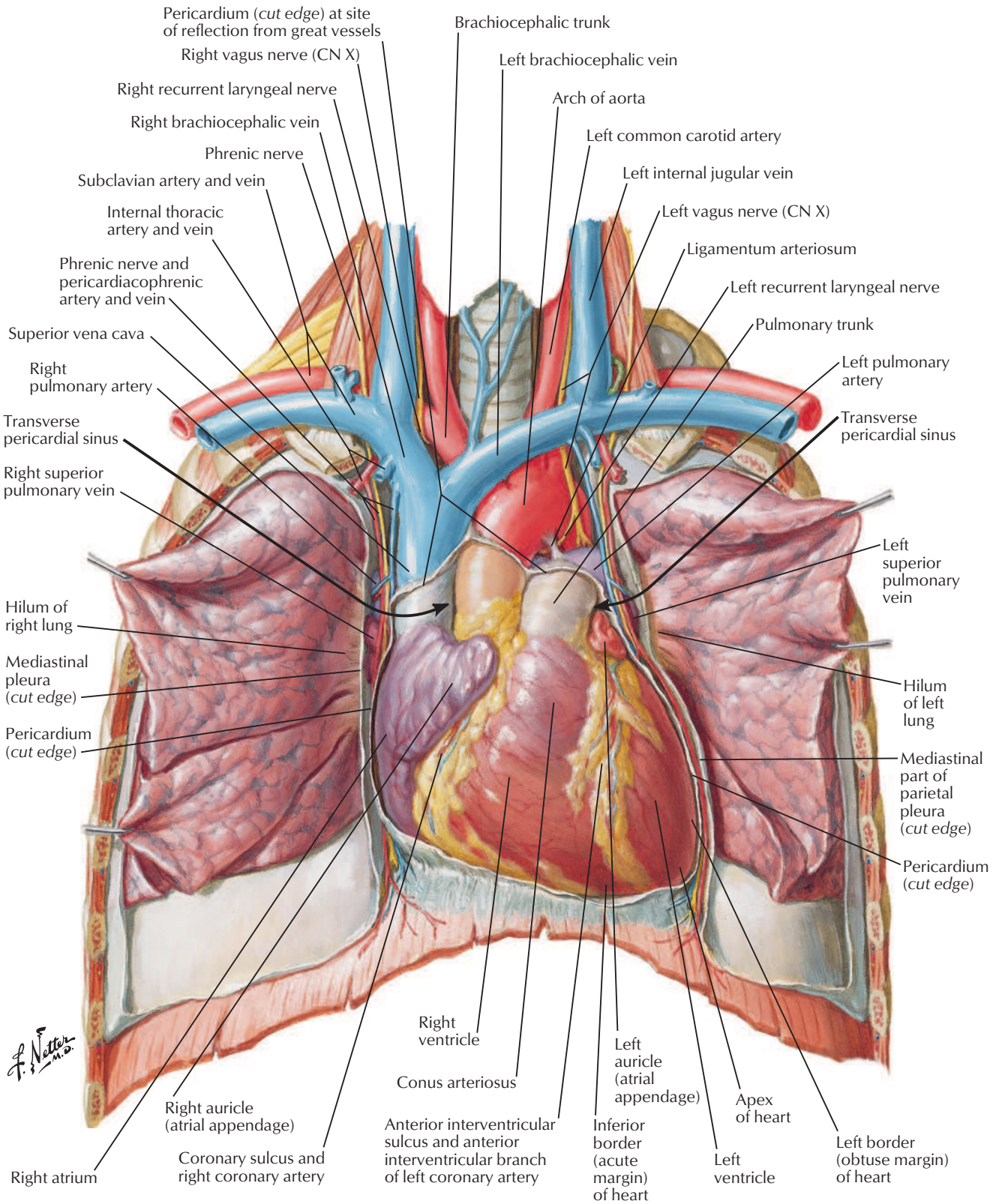
Pericardium (*cut edge*) at site of reflection from great vessels
Right vagus nerve (CN X)
Right recurrent laryngeal nerve
Right brachiocephalic vein
Phrenic nerve
Subclavian artery and vein
Internal thoracic artery and vein
Phrenic nerve and pericardiacophrenic artery and vein
Superior vena cava
Right pulmonary artery
Transverse pericardial sinus
Right superior pulmonary vein
Hilum of right lung
Mediastinal pleura (*cut edge*)
Pericardium (*cut edge*)
Right atrium
Right auricle (atrial appendage)
Coronary sulcus and right coronary artery
Right ventricle
Conus arteriosus
Anterior interventricular sulcus and anterior interventricular branch of left coronary artery
Brachiocephalic trunk
Left brachiocephalic vein
Arch of aorta
Left common carotid artery
Left internal jugular vein
Left vagus nerve (CN X)
Ligamentum arteriosum
Left recurrent laryngeal nerve
Pulmonary trunk
Left pulmonary artery
Transverse pericardial sinus
Left superior pulmonary vein
Hilum of left lung
Mediastinal part of parietal pleura (*cut edge*)
Pericardium (*cut edge*)
Left auricle (atrial appendage)
Inferior border (acute margin) of heart
Apex of heart
Left ventricle
Left border (obtuse margin) of heart

Lymph Vessels and Nodes of Posterior Abdominal Wall

See also Plates 319, 388

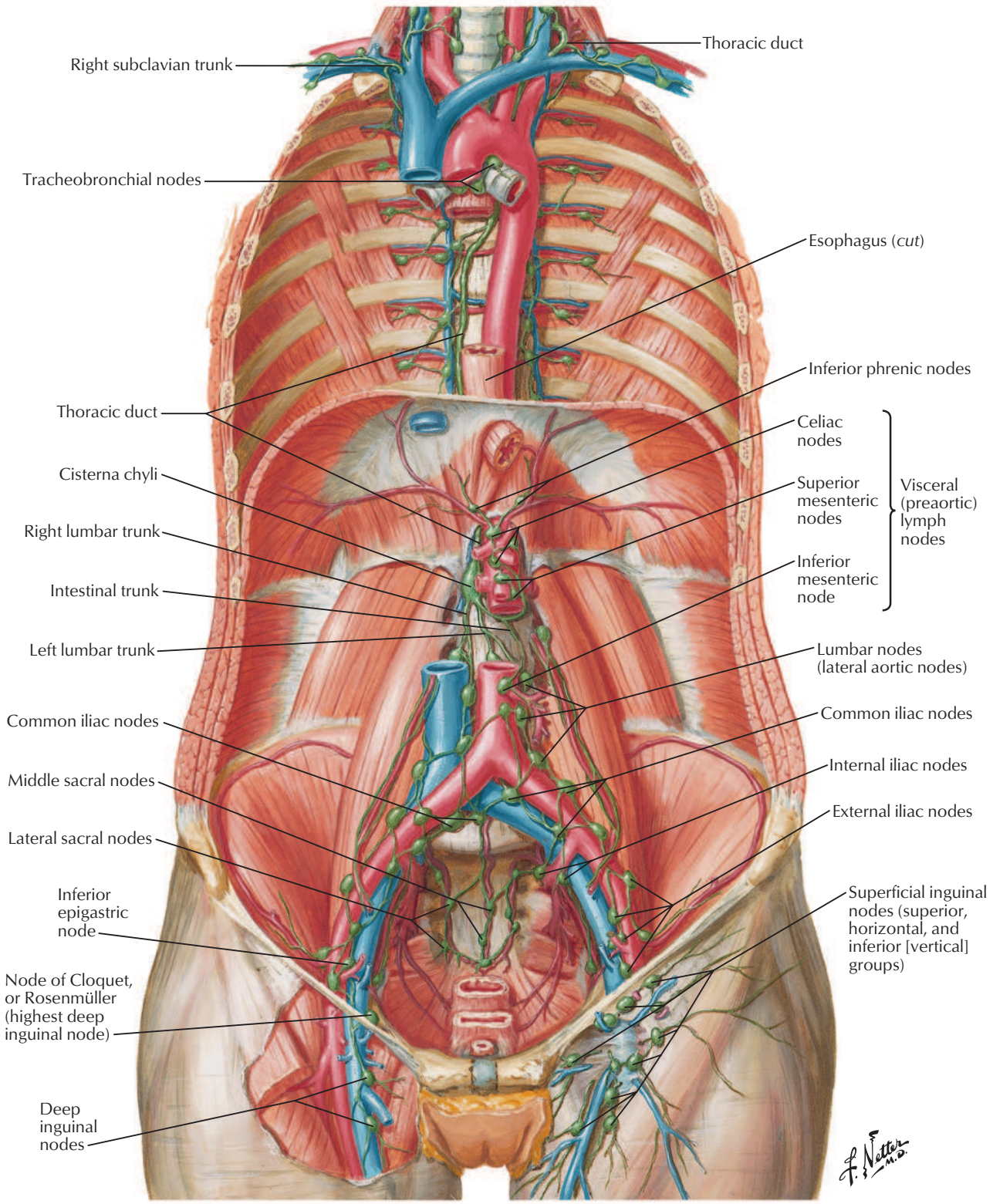
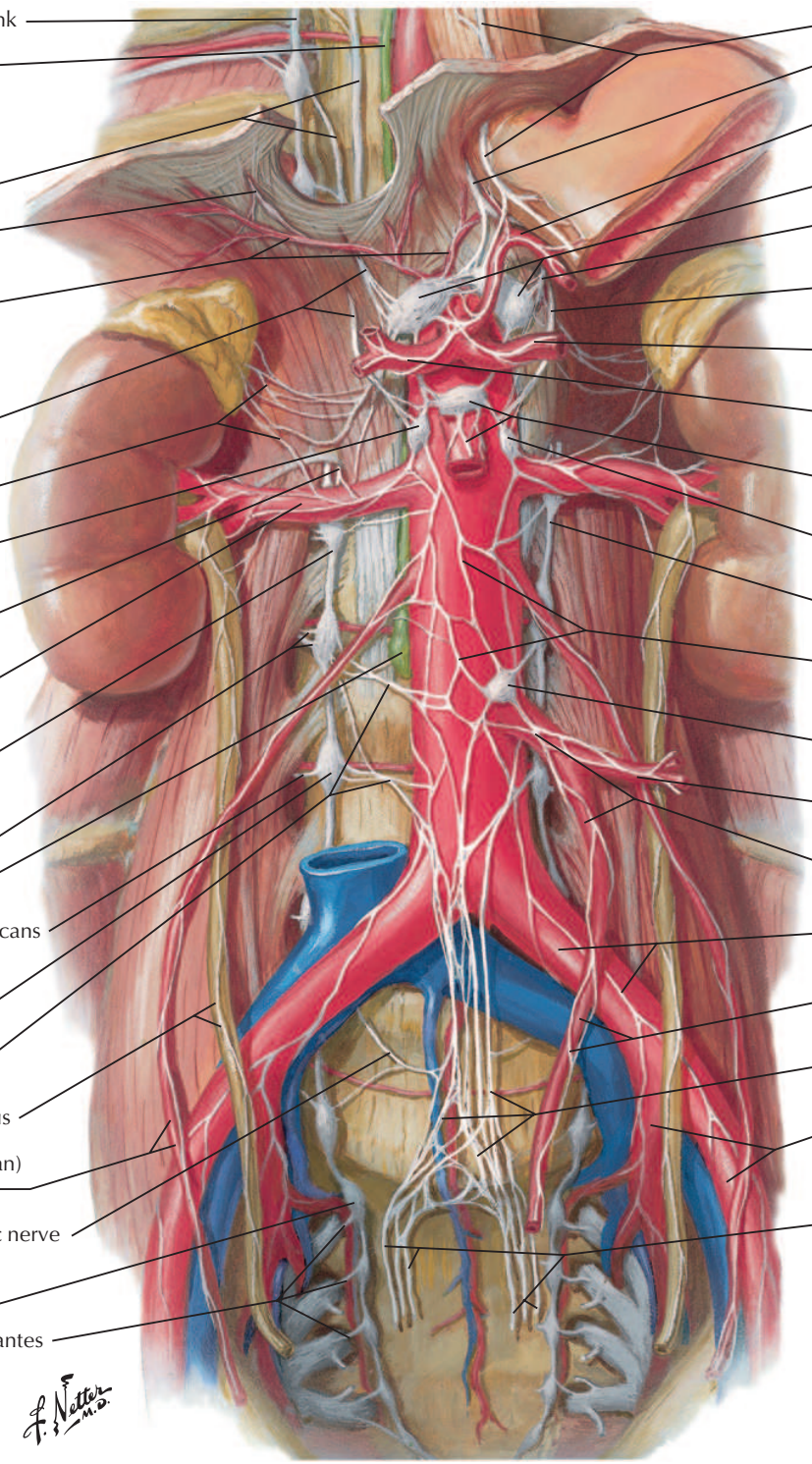
See also Plate 305