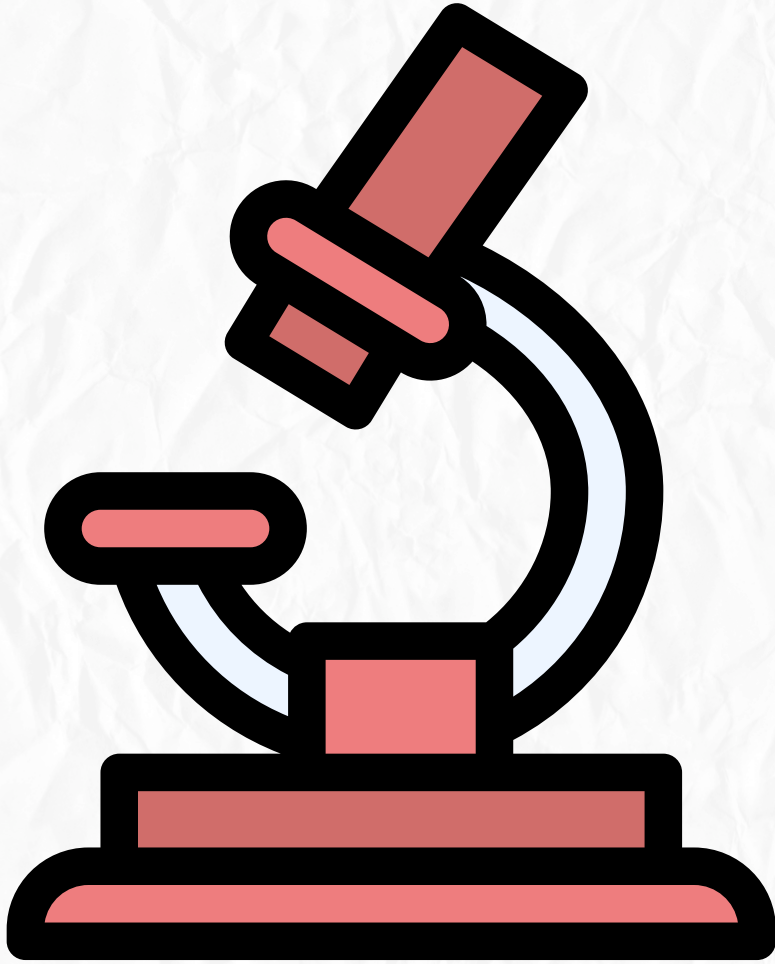


Histology

Quiz time



Bone formation

1. What is the primary function of bone tissue?

- (A) Store calcium inside the bone marrow**
- (B) Act as a blood clotting organ**
- (C) Support soft tissues and protect vital organs**
- (D) Provide a site for muscle attachment only**

2. Where is bone marrow located, and what is its function?

- (A) Surrounding the bone and acts as a protective layer**
- (B) In the periosteum and helps in bone growth**
- (C) Within the bone and acts as a haemopoietic organ**
- (D) Within the endosteum and acts as a blood vessel supply**

3. What are the primary components of bone matrix?

- (A) Calcium salts and collagen fibers**
- (B) Calcium salts and osteoclast cells**
- (C) Collagen fibers and ground substance**
- (D) Osteogenic cells and calcium salts**

4. What is the main cell type responsible for bone formation?

- (A) Osteocytes**
- (B) Osteoclasts**
- (C) Osteoblasts**
- (D) Osteogenic cells**

5. How do osteocytes maintain contact with each other?

- (A) By direct physical connection**
- (B) Using perforating fibers**
- (C) Through gap junctions in canaliculi**
- (D) Through organelles within the lacunae**

6. What stimulates osteogenic cells to become osteoblasts?

- (A) Growth and repair of bone**
- (B) Degeneration of bone tissue**
- (C) Calcification of the bone matrix**
- (D) Differentiation into osteocytes**

7. What happens to osteoblasts when they are surrounded by the bone matrix?

- (A) They become inactive osteocytes**
- (B) They become more active**
- (C) They die**
- (D) They transform into osteoclasts**

8. Where are osteoclasts primarily located, and what is their function?

- (A) In the endosteum, responsible for bone formation**
- (B) In Howship's lacunae, responsible for bone resorption**
- (C) In lacunae, responsible for calcium storage**
- (D) In the periosteum, responsible for bone growth**

9. What is the function of the periosteum's outer fibrous layer?
- (A) Contains dense collagen fibers that bind the periosteum to the bone
 - (B) Facilitates the transfer of nutrients
 - (C) Contains large blood vessels and nerves
 - (D) Houses bone marrow for blood cell formation
10. Which component makes the bone matrix highly acidophilic?
- (A) Ground substance
 - (B) Osteocytes
 - (C) Collagen type I
 - (D) Calcium phosphate
11. What are the inorganic components of the bone matrix?
- (A) Collagen fibers and glycoproteins
 - (B) Fibers and ground substance
 - (C) Calcium hydroxyapatite and calcium phosphate
 - (D) Alkaline phosphatase and proteoglycans
12. What characterizes the endosteum?
- (A) Composed of a single layer of osteogenic cells and little connective tissue
 - (B) Composed of dense fibrous layers
 - (C) Contains specialized muscle fibers
 - (D) Acts as the main structural framework of the bone
13. What characterizes the surface of the zone facing the bone in osteoclasts?
- (A) The surface facing the bone is flat
 - (B) The surface facing the bone is highly mineralized
 - (C) The surface facing the bone is irregular
 - (D) The surface facing the bone is smooth
14. Which zone in an osteoclast surrounds the ruffled border?
- (A) Ruffled Border
 - (B) Basal zone
 - (C) Clear Zone
 - (D) Region of vesicles and vacuoles
15. What does the region of vesicles and vacuoles contain in an osteoclast?
- (A) Nuclei of the cell
 - (B) Collagen fibers
 - (C) Mineralized bone particles
 - (D) Lysosomes
16. Which part of the osteoclast contains the nuclei and other cell organelles?
- (A) Region of vesicles and vacuoles
 - (B) Basal zone
 - (C) Ruffled Border
 - (D) clear zone

17. What is the function of osteoclasts in bone remodeling?

- (A) Bone formation**
- (B) Cartilage synthesis**
- (C) Maintenance of bone matrix**
- (D) Bone resorption**

18. Which cells secrete acid and collagenase to erode the bone matrix?

- (A) Osteoblasts**
- (B) Osteocytes**
- (C) Osteoclasts**
- (D) Osteogenic cells**

19. What term describes the temporary bone that first appears in development and is characterized by irregular collagen fiber arrangement?

- (A) Primary bone (Immature or woven)**
- (B) Cancellous bone**
- (C) Compact bone**
- (D) Secondary bone (lamellar)**

20. What type of bone is usually present in adults and is characterized by high calcium content and regularly arranged collagen fibers?

- (A) Cancellous bone**
- (B) Compact bone**
- (C) Secondary bone (lamellar)**
- (D) Primary bone (Immature or woven)**

- 1.C Support soft tissues and protect vital organs
- 2.C Within the bone and acts as a haemopoietic organ
- 3.A Calcium salts and collagen fibers
- 4.C
- 5.C Through gap junctions in canaliculi
- 6.A Growth and repair of bone
- 7.A
- 9.B
- 10.C Collagen type I
- 11.C Calcium hydroxyapatite and calcium phosphate
- 12.A Composed of a single layer of osteogenic cells and little connective tissue
- 13.C The surface facing the bone is irregular
- 14.C Clear Zone
- 15.D Lysosomes
- 16.B Basal zone
- 17.D Bone resorption
- 18.C Osteoclasts
- 19.A Primary bone (Immature or woven)
- 20.C Secondary bone (lamellar)

طب الأسنان

1. What are the two types of bone development?

- (A) Bone may develop directly from cartilage or indirectly from mesenchyme.**
- (B) Bone may develop only by the replacement of mesenchyme.**
- (C) Bone may develop indirectly from mesenchyme only.**
- (D) Bone may develop directly from mesenchyme or indirectly by the replacement of cartilage**

2. Which type of ossification involves the deposition of bone matrix on the surface of pre-existing cartilage matrix?

- (A) Intramembranous ossification.**
- (B) Both Intramembranous and Endochondral ossification.**
- (C) Neither Intramembranous nor Endochondral ossification.**
- (D) Endochondral ossification.**

3. What forms as a result of intramembranous ossification?

- (A) Most bones of the body (short, long).**
- (B) Flat bones.**
- (C) The epiphyseal growth plate.**
- (D) Bone collar around cartilage model**

4. During intramembranous ossification, what cell type secretes osteoid tissue?

- (A) Osteocytes.**
- (B) Osteoblasts.**
- (C) Chondrocytes.**
- (D) Fibroblasts.**

5. What structure remains inside the epiphyses after endochondral ossification is completed?

- (A) Bone marrow cavity.**
- (B) Ossification centers.**
- (C) Hyaline cartilage in the epiphyseal plates and articular cartilages.**
- (D) Periosteum.**

6. Which of the following describes the primary ossification center formation?

- (A) Deposition of bone matrix directly on mesenchyme.**
- (B) Formation within mesenchyme without vascularization.**
- (C) Hypertrophy of chondrocytes followed by invasion of osteogenic cells and blood capillaries.**
- (D) Intramembranous ossification without any pre-existing cartilage.**

7. When do secondary ossification centers begin to form in endochondral ossification?

- (A) During adolescence.**
- (B) (C) (D) After full bone remodeling is completed.**
- At the time of bone repair.**
- Around the time of birth.**

8. What structure is found at the junction of the epiphysis with the diaphysis of long bones?

- (A) The periosteum.**
- (B) The ossification center.**
- (C) The red bone marrow.**
- (D) The epiphyseal plate.**

9. Which zone of the epiphyseal plate contains proliferating chondrocytes?

- (A) Hypertrophic zone.**
- (B) Proliferative zone.**
- (C) Resting zone.**
- (D) Calcification zone.**

طب الأسنان

- 1.D Bone may develop directly from mesenchyme or indirectly by the replacement of cartilage.
- 2.D Endochondral ossification.
- 3.B Flat bones.
- 4.B Osteoblasts.
- 5.C Hyaline cartilage in the epiphyseal plates and articular cartilages.
- 6.C Hypertrophy of chondrocytes followed by invasion of osteogenic cells and blood capillaries.
- 7.D Around the time of birth.
- 8.D The epiphyseal plate.
- 9.C Resting zone.



سُبْحَانَكَ اللَّهُمَّ وَبِحَمْدِكَ ، أَشْهَدُ أَنْ لَا
إِلَهَ إِلَّا أَنْتَ ، أَسْتَغْفِرُكَ وَأَتُوبُ إِلَيْكَ .