

وسهلا



أهلا

يُمنع أخذ السلايدات بدون  
إذن المحرر واي اجراء  
يخالف ذلك يقع تحت طائلة  
المسؤولية القانونية  
جميع المعلومات للاستخدام  
التعليمي فقط

الأستاذ الدكتور يوسف حسين

كلية الطب - جامعة مؤتة - الأردن

دكتورة من جامعة كولونيا المانيا

Prof. Dr. Youssef Hussein Anatomy - YouTube

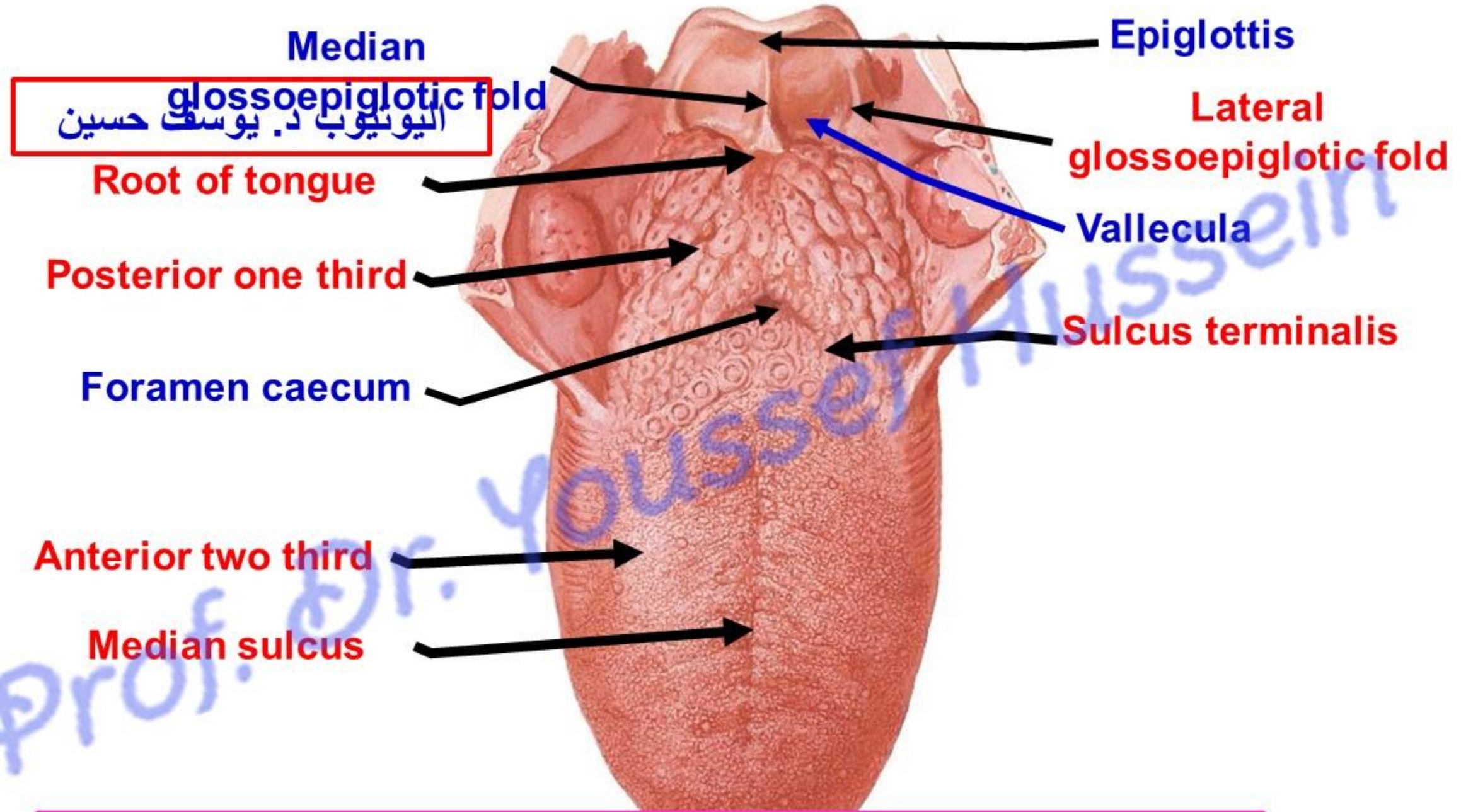
الواتس (أي استفسار)  
00201224904207

الـيـوتـيـوب دـ. يـوسـف حـسـين

dr\_youssefhussein@yahoo.com

# Development of Tongue

<https://www.youtube.com/@ProfDrYoussefHusseinAnatomy/playlists>



Median  
glossoepiglottic fold  
الْيُوسُفُ بْنُ يُوْسُفَ حُسَيْنِ

Epiglottis

Lateral  
glossoepiglottic fold

Vallecula

Root of tongue

Posterior one third

Sulcus terminalis

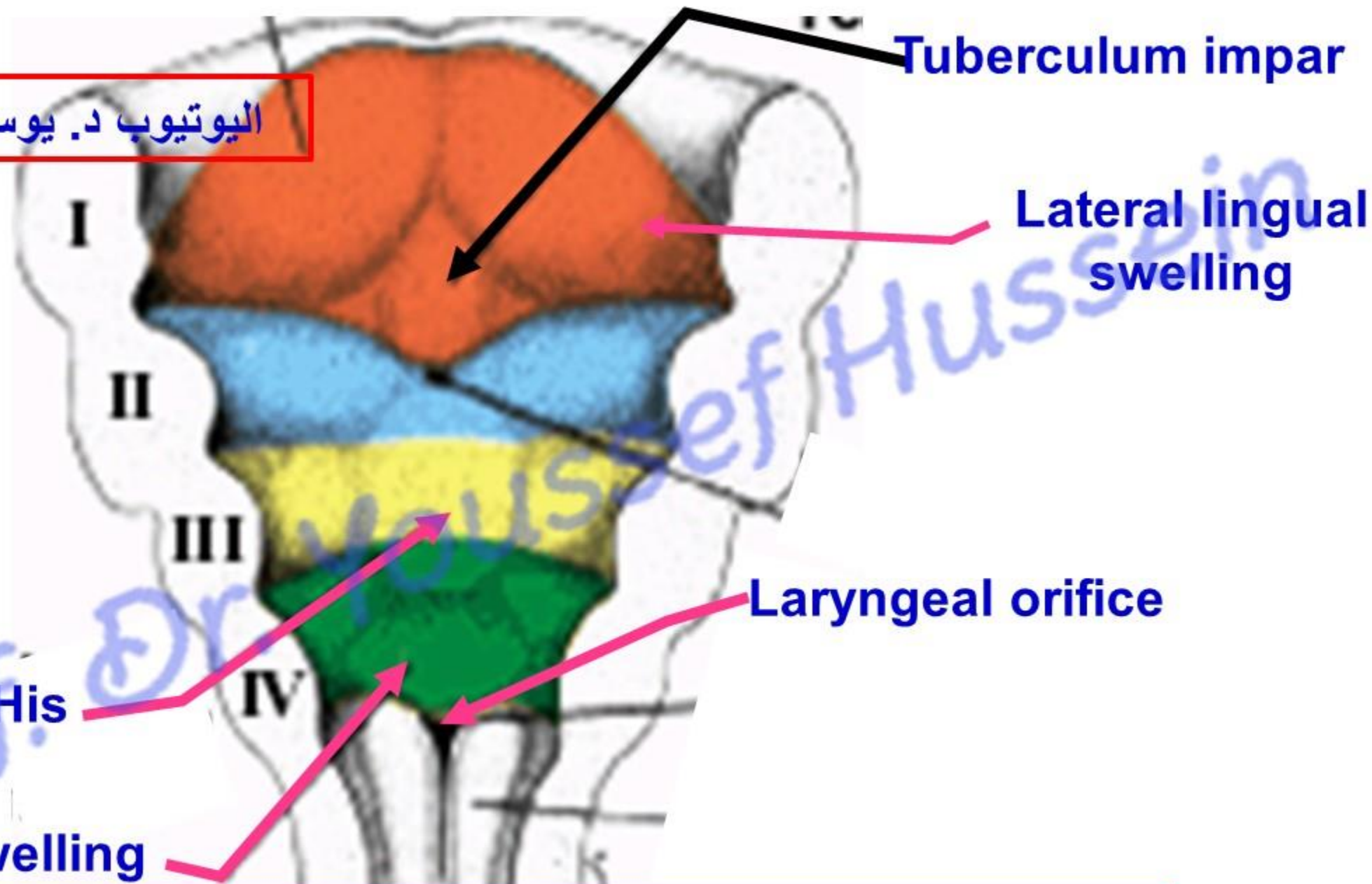
Foramen caecum

Anterior two third

Median sulcus

<https://www.youtube.com/@ProfDrYoussefHusseinAnatomy/playlists>

اليوثيوب د. يوسف حسين



Tuberculum impar

Lateral lingual swelling

Laryngeal orifice

Copula of His

Epiglottic swelling

<https://www.youtube.com/@ProfDrYoussefHusseinaAnatomy/playlists>

• **Development of the mucous membrane of the anterior 2/3 of the tongue:**

- **At 4<sup>th</sup> week 3 endodermal swellings** appears from 1<sup>st</sup> pharyngeal arches
- **1- A median swelling** called the **tuberculum impar**
- **2- Two lateral lingual swellings** proliferate and grow medially.
- In the midline, they fused together at **median sulcus** and completely covered tuberculum impar forming mucous membrane of anterior 2/3 of the tongue.
- **So the anterior 2/3 is supplied by Lingual nerve from posterior division of mandibular nerve.**

اليو تيوب د. يوسف حسين

<https://www.youtube.com/@ProfDrYoussefHusseinAnatomy/playlists>

- **Development of the mucous membrane of the posterior 1/3 of the tongue:**
- It develops as a large midline mass (**copula of His**) derived from **endoderm** of **2nd, 3<sup>rd</sup> and 4th** pharyngeal arches.
- The part of the **3<sup>rd</sup> arch** proliferates and migrates forward overlying the 2<sup>nd</sup> arch and forms **posterior 1/3 of the tongue that fused with anterior 2/3 by sulcus terminalis.**
- **So the posterior 1/3 is supplied by the glossopharyngeal nerve.**
  - **Development of the mucous membrane of the Root of the tongue;**
- **From** the part of the copula derived from the **4<sup>th</sup> pharyngeal arch**
- **So** it is supplied by the vagus nerve (internal laryngeal nerve).

<https://www.youtube.com/@ProfDrYoussefHusseinAnatomy/playlists>

## • Development of the muscles of the tongue:

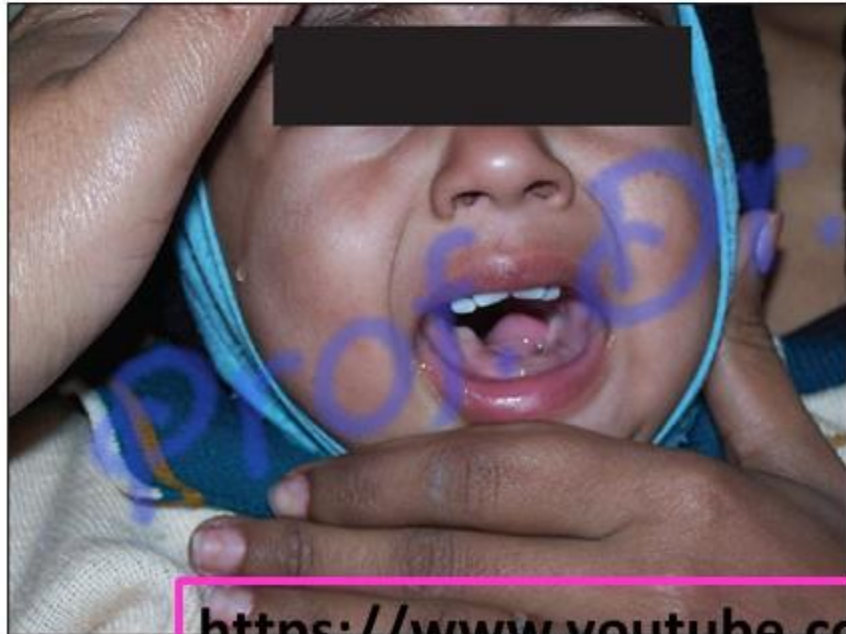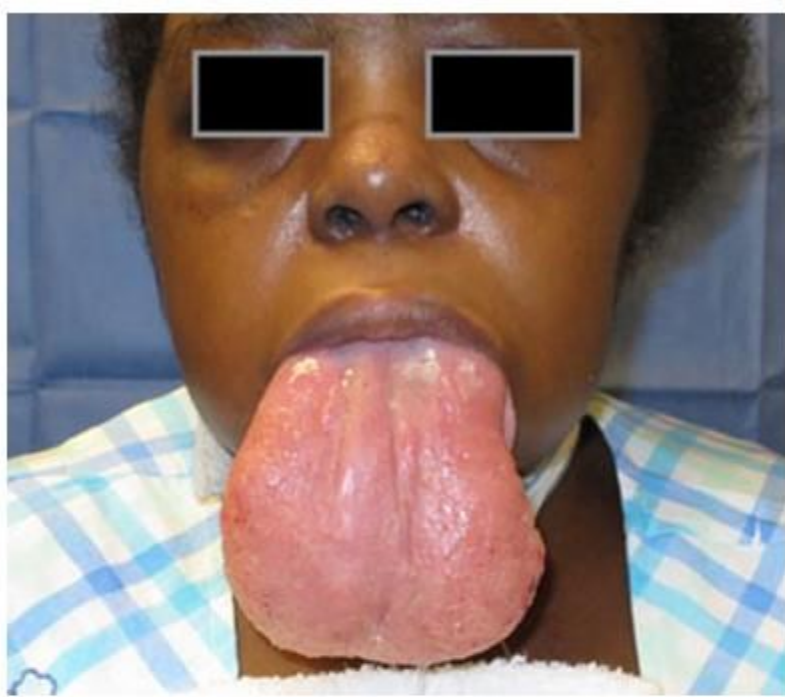- **The muscles of the tongue** are derived from the **occipital myotomes** except **palatoglossus** muscle that develop from the **mesoderm in situ**.
- **So** the muscles are supplied by the **hypoglossal nerve** except palatoglossal muscle supplied by **pharyngeal nerve plexus**

## Separation of the tongue

اليوثيوب د. يوسف حسين

- At first the tongue is adherent to the floor of the mouth, then a horse-shoe (C-shaped) groove called **alveololingual groove** separates the anterior 2/3 of tongue from the floor of the mouth except in the midline where the tongue is connected to the floor by the **frenulum of the tongue**.

<https://www.youtube.com/@ProfDrYoussefHusseinAnatomy/playlists>

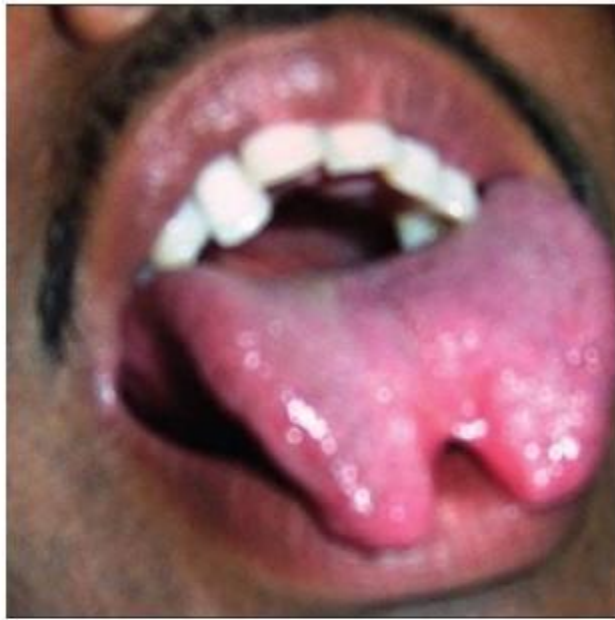

## \*\* Congenital anomalies of the tongue

- **A glossa:** failure of development of the tongue,
- **Macroglossia:** large sized tongue which protrudes from the mouth (as in mongolism and cretinism).
- **Microglossia:** small sized tongue

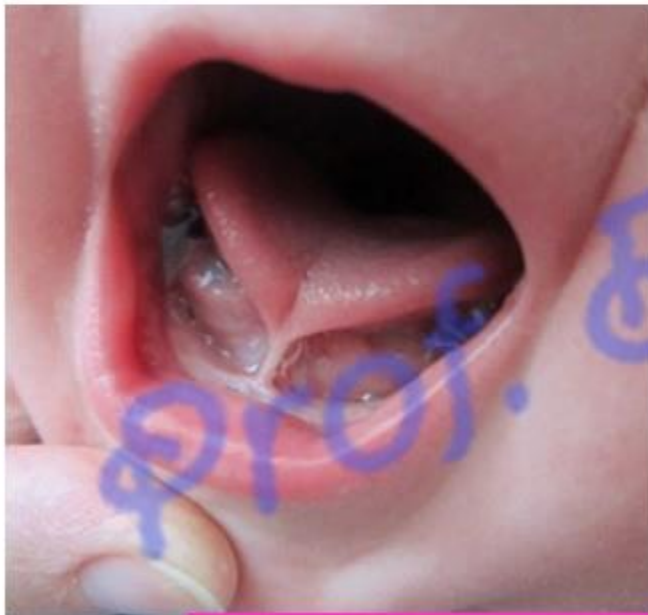اليو تيوب د. يوسف حسين

<https://www.youtube.com/@ProfDrYoussefHusseinaAnatomy/playlists>



- **Bifid tongue:** due to failure of fusion of the 2 lingual swellings.

- **Tongue-tie (Ankyloglossia):** the tongue is adherent to the floor of the mouth.



- **Short frenulum:** due to incomplete separation of tongue (common)
- **Long frenulum:** due to excess separation of the tongue. It causes the tongue to fall back and close the pharynx and larynx (suffocation).

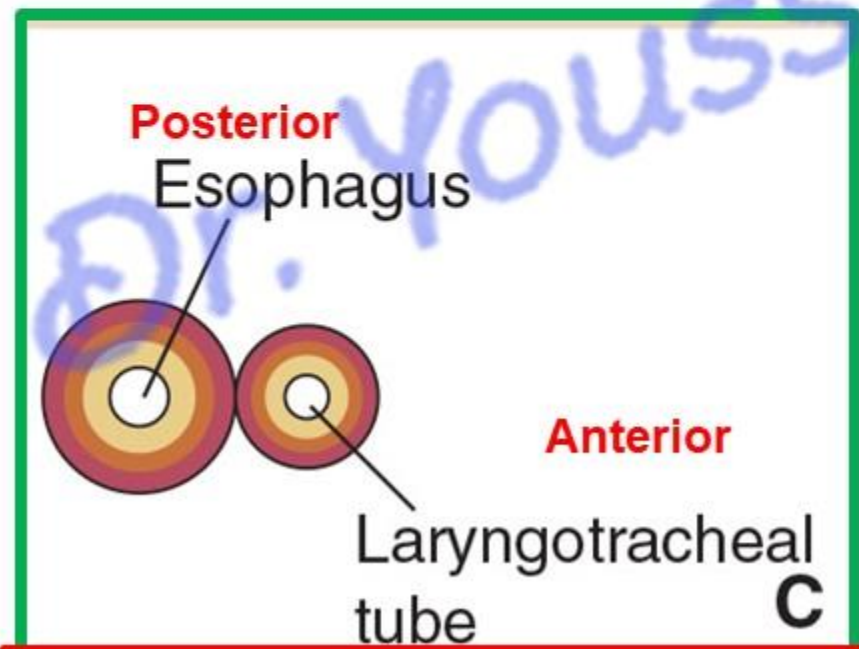
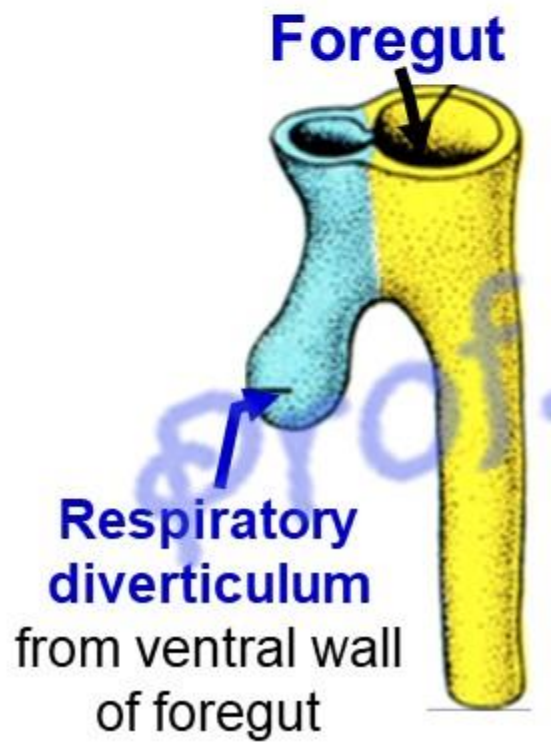
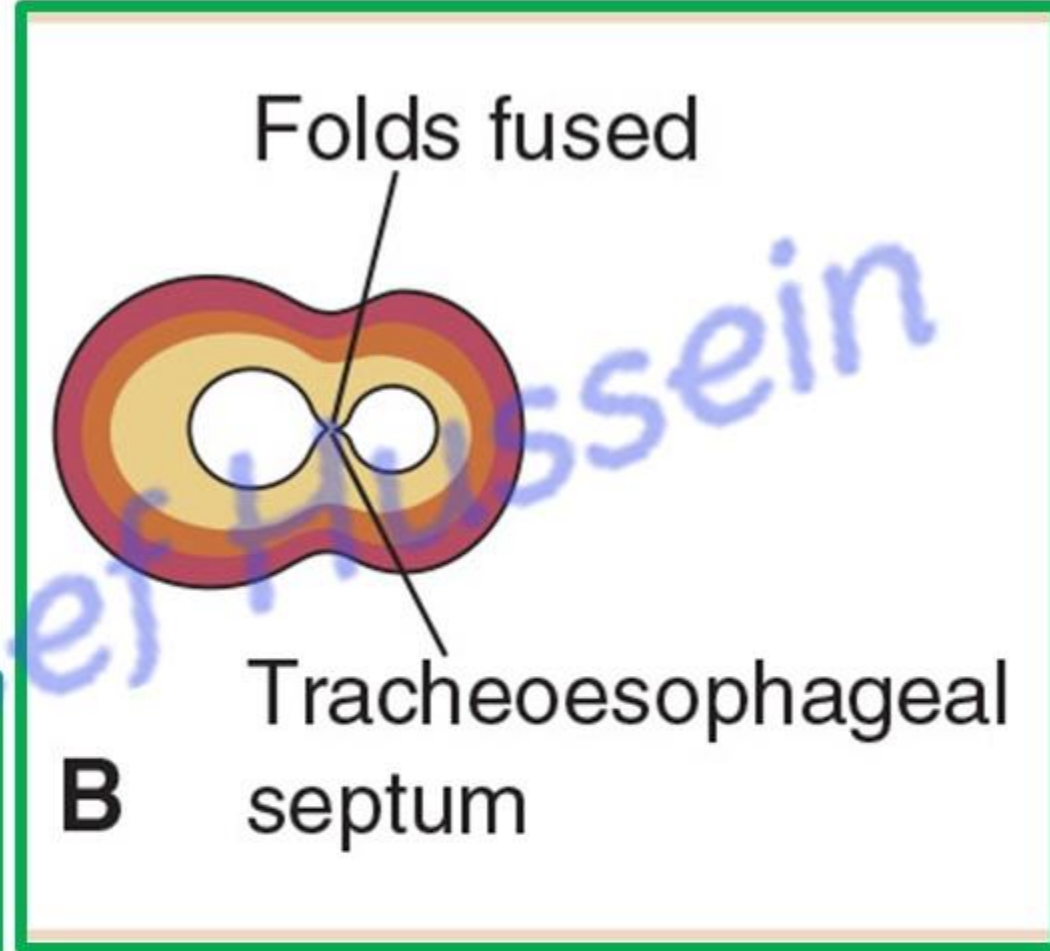
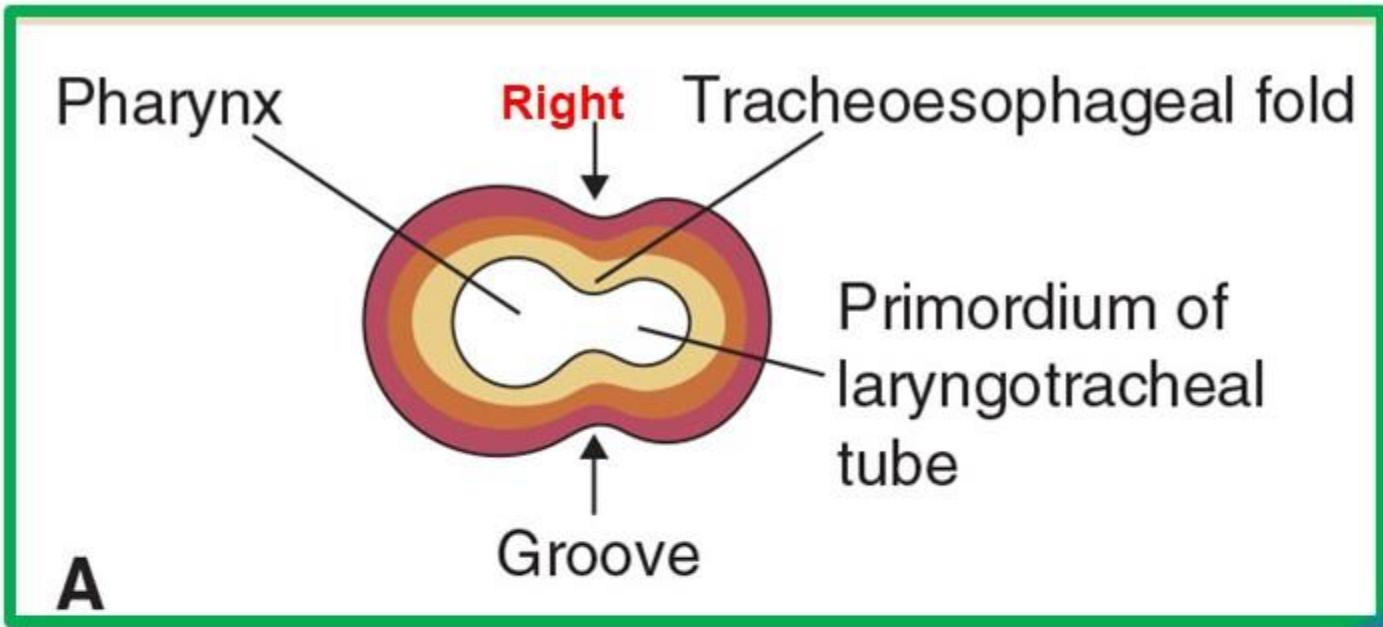
اليوثيوب د. يوسف حسين

البيوتوب د. يوسف حسين

dr\_youssefhussein@yahoo.com

# Development of Esophagus

Prof. Dr. Youssef Hussein Anatomy - YouTube



اليوثيوب د. يوسف حسين

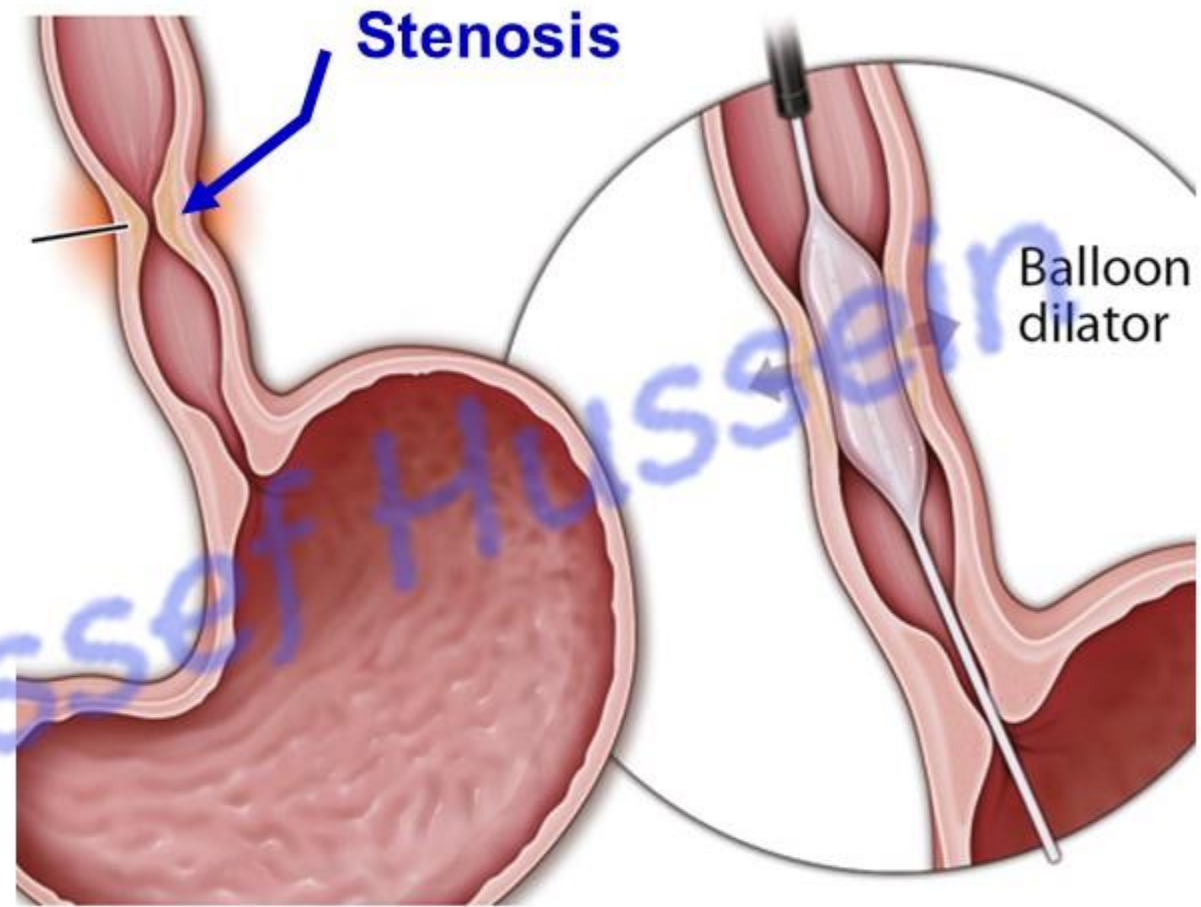
## **\*\* Congenital abnormalities of the esophagus**

- **Esophageal atresia (obstruction):** associated with polyhydramnios due to failure of swallowing of the amniotic fluid

- **Esophageal stenosis (narrow):** due to

a- Posterior displacement of tracheoesophageal septum.

b- Mechanical factors push posterior wall of the tube forward.



اليوتيوب د. يوسف حسين

- **Tracheoesophageal fistula:**

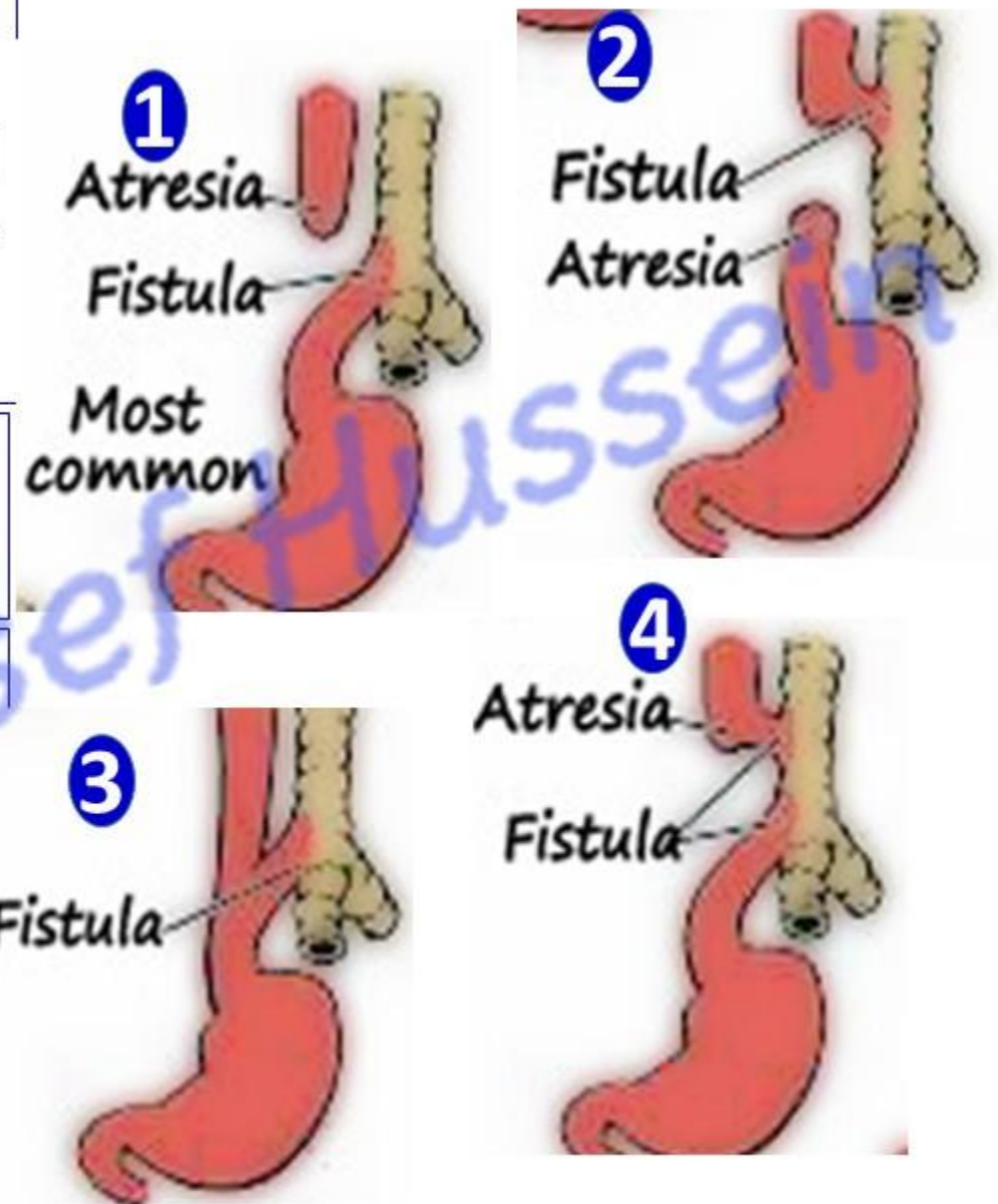
- An abnormal opening between esophagus and trachea caused by failure of complete closure of the tracheoesophageal septum.

1. **Proximal part** of esophagus ends as a **blind sac** and distal part continues with the trachea.

2- **Proximal part** of esophagus **continues** with trachea and distal part ends as blind sac.

3- Proximal and distal parts of **continue** with trachea by **single tube**.

4- Proximal and distal parts of esophagus **continue** with trachea separately by **double tubes**.



dr\_youssefhussein@yahoo.com

# Development of liver & Biliary system

اليوطيوب د. يوسف حسين

<https://www.youtube.com/@ProfDrYoussefHusseinAnatomy/playlists>

Gallbladder

Hepatic ducts

Common hepatic duct

Cystic duct

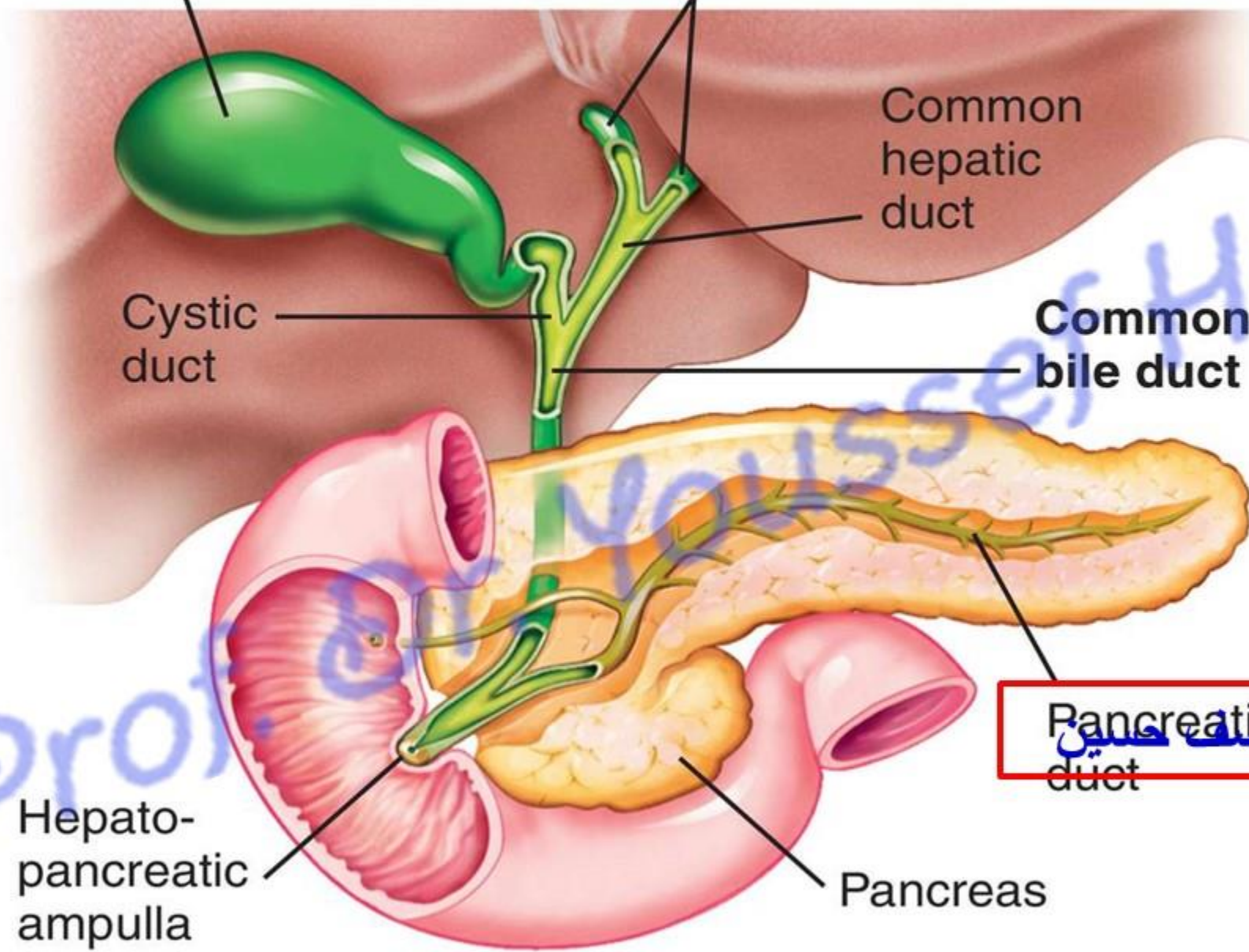
Common bile duct

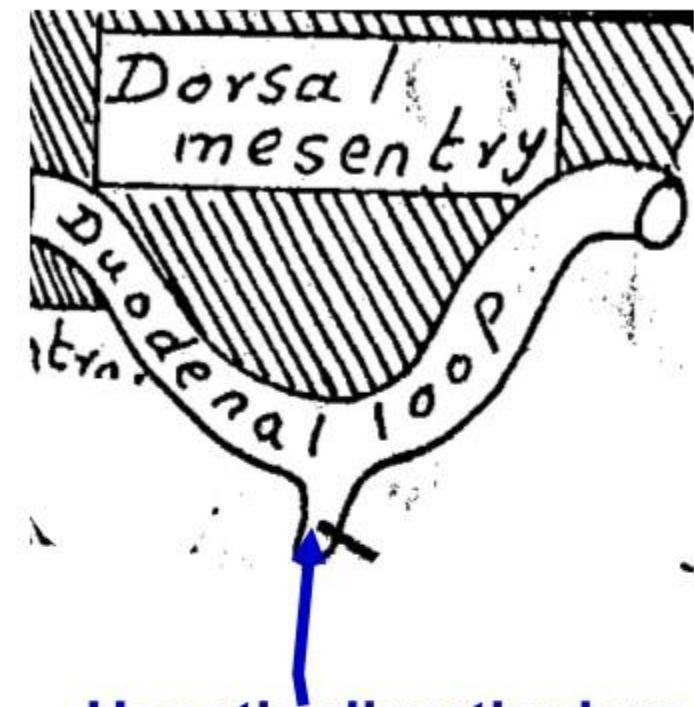
dr\_youssefhussain@yahoo.com

البيوتوب د. يوسف حسين  
Pancreatic duct

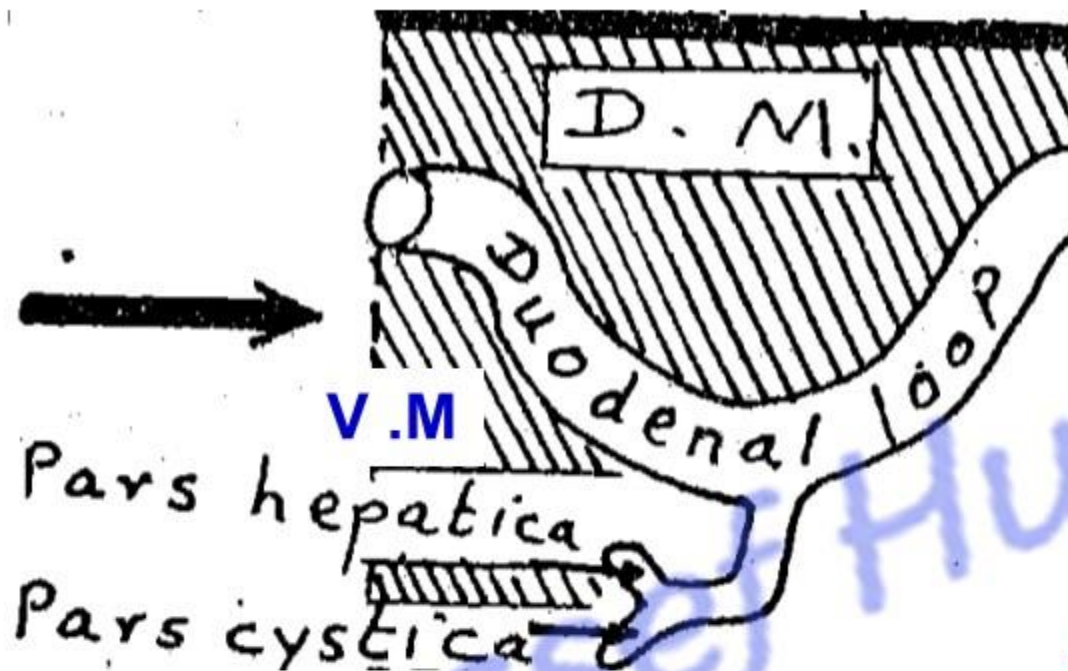
Hepato-pancreatic ampulla

Pancreas

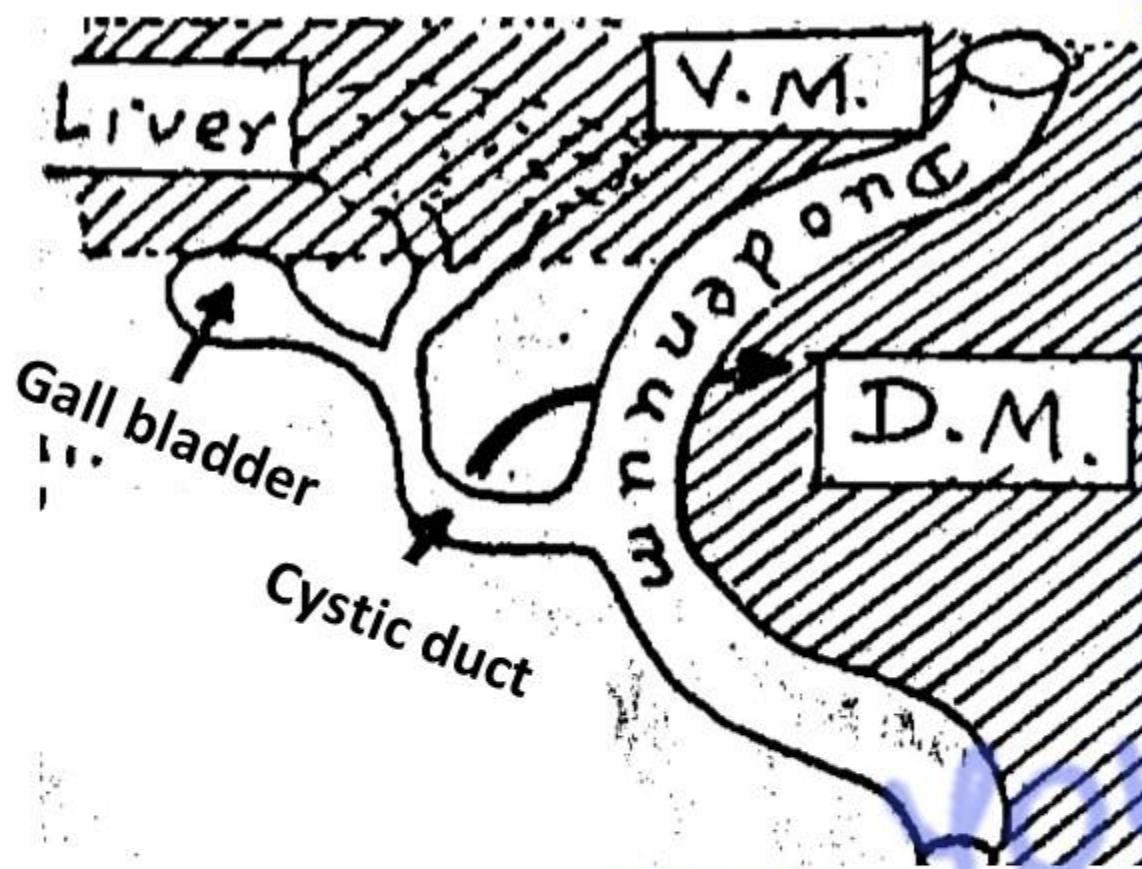




**Hepatic diverticulum** from the **ventral** wall of the duodenal loop by the 4th week of development



- **The diverticulum** grows ventrally and cranially into ventral mesentery.
- The diverticulum divides into 2 parts:
- **Cranial** part called **pars hepatica**
- **Caudal** part called **pars cystica.**



## I- Development of the liver (Pars Hepatica)

- \* The cranial end of the pars hepatica divides into 2 branches that form **right and left hepatic ducts**.
- \* The cranial ends of ducts divide to form hepatic cells and intrahepatic biliary tree.
- \* The hepatic cells are separated by **blood sinusoids** developed from absorbed umbilical and vitelline veins.
- \* The blood sinusoids are lined by mesenchymal cells and large phagocytic cells (Kupffer cells).
- \* The connective tissue stroma and fibrous capsule derived from the surrounding mesoderm

## II- Development of the gall bladder (Pars cystica)

- Distal part** is dilated and forms **gall bladder**.
- Proximal part** remains narrow and forms **cystic duct**.

### III- Development of the common bile duct:

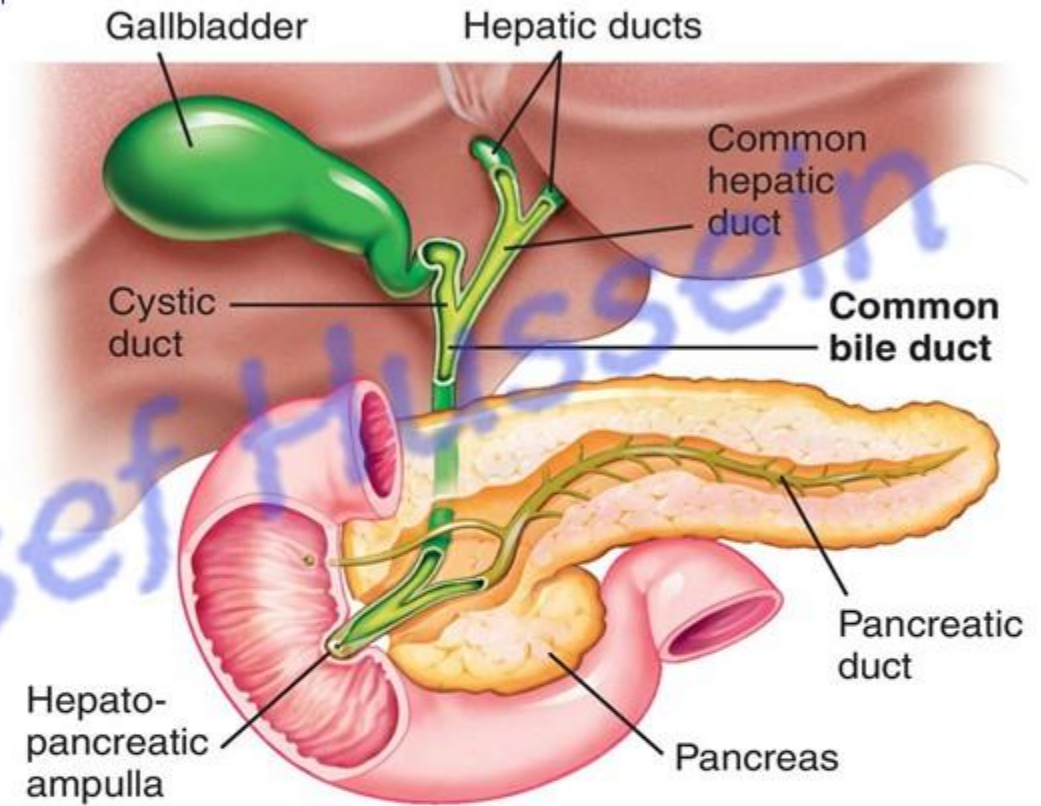
- The proximal part of the hepatic diverticulum forms the common bile duct.

**\*\* At first**, the common bile duct opens in the ventral wall of the duodenum.

- After **rotation of the duodenal loop 90° (clockwise) and unequal growth of its walls**,

a) The opening shifts to the dorsomedial wall of the 2<sup>nd</sup> part of the duodenum.

b) The common bile duct passes behind the first part of the duodenum



[dr\\_youssefhussein@yahoo.com](mailto:dr_youssefhussein@yahoo.com)

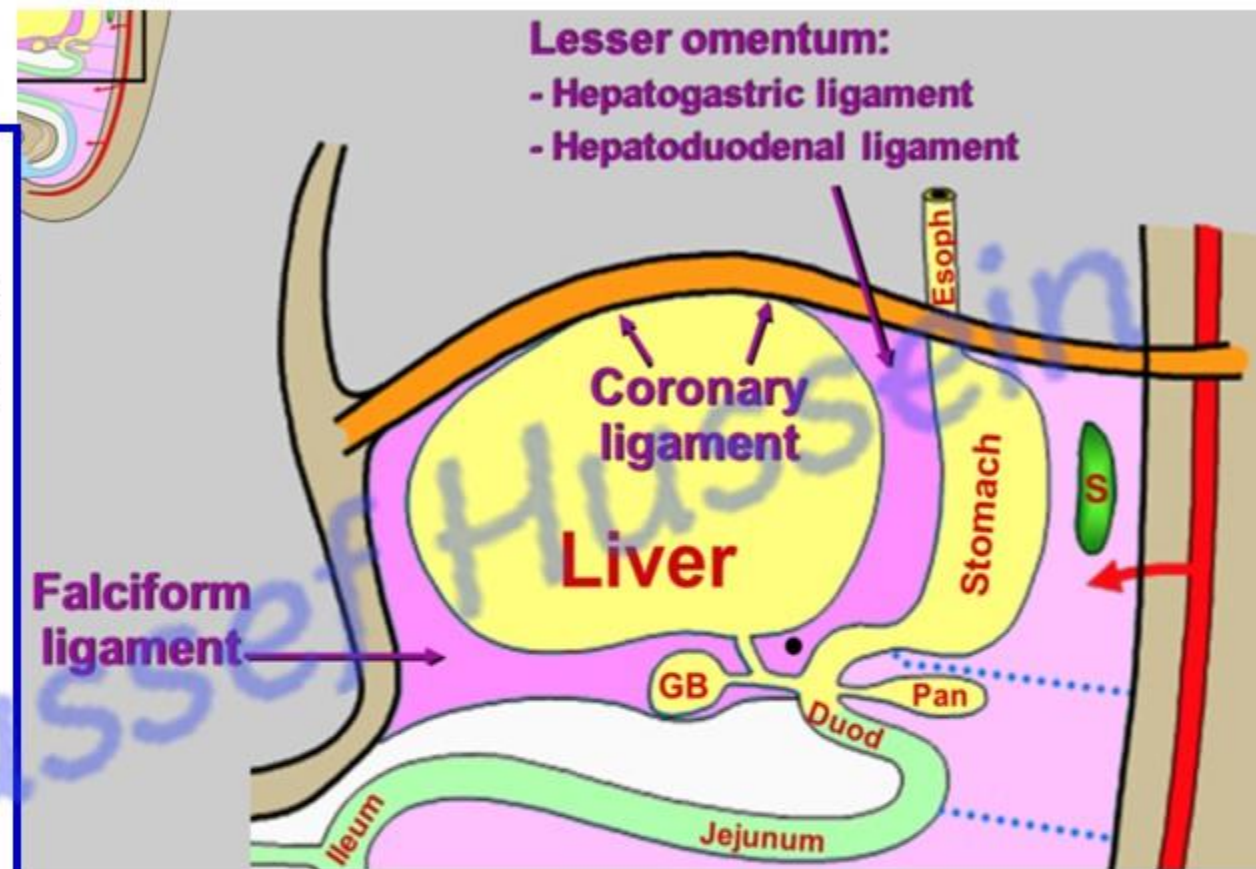
**\*\* Development of ligaments of liver:**

- Development of the liver between the layers of the **ventral mesentery** divides it into:

**a- Ventral part** connects liver to anterior abdominal wall (**falciform ligament**).

**b- Dorsal part** connects liver to stomach (lesser omentum)

**c- Cranial part** forming triangular and coronary ligaments



[dr\\_youssefhussein@yahoo.com](mailto:dr_youssefhussein@yahoo.com)

<https://www.youtube.com/@ProfDrYoussefHusseinAnatomy/playlists>

## **\*\* Congenital Anomalies of the liver and biliary system:**

- I. Agenesis or hypo-genesis of the liver:** due to failure of formation of the hepatic diverticulum or due to incomplete development of the hepatic bud.
- II. Abnormal number of the liver lobes:** due to abnormal division of the pars hepatica.
- III. Agenesis of the gall bladder:** failure of development of the cystic bud
- IV. Double gall bladder:** abnormal division of the cystic bud into 2 parts.
- V. Mobile gall bladder:** the gall bladder is completely separated from the liver and completely covered with peritoneum.
- VI. Atresia (narrowing) of the biliary ducts:** due to failure of their canalization. It is associated later with congenital jaundice


[dr\\_youssefhussein@yahoo.com](mailto:dr_youssefhussein@yahoo.com)

<https://www.youtube.com/@ProfDrYoussefHusseinAnatomy/playlists>

[https://www.youtube.com/channel/UCVSNqbibj9UWYaJdd\\_cn0PQ](https://www.youtube.com/channel/UCVSNqbibj9UWYaJdd_cn0PQ)

يُمنع أخذ السلايدات بدون  
إذن المحرر و اي اجراء  
يخالف ذلك يقع تحت طائلة  
المسؤولية القانونية  
جميع المعلومات للاستخدام  
التعليمي فقط

اليوتيوب د. يوسف حسين



<https://www.youtube.com/@ProfDrYoussefHusseinAnatomy/playlists>