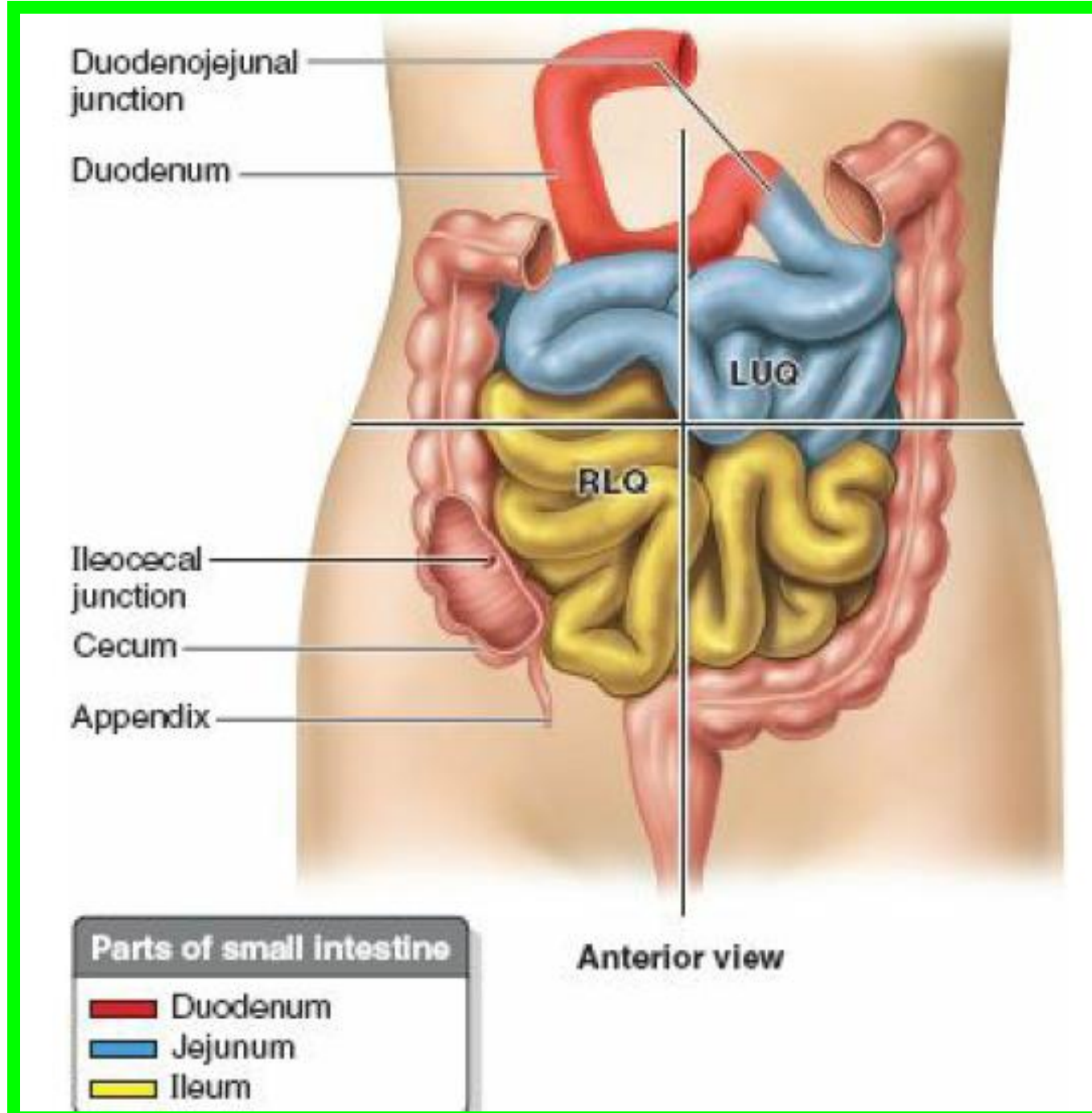


# ***THE SMALL INTESTINE***

***Dr. Aiman Qais Afar***  
***Surgical Anatomist***

***College of Medicine / University of Mutah***  
***2025-2026***

***Tuesday 7 April 2026***

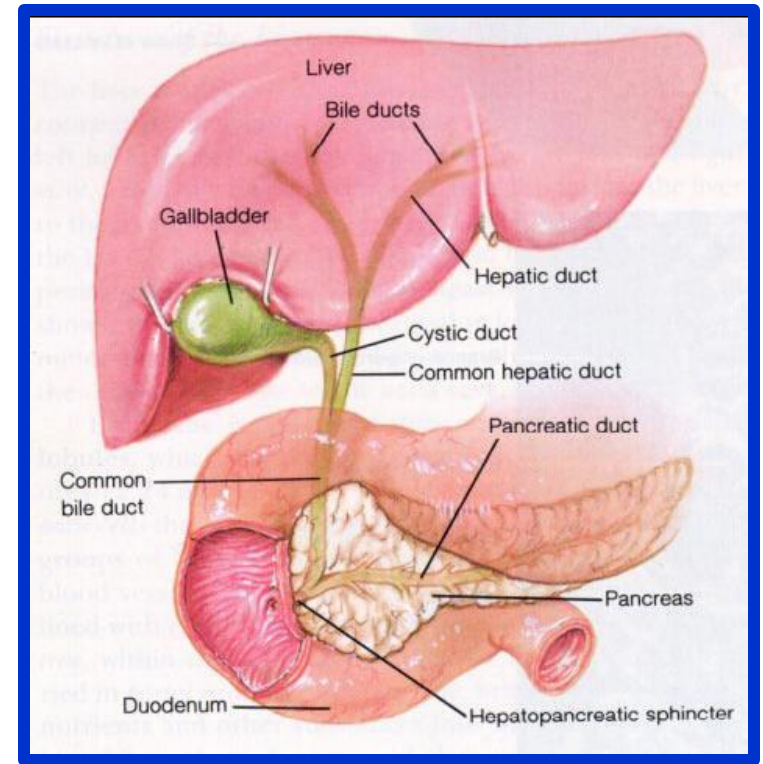


# Small Intestine

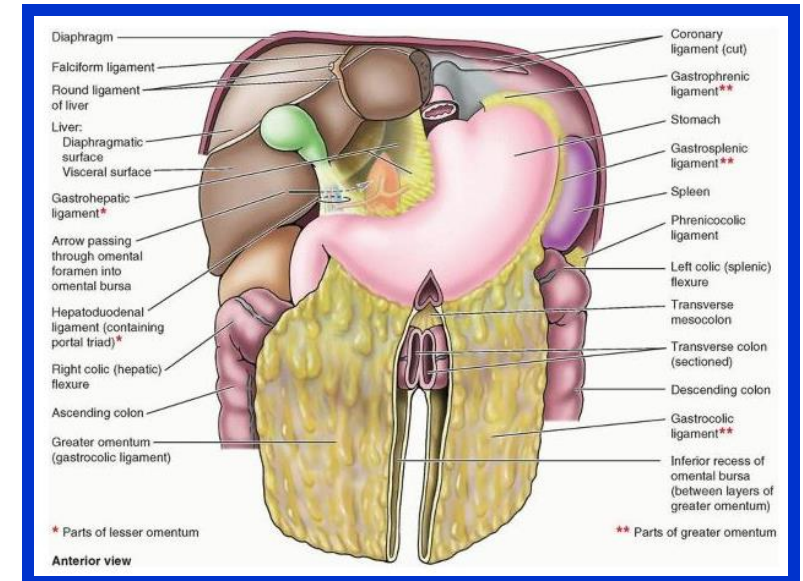
Dr. Aiman AL-Maathydi  
Tuesday 7 April 2026

## Duodenum

- ❖ The duodenum is a **C-shaped tube**, about **10 in. (25 cm)** long, which joins **the stomach to the jejunum**.
- ❖ It receives the openings of **the bile** and **pancreatic ducts**. The duodenum curves around the head of the pancreas



**The first inch (2.5 cm)** of the duodenum resembles the stomach in that it is covered on its anterior and posterior surfaces with peritoneum and has **the lesser omentum** attached to its upper border and **the greater omentum** attached to its lower border



# Duodenum

The remainder of the duodenum is retroperitoneal, being only partially covered by peritoneum.

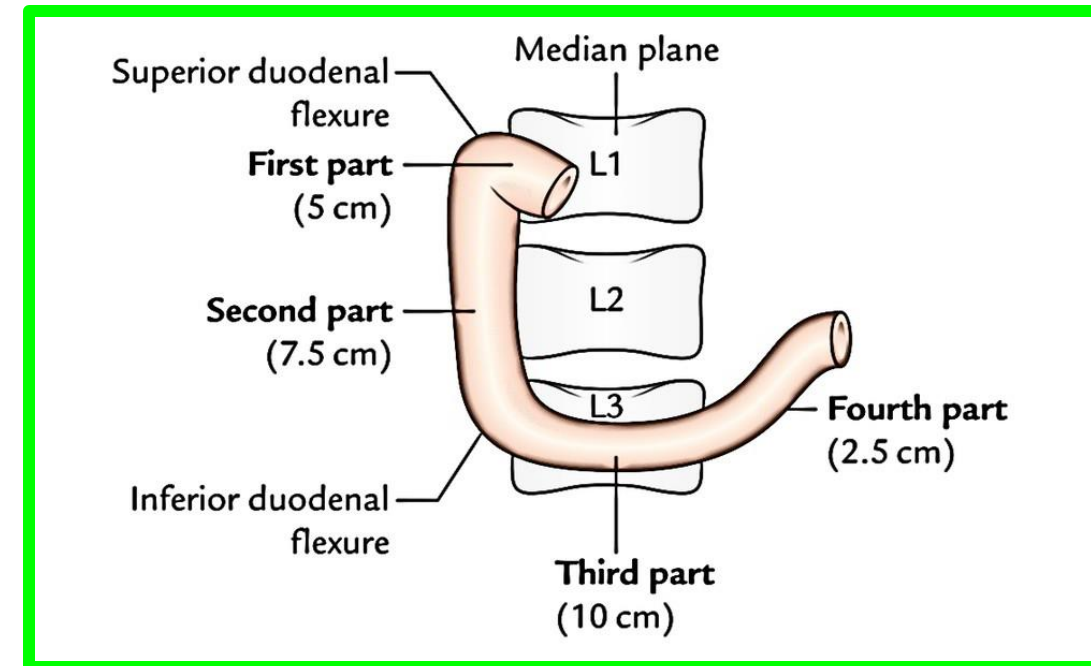
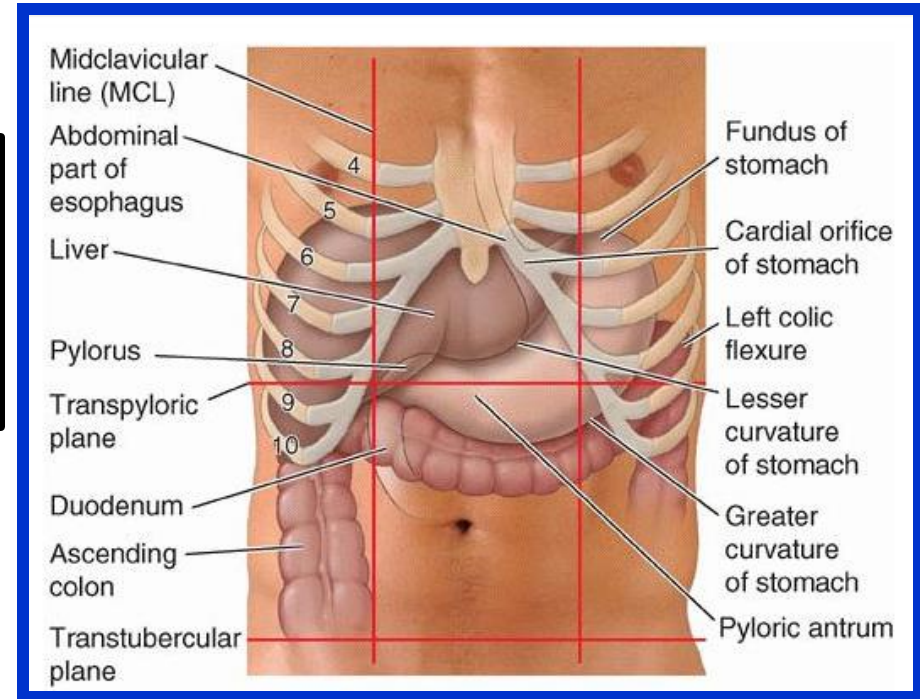
## Parts of the Duodenum

❖ The duodenum is situated in the epigastric and umbilical regions and, for purposes of description, is divided into four parts:

### □ First Part of the Duodenum

begins at the pylorus and runs upward and backward on the transpyloric plane at the level of the first lumbar vertebra.

The relations of this part are as follows:



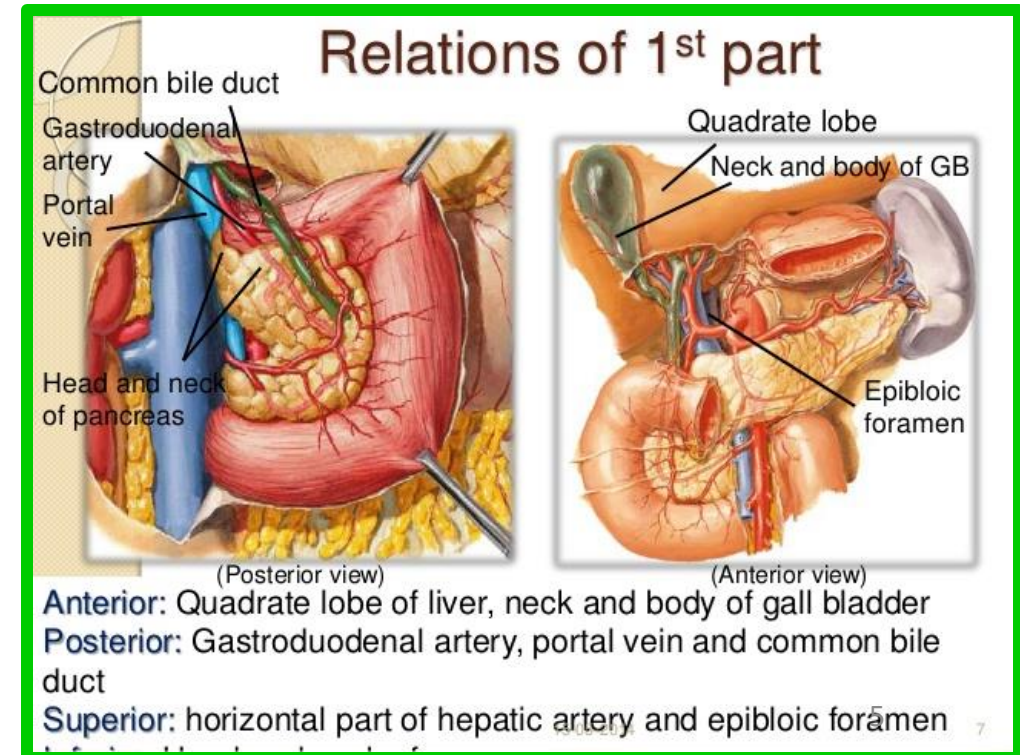
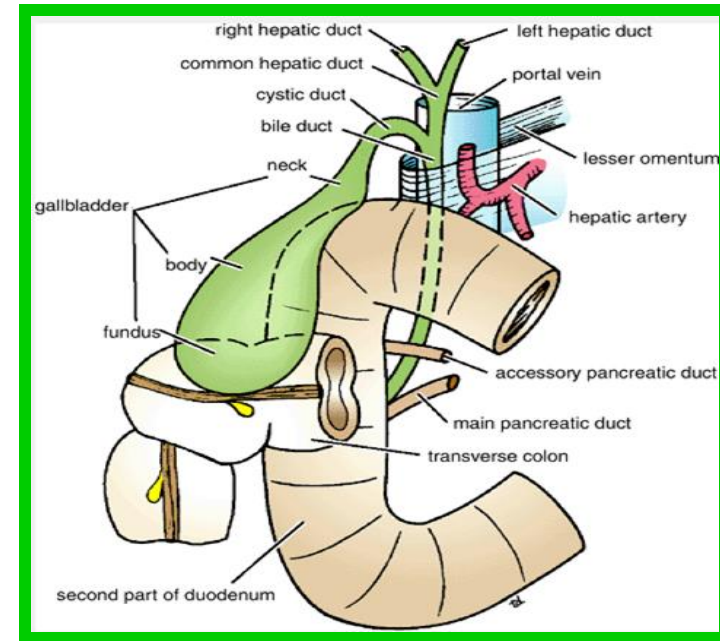
# Duodenum

**Anteriorly:** The quadrate lobe of the liver and the gallbladder

**Posteriorly:** The lesser sac (first inch only), the gastroduodenal artery, the bile duct and portal vein, and the inferior vena cava.

**Superiorly:** The entrance into the lesser sac (the epiploic foramen)

**Inferiorly:** The head of the pancreas.



Dr. Aiman AL-Maathydi

Tuesday 7 April 2026

# Duodenum

Dr. Aiman AL-Maathydi

Tuesday 7 April 2026

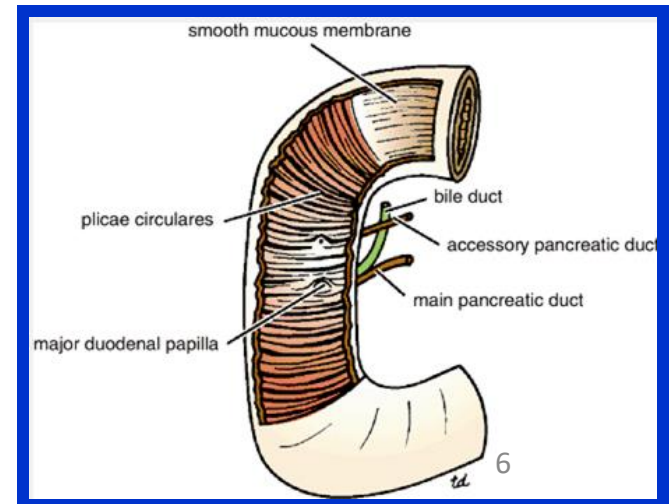
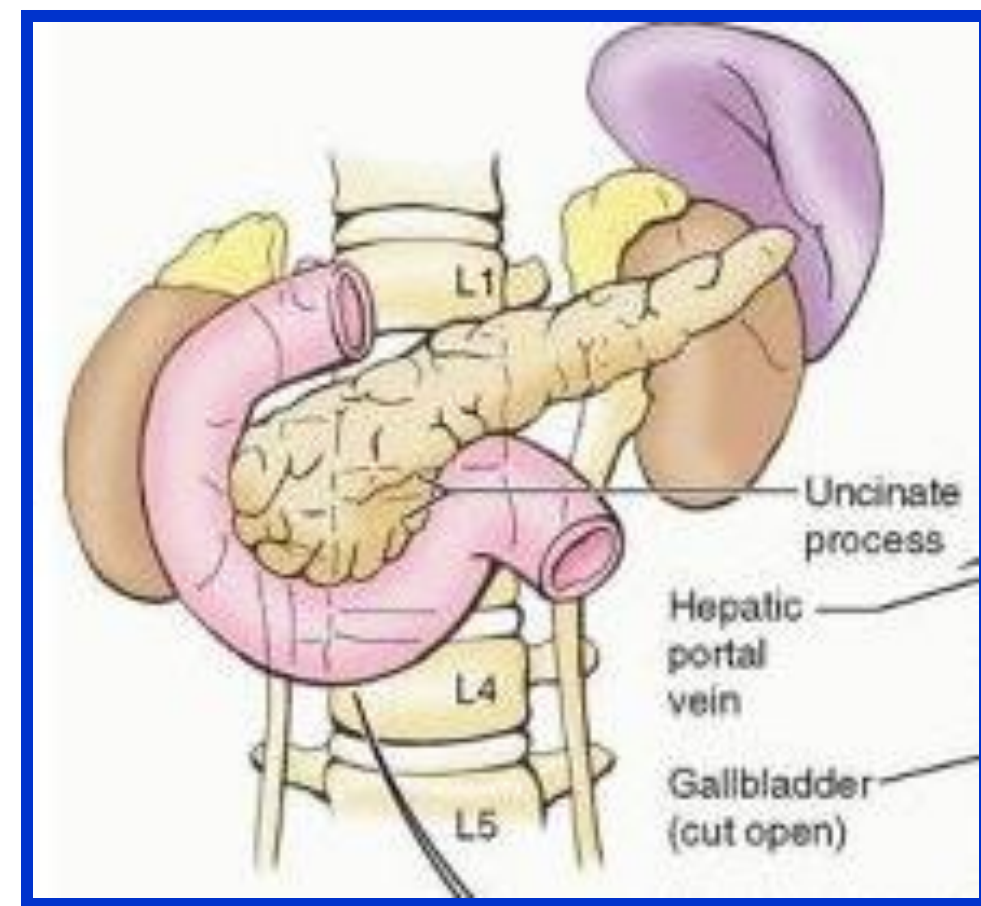
## ❑ Second Part of the Duodenum

❖ Runs vertically downward in front of the hilum of the right kidney on the right side of the second and third lumbar vertebrae.

❖ About halfway down its medial border, the bile duct and the main pancreatic duct pierce the duodenal wall

❖ They unite to form the ampulla that opens on the summit of the major duodenal papilla.

❖ The accessory pancreatic duct, if present, opens into the duodenum a little higher up on the minor duodenal papilla.



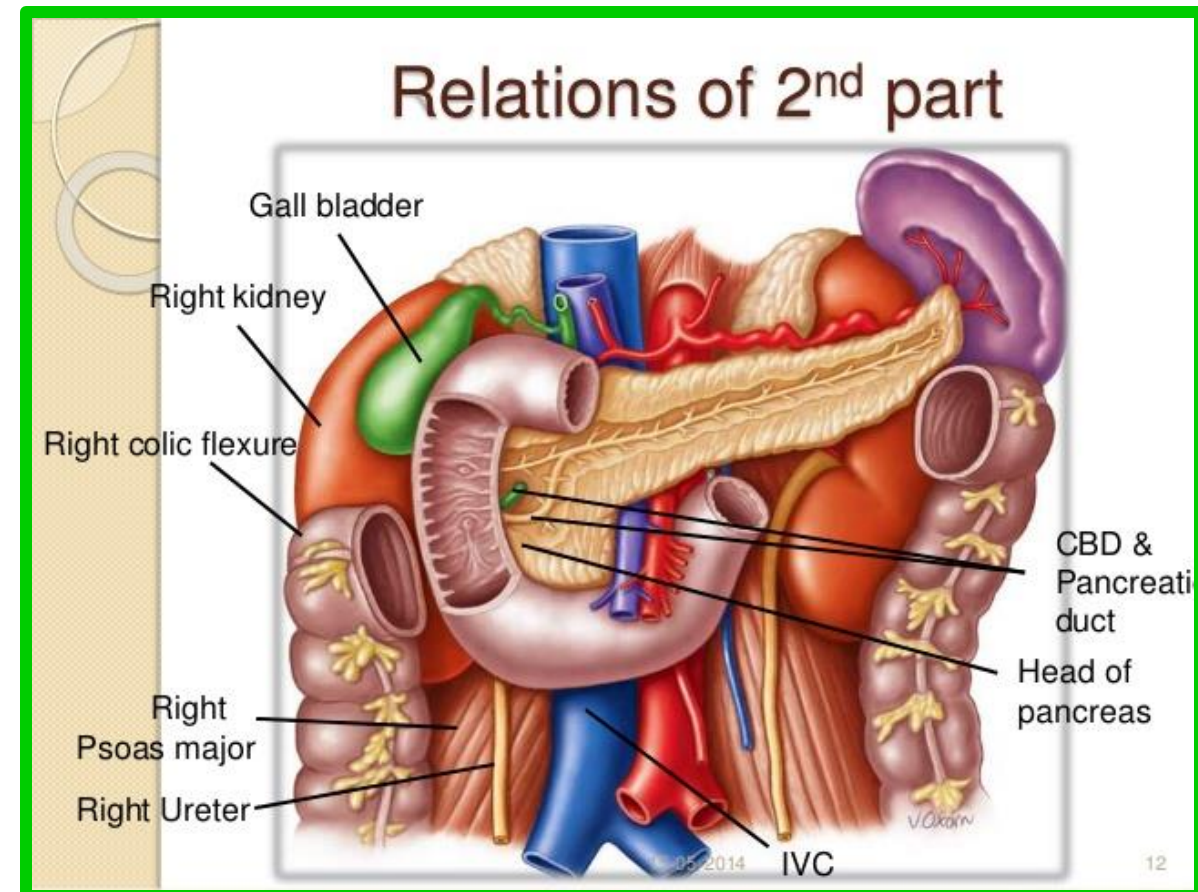
# Duodenum

7

Dr. Aiman AL-Maathydi  
Tuesday 7 April 2026

The relations 2<sup>nd</sup> part are as follows:

- **Anteriorly:** The fundus of the gallbladder and the right lobe of the liver, the transverse colon, and the coils of the small intestine
- **Posteriorly:** The hilum of the right kidney and the right ureter.
- **Laterally:** The ascending colon, the right colic flexure, and the right lobe of the liver.
- **Medially:** The head of the pancreas, the bile duct, and the main pancreatic duct.





# Duodenum

## Fourth Part of the Duodenum

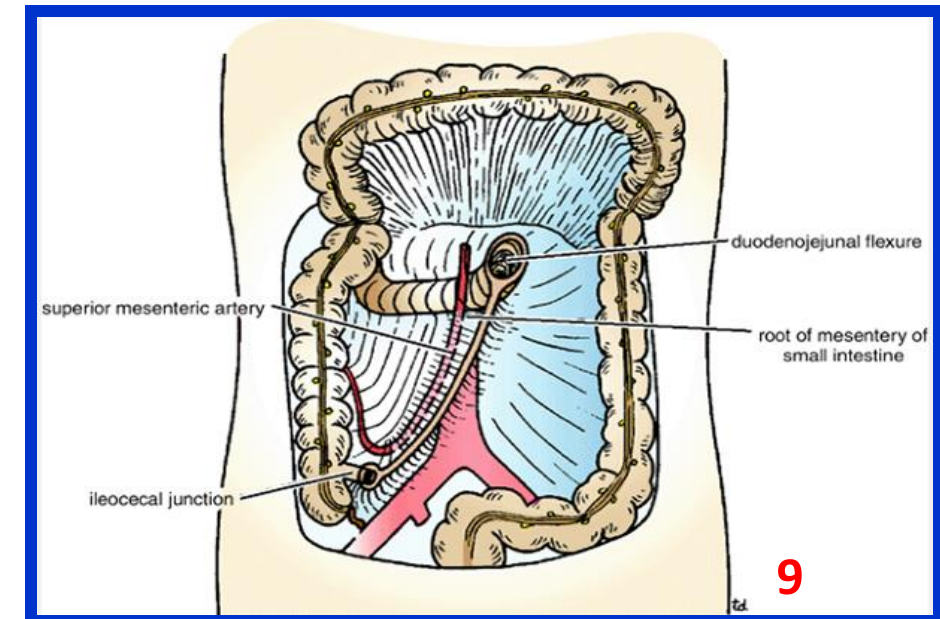
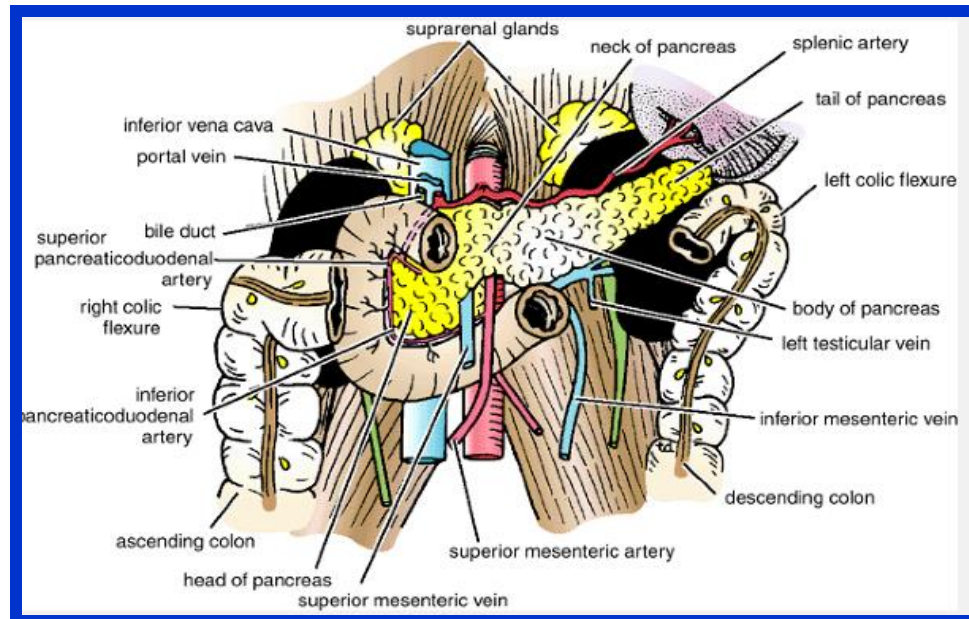
runs upward and to the left to **the duodenojejunal flexure**.

The flexure is held in position by a peritoneal fold, **the ligament of Treitz**, which is attached to the right crus of the diaphragm.

**The relations are as follows:**

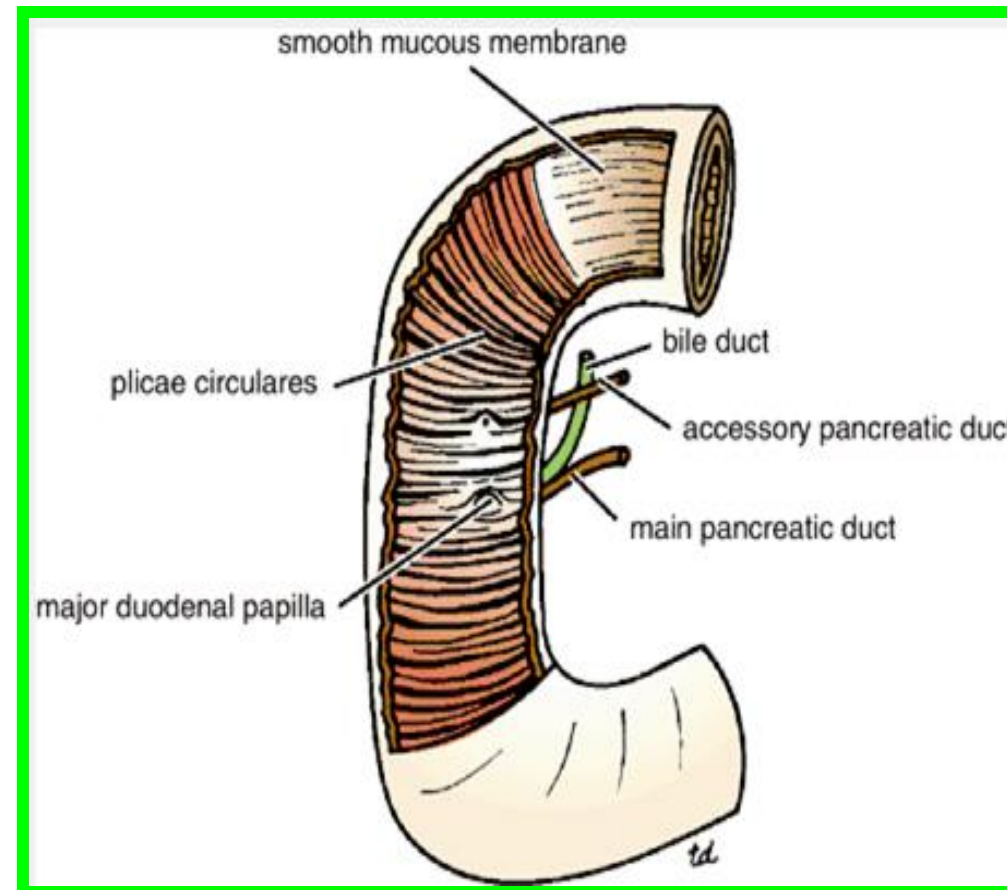
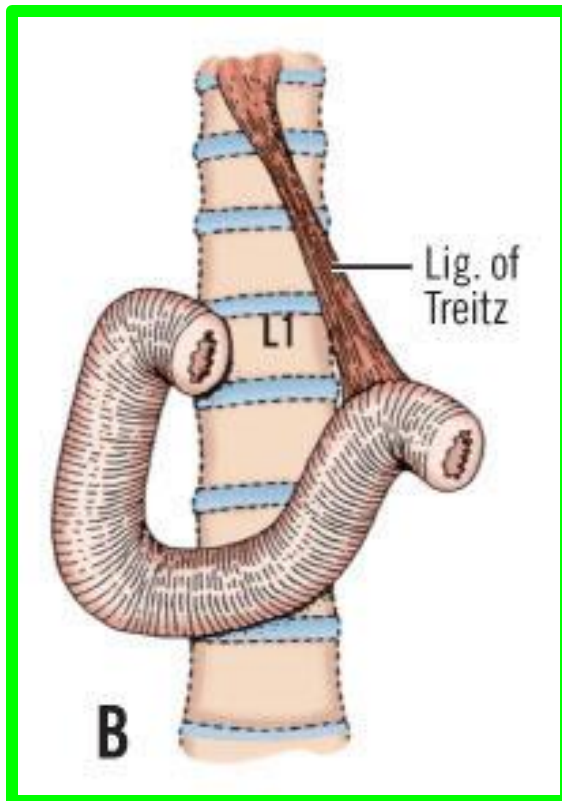
**Anteriorly:** The **beginning of the root of the mesentery** and **coils of jejunum**

**Posteriorly:** The **left margin of the aorta** and the **medial border of the left psoas muscle**



## Mucous Membrane and Duodenal Papillae

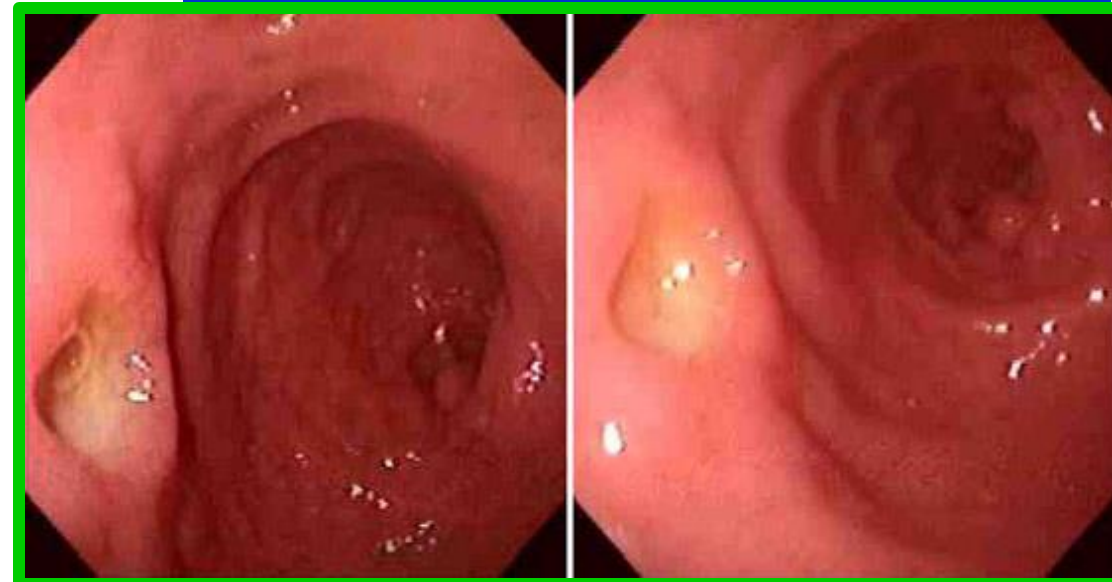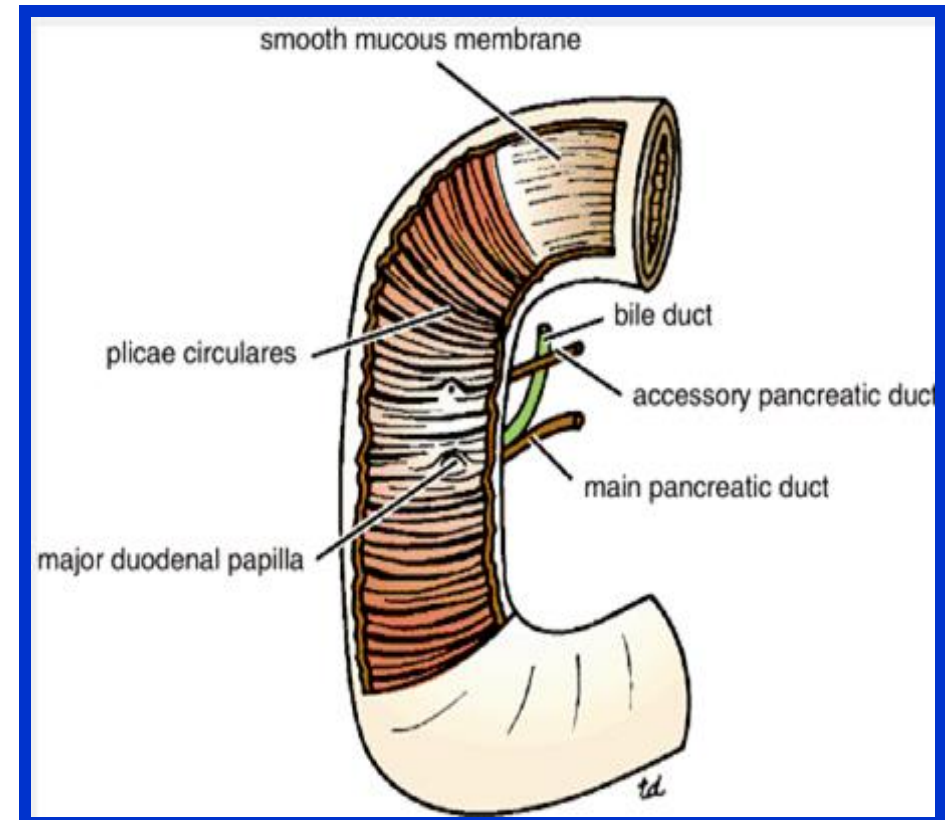
- ❖ The mucous membrane of the duodenum is thick.
- ❖ In the first part of the duodenum it is smooth.
- ❖ In the remainder of the duodenum it is thrown into numerous circular folds called **the plicae circulares**.



# Duodenum

❖ At the site where **the bile duct** and **the main pancreatic duct** pierce the medial wall of the second part is a small, rounded elevation called the **major duodenal papilla**

❖ **The accessory pancreatic duct**, if present, opens into the duodenum on a smaller papilla about 0.75 in. (1.9 cm) above **the major duodenal papilla** called **minor duodenal papilla**.



Dr. Aiman AL-Maathydi

Tuesday 7 April 2026

# Duodenum

## Arteries

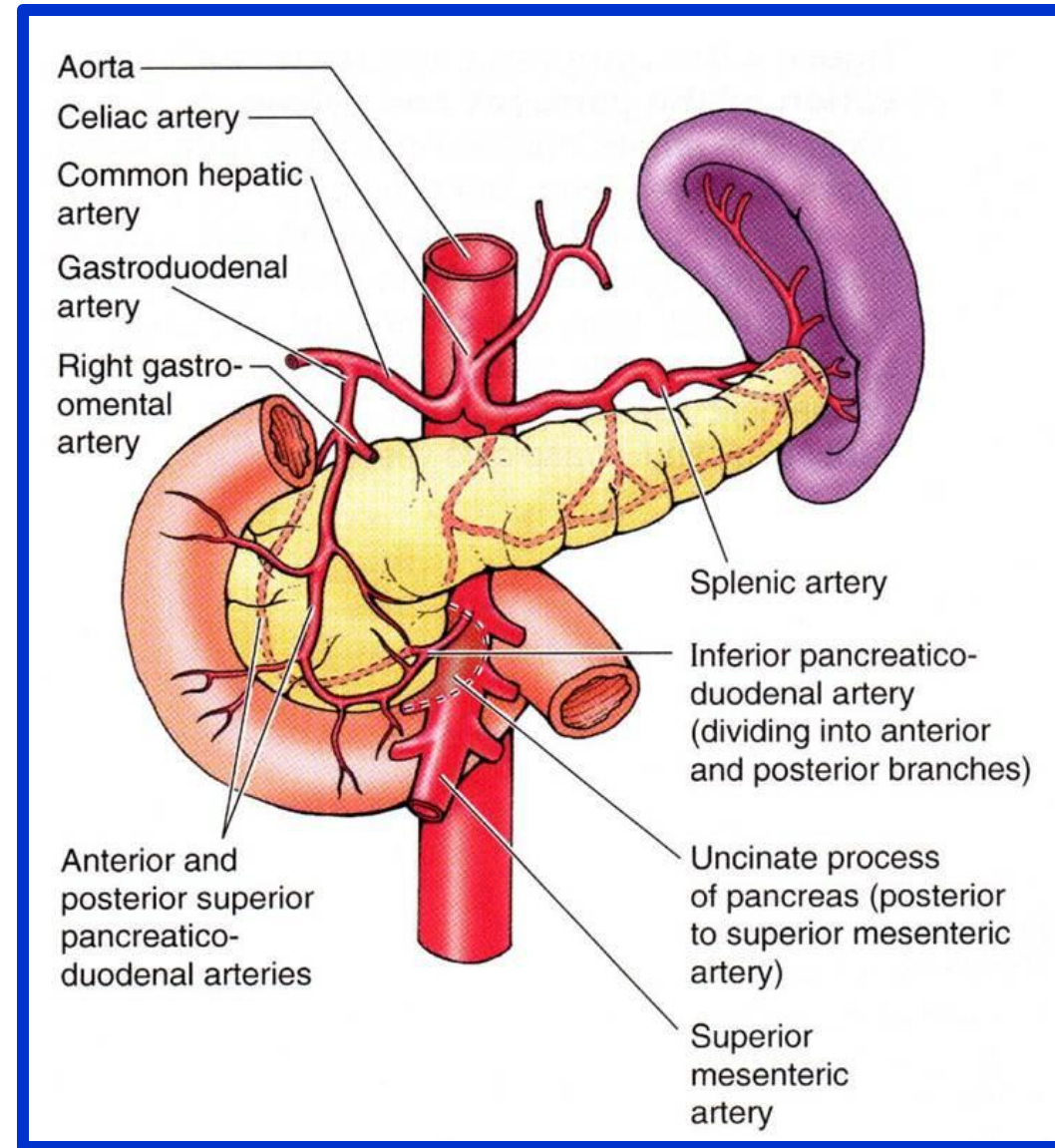
❖ The upper half is supplied by the **superior pancreaticoduodenal artery**, a branch of the **gastroduodenal artery**.

❖ The lower half is supplied by the **inferior pancreaticoduodenal artery**, a branch of the **superior mesenteric artery**.

## Veins:

The **superior pancreaticoduodenal vein** drains into the **portal vein**

The **inferior vein** joins the **superior mesenteric vein**.



# Duodenum

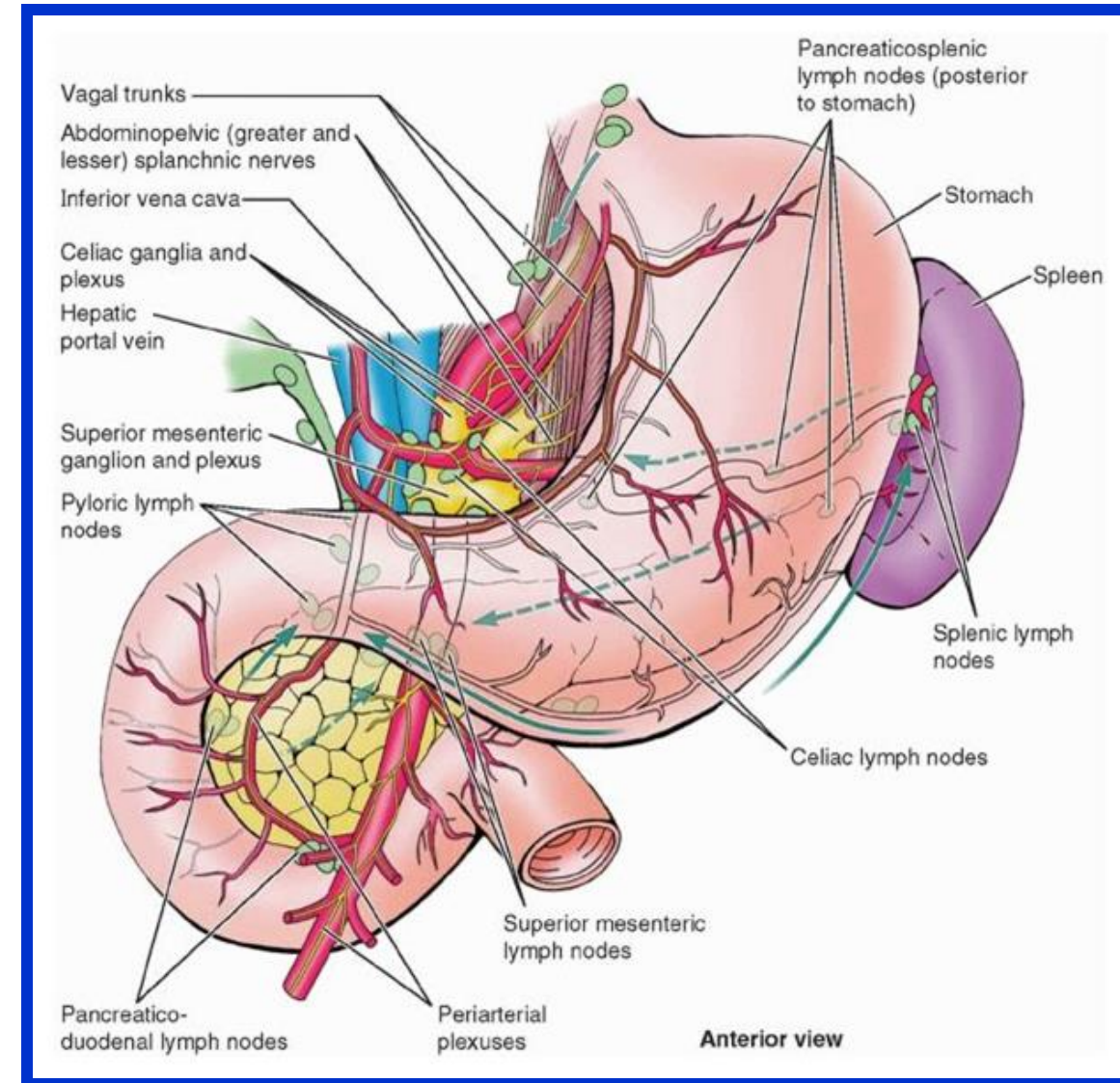
## Lymph Drainage

The lymph vessels follow the arteries and drain upward via **pancreaticoduodenal nodes** to the **gastroduodenal nodes** and then to the **celiac nodes** and

Downward via **pancreaticoduodenal nodes** to the **superior mesenteric nodes** around the origin of the **superior mesenteric artery**.

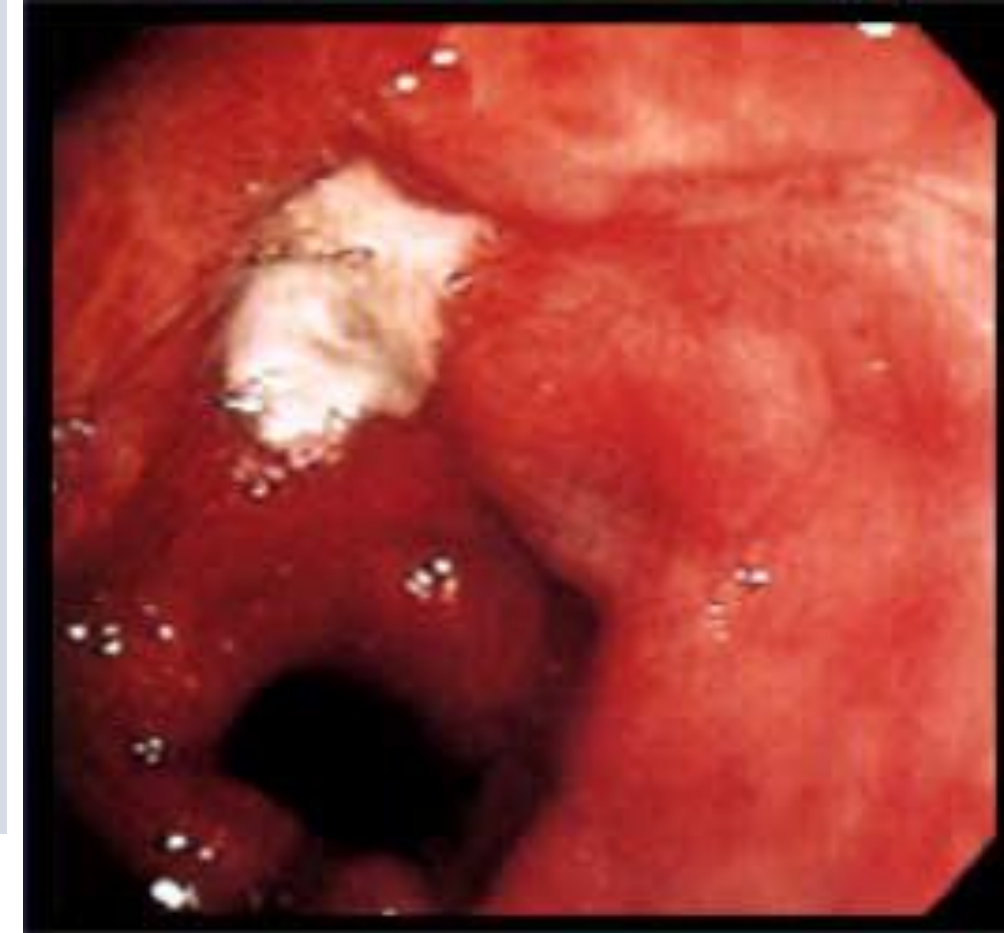## Nerve Supply

The nerves are derived from **sympathetic** from the **celiac** and **superior mesenteric plexuses** and **parasympathetic (vagus)** nerves



**Duodenal ulcers (peptic ulcers)** are inflammatory erosions of the duodenal mucosa. Most (**65%**) duodenal ulcers occur in the posterior wall of the superior part of the duodenum within **3 cm** of the pylorus.

Occasionally, an ulcer perforates the duodenal wall, permitting the contents to enter the peritoneal cavity and causing peritonitis.



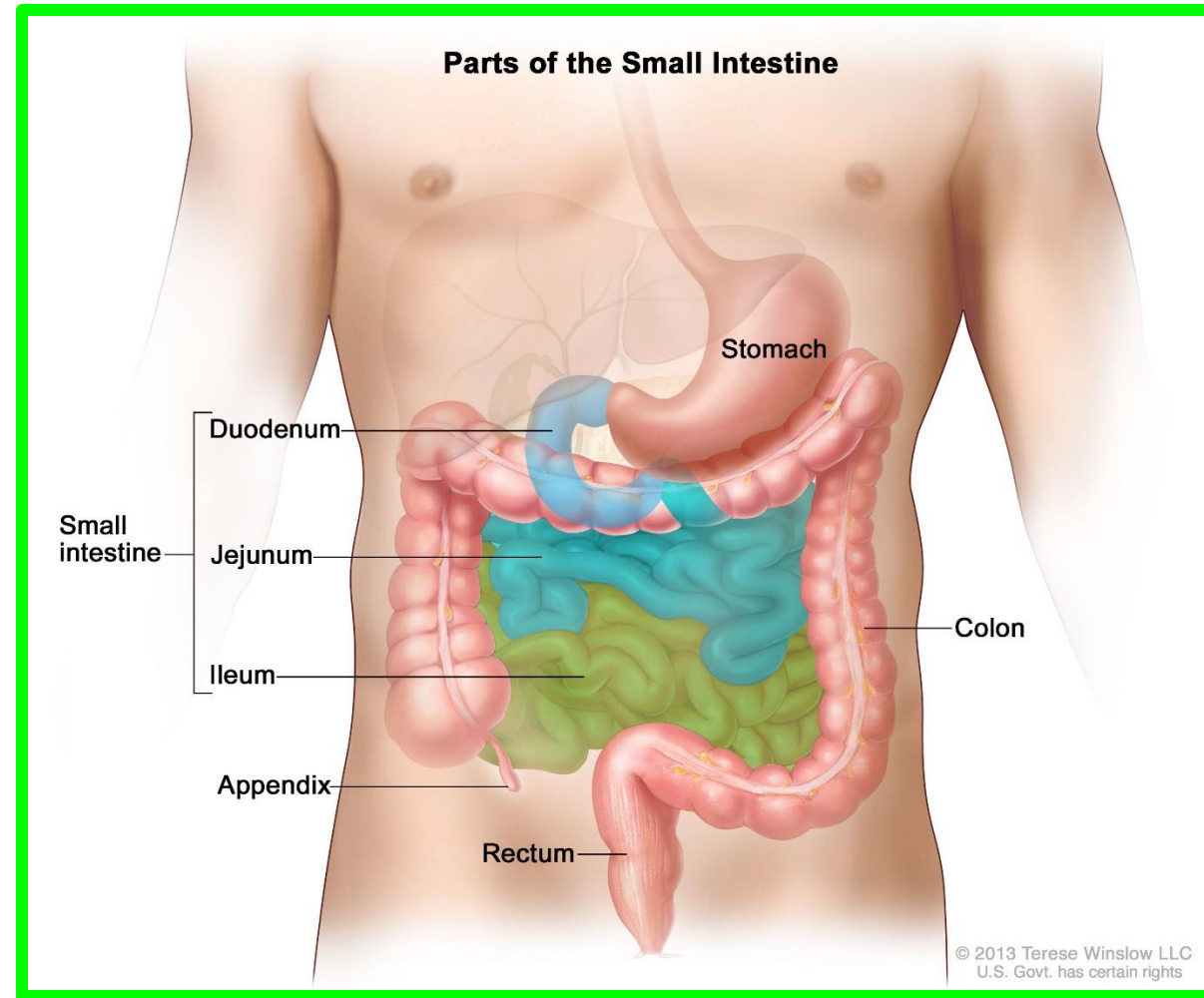
Although **bleeding from duodenal ulcers** commonly occurs, erosion of **the gastroduodenal artery** (a posterior relation of the superior part of the duodenum) by a duodenal ulcer results in severe hemorrhage into the peritoneal cavity and subsequent peritonitis

# Jejunum and Ileum

❖ The **jejunum** and **ileum** measure about **20 ft (6 m)** long; the **upper two fifths** of this length make up the **jejunum**.

❖ The **jejunum** begins at the **duodenojejunal flexure**, and the **ileum** ends at **the ileocecal junction**

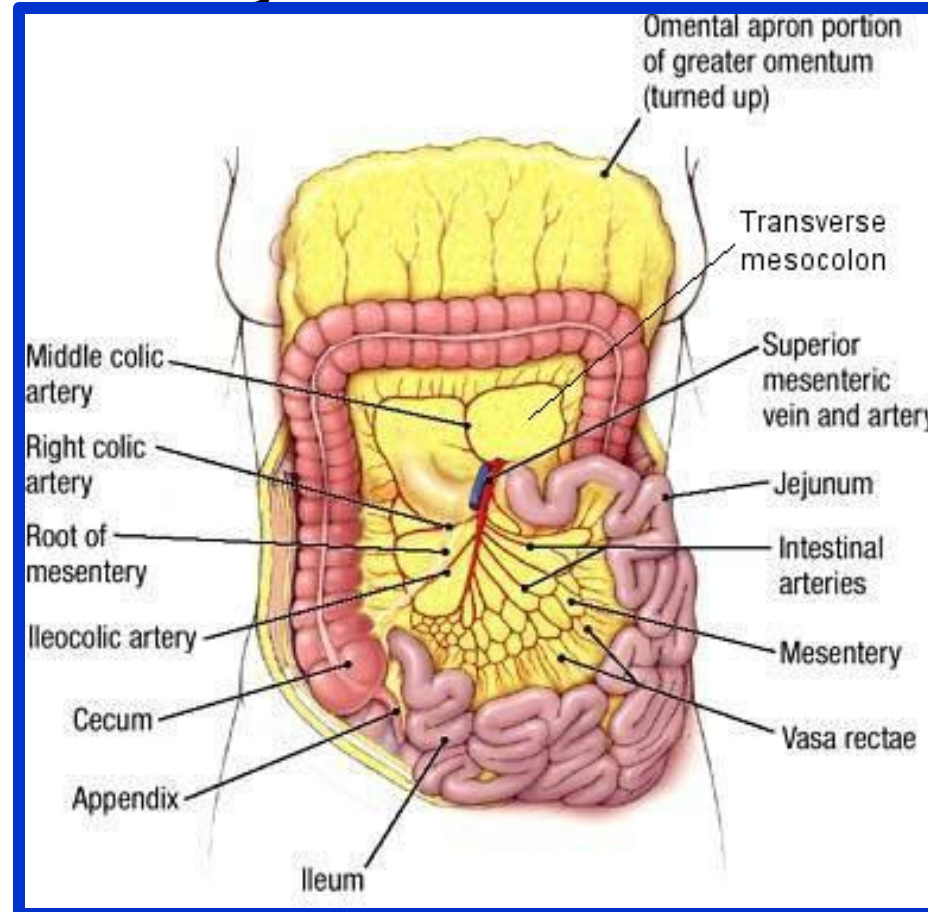
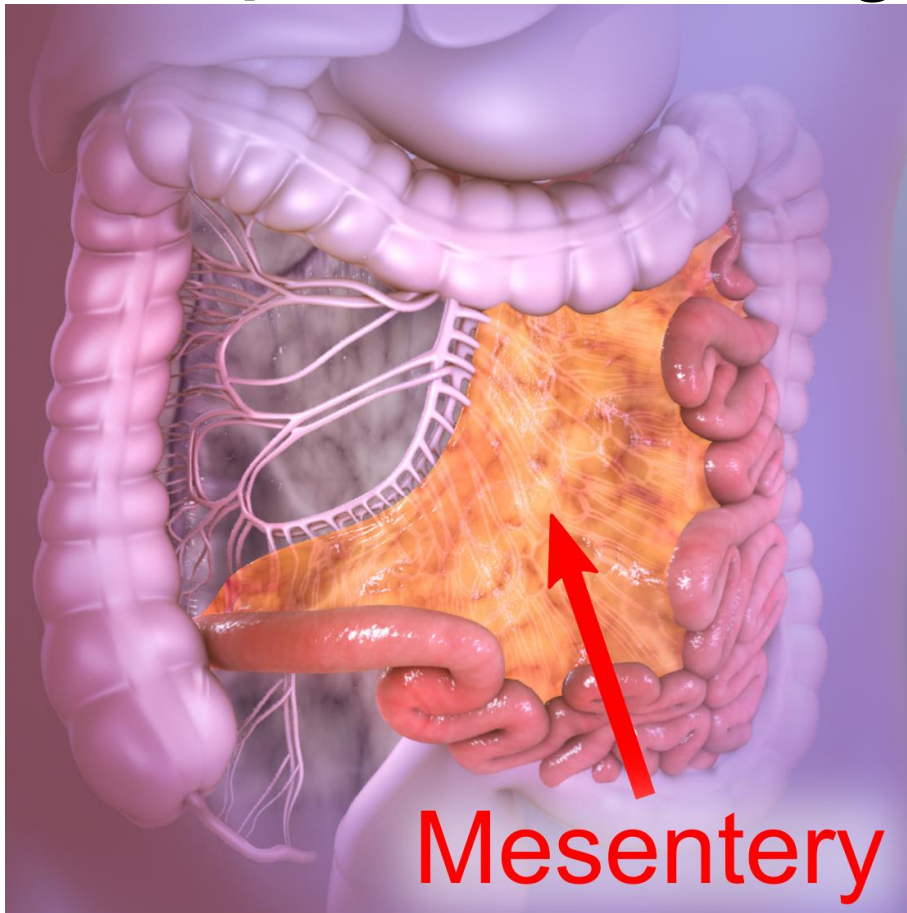
❖ The coils of **jejunum** and **ileum** are freely mobile and are attached to the **posterior abdominal wall** by a fan-shaped fold of peritoneum known as **the mesentery of the small intestine**



# Jejunum and Ileum

Dr. Aiman AL-Maathydi  
Tuesday 7 April 2026

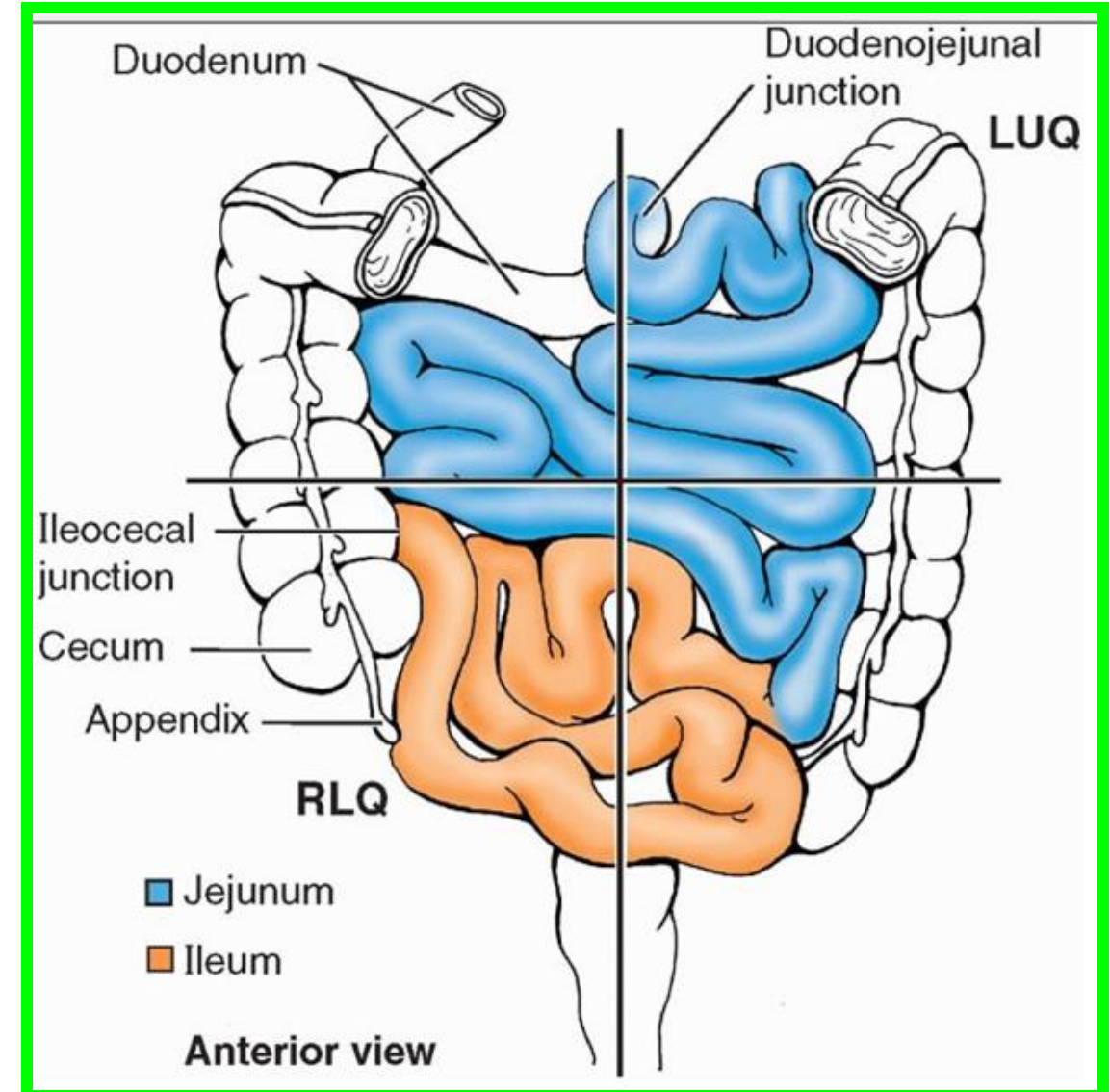
The root of the mesentery permits the entrance and exit of the branches of the **superior mesenteric artery** and **vein**, **lymph vessels**, and **nerves** into the space between the two layers of peritoneum forming the mesentery



# Jejunum and Ileum

In the living, the jejunum can be distinguished from the ileum by the following features

❖ **The jejunum** lies coiled in the upper part of the peritoneal cavity below the left side of the transverse mesocolon; **the ileum** is in the lower part of the cavity and in the pelvis



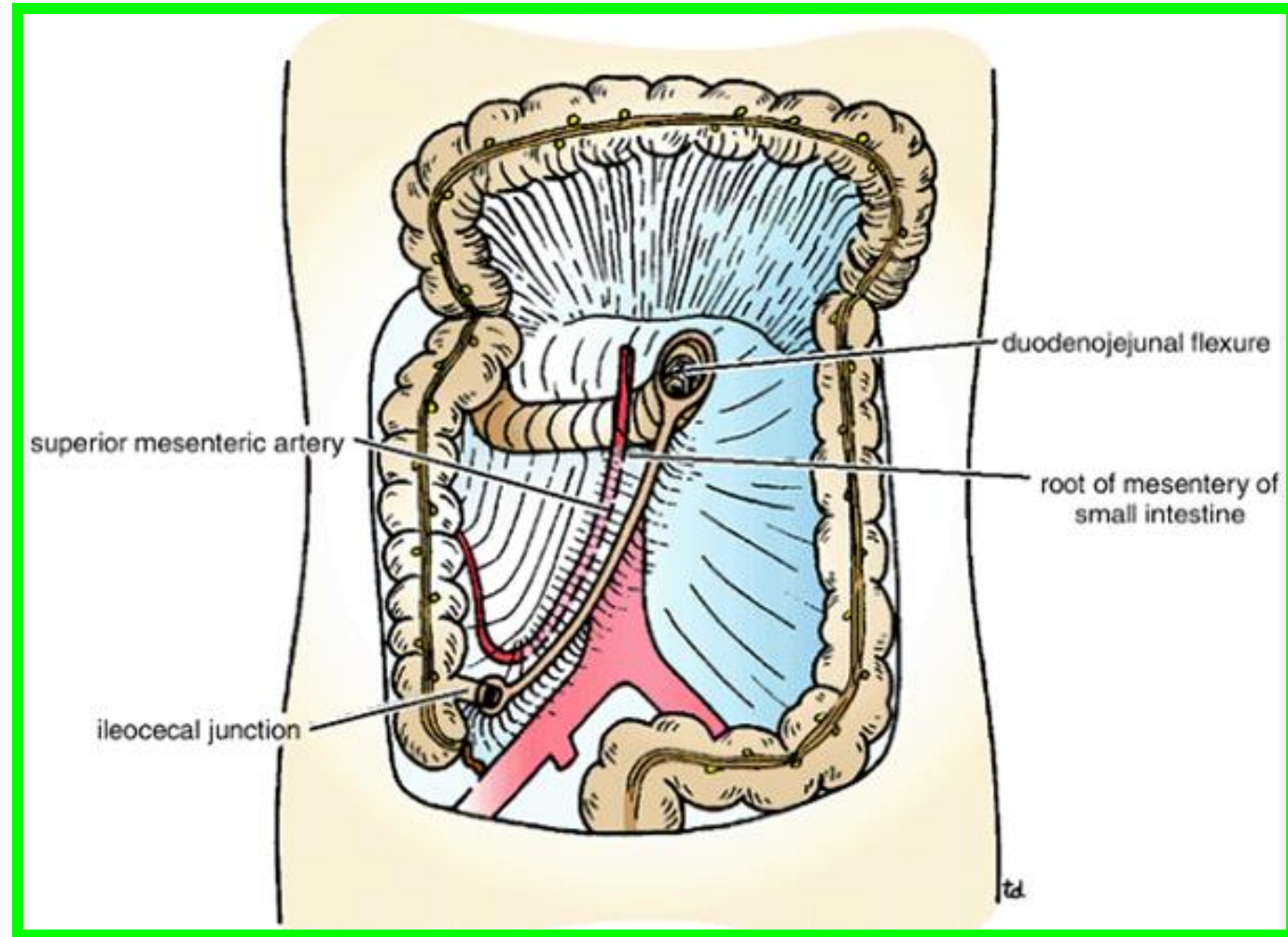
Dr. Aiman AL-Maathydi

Tuesday 7 April 2026

# Jejunum and Ileum

❖ The jejunal mesentery is attached to the posterior abdominal wall above and to the left of the aorta, whereas

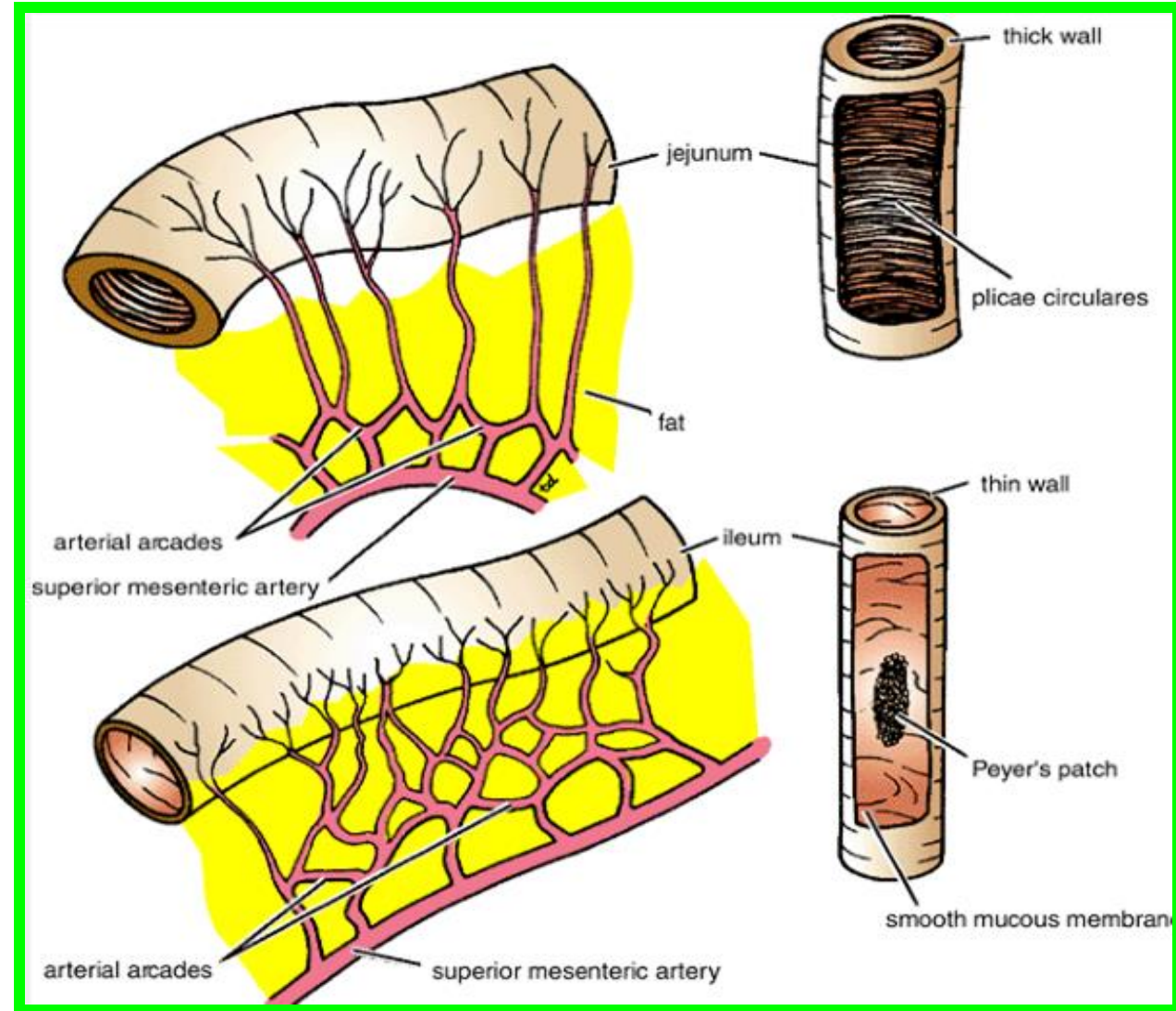
❖ The ileal mesentery is attached below and to the right of the aorta



# Jejunum and Ileum

❖ The jejunal mesenteric vessels form only one or two arcades, with long and infrequent branches passing to the intestinal wall.

❖ The ileum mesenteric vessels form three or four or even more arcades with numerous short terminal vessels passing to the intestinal wall

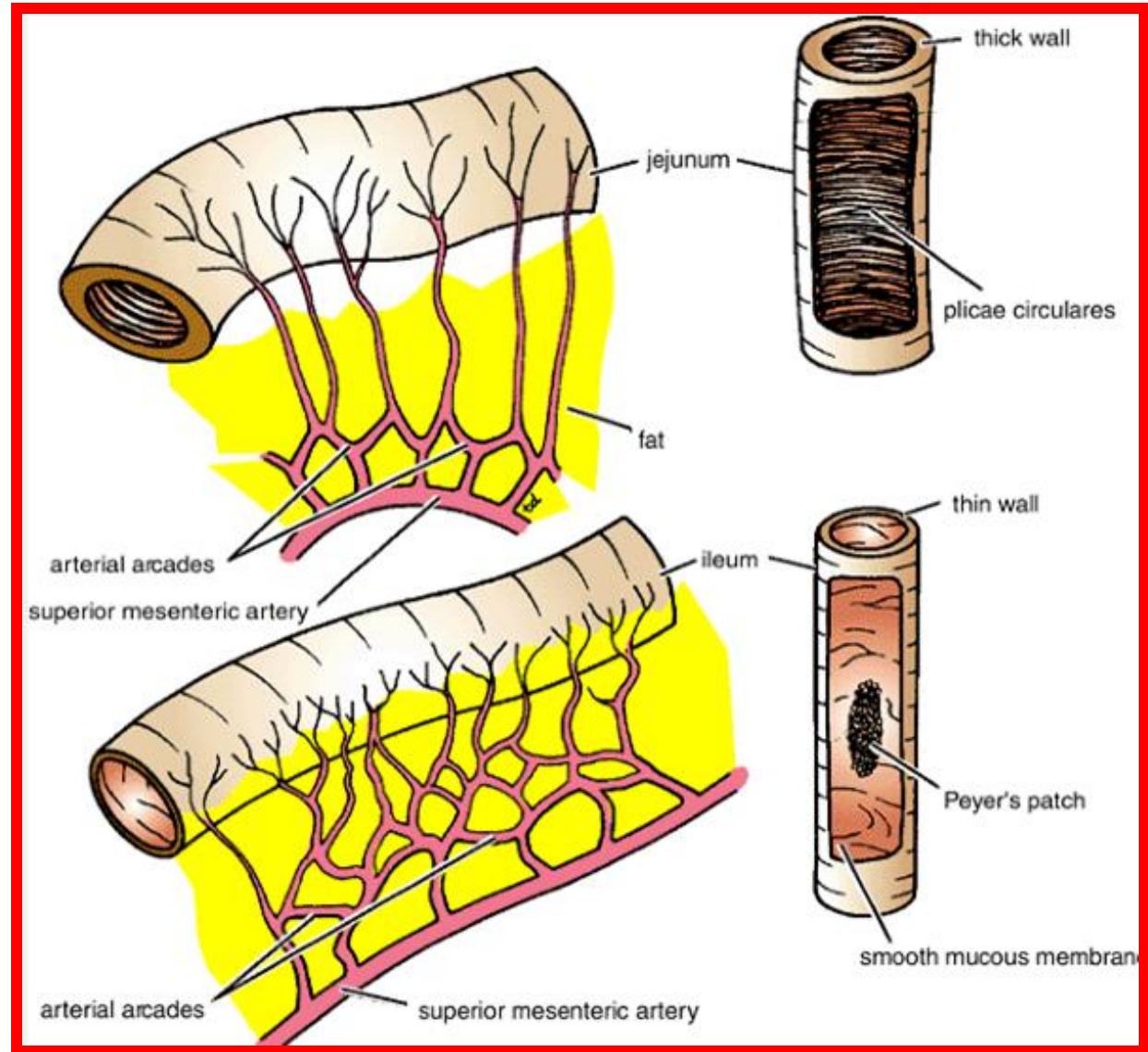


# Jejunum and Ileum

❖ The jejunum is wider bored, thicker walled, and redder than the ileum.

The jejunal wall feels thicker because the plicae circulares, are larger, more numerous, and closely set in the jejunum,

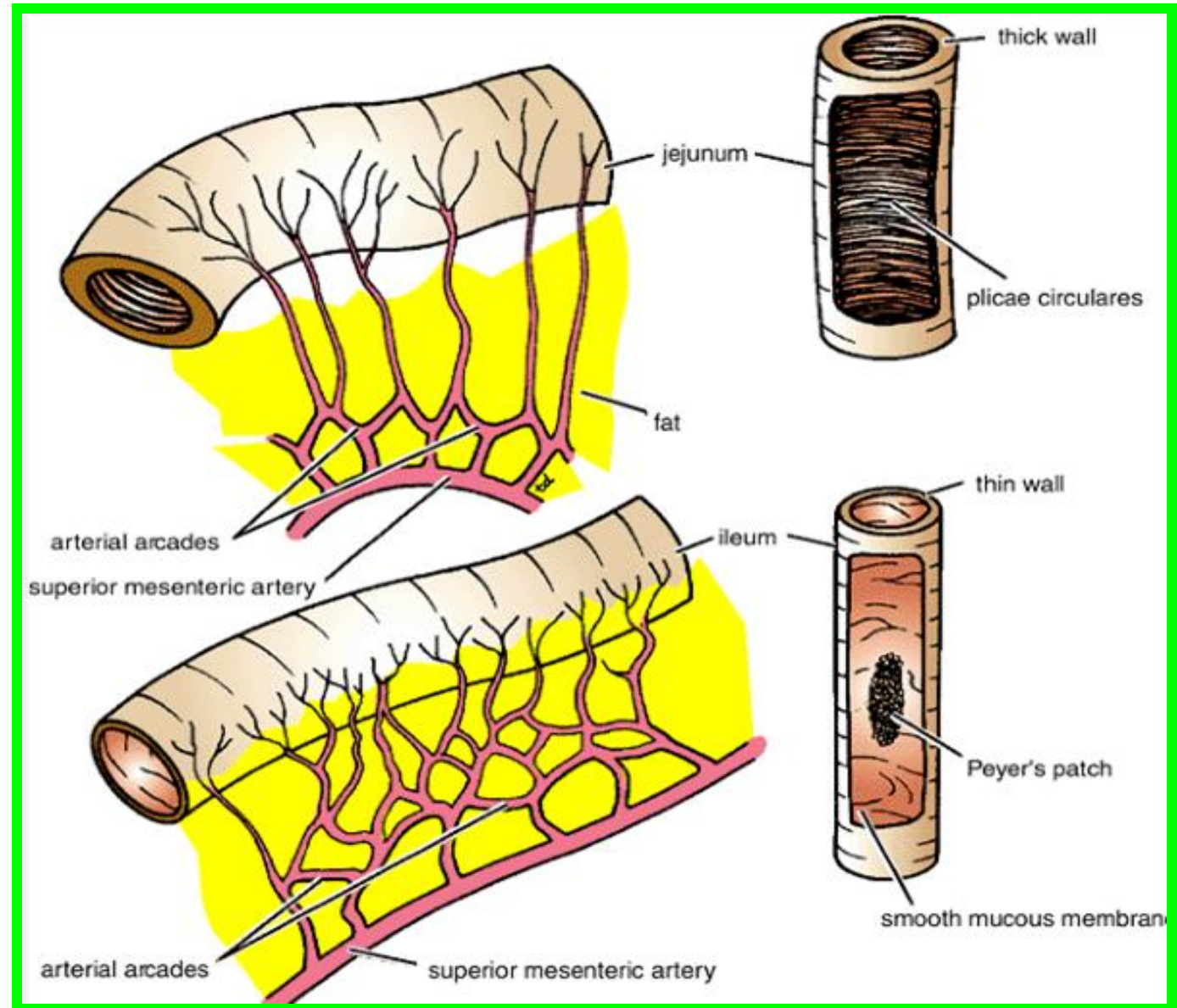
whereas in the upper part of the ileum they are smaller and more widely separated and in the lower part they are absent



# Jejunum and Ileum

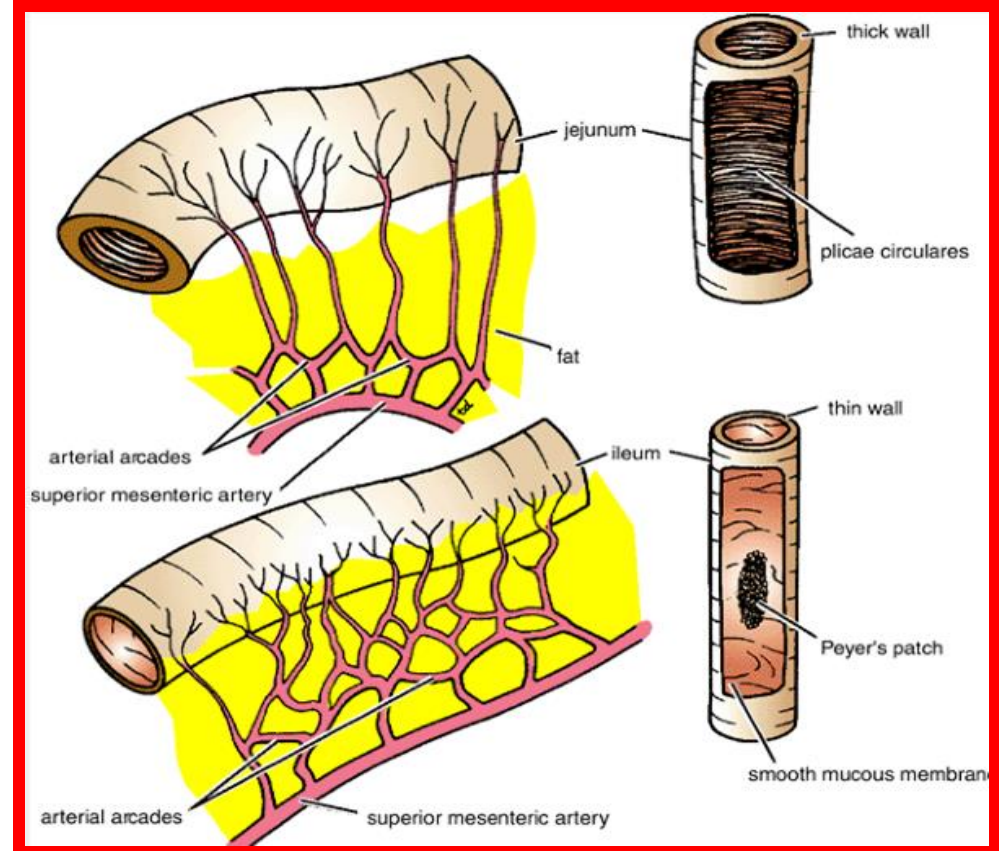
❖ At the jejunal end of the mesentery, the fat is deposited near the root and is scanty near the intestinal wall.

❖ At the ileal end of the mesentery the fat is deposited throughout so that it extends from the root to the intestinal wall.



# Jejunum and Ileum

❖ Aggregations of lymphoid tissue (**Peyer's patches**) are present in the mucous membrane of **the lower ileum** along the antimesenteric border. In the living these may be visible through the wall of the ileum from the outside

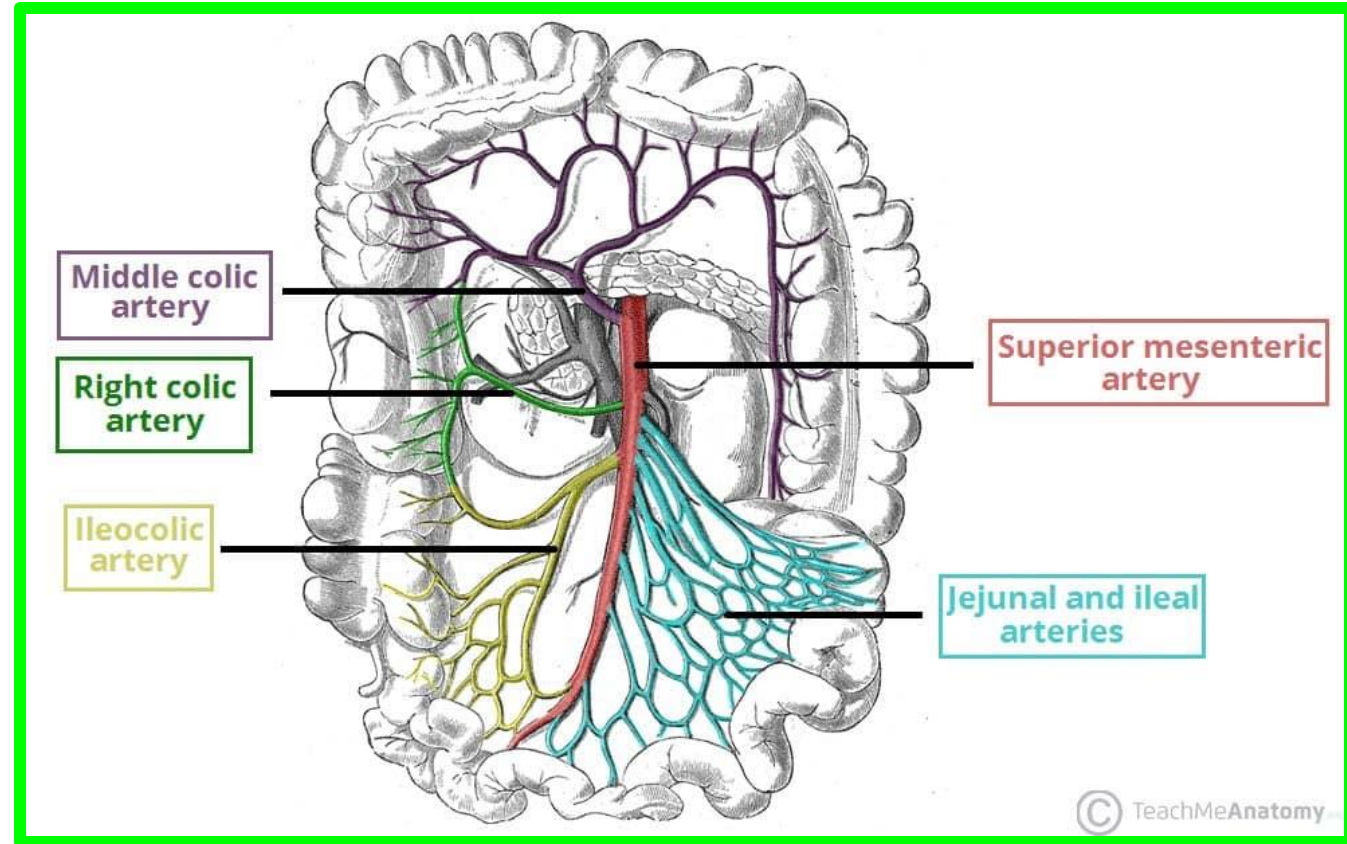


# Jejunum and Ileum

## Arteries

✓ The arterial supply is from branches of **the superior mesenteric artery**

✓ **The intestinal branches** arise from the left side of the artery and run in the mesentery to reach the gut.



✓ They anastomose with one another to form a **series of arcades**.

✓ The lowest part of the ileum is also supplied by **the ileocolic artery**

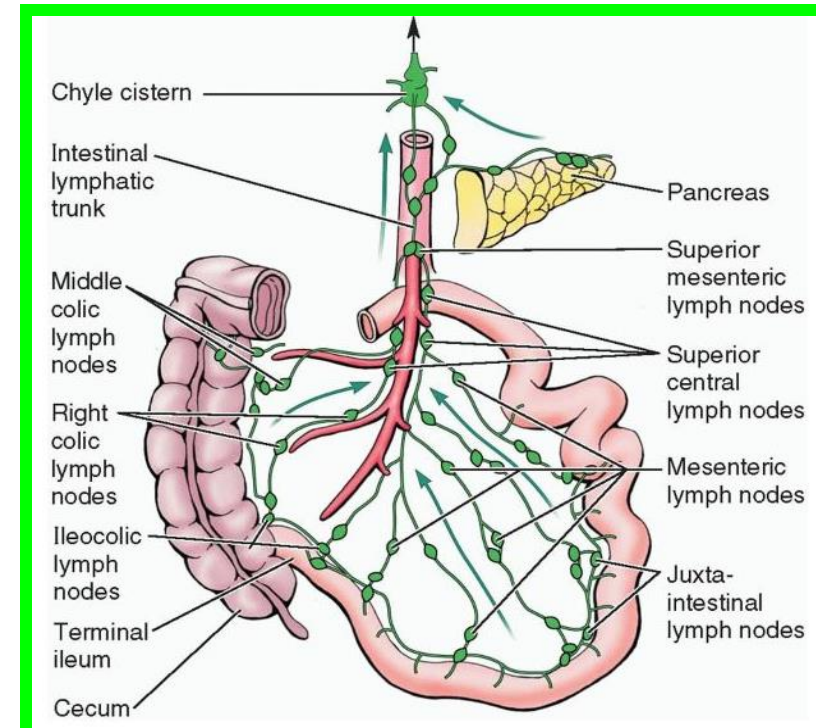
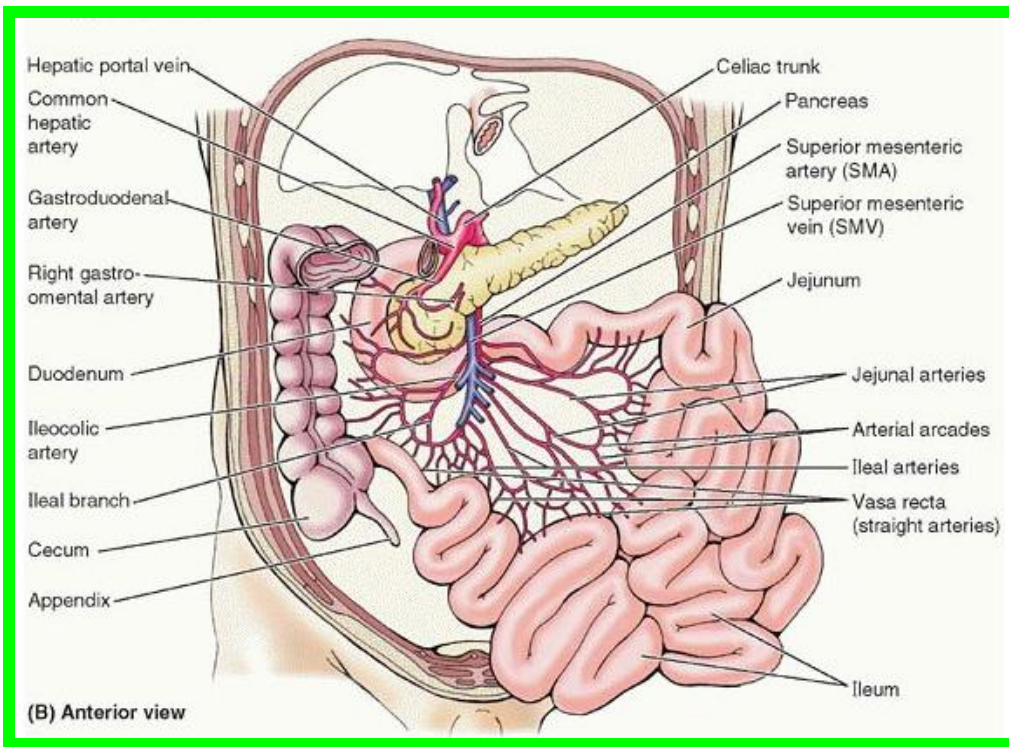
# Jejunum and Ileum

## Veins

The veins correspond to the branches of the **superior mesenteric artery** and drain into the **superior mesenteric vein**

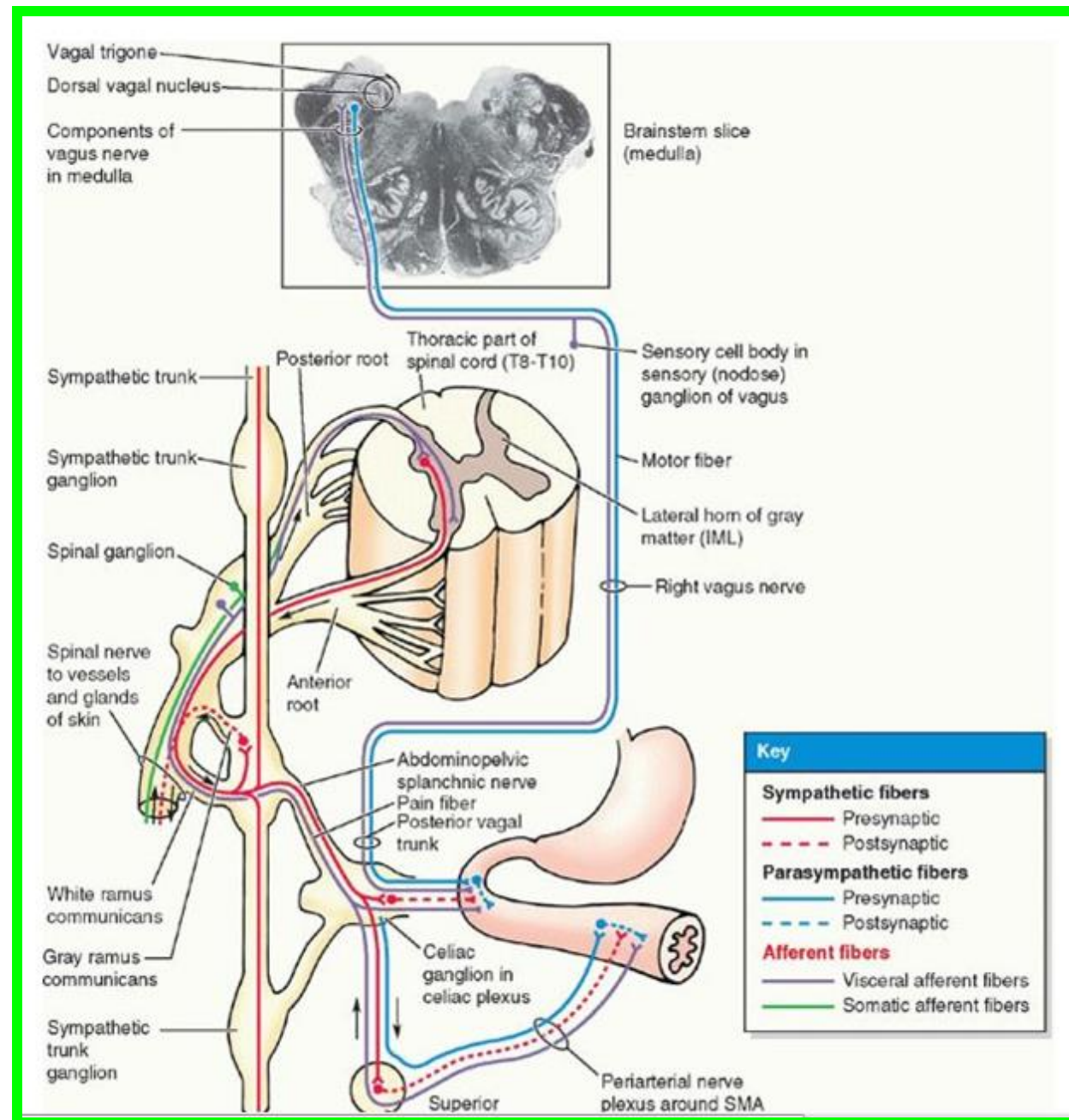
## Lymph Drainage

The lymph vessels pass through many intermediate mesenteric nodes and finally reach the superior mesenteric nodes, which are situated around the origin of the **superior mesenteric artery**



# Jejunum and Ileum

The nerves are derived from the **sympathetic and parasympathetic (vagus)** nerves from the **superior mesenteric plexus**



# Ileal Diverticulum

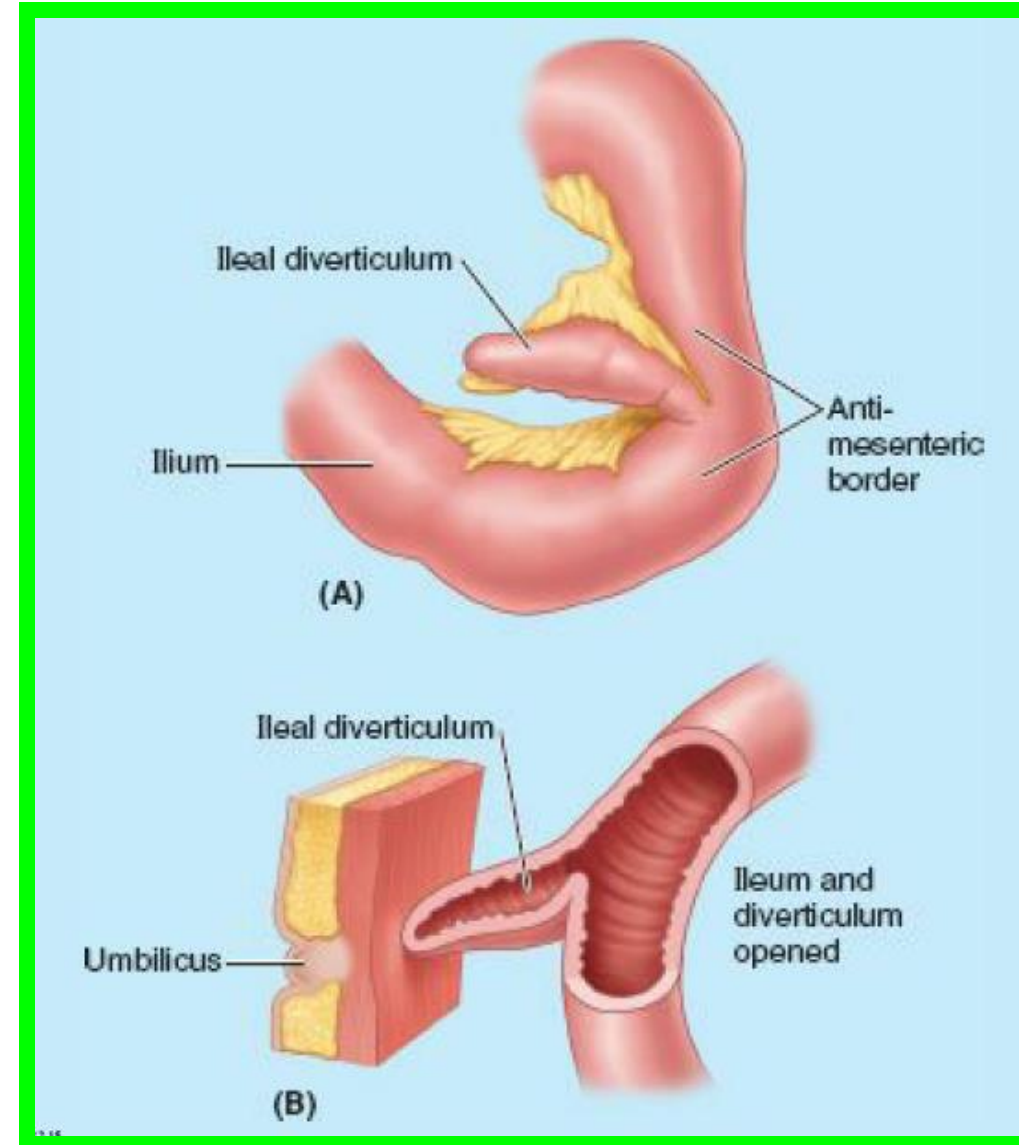
Tuesday 7 April 2026

Dr. Aiman AL-Maathydi

(or Meckel diverticulum) is a congenital anomaly that occurs in 1–2% of the population. usually appears as a finger-like pouch. It is always at the site of the antimesenteric border of the ileum.

The diverticulum is usually located 30–60 cm from the ileocecal junction in infants and 50 cm in adults.

An ileal diverticulum may become inflamed and produce pain mimicking that produced by appendicitis.

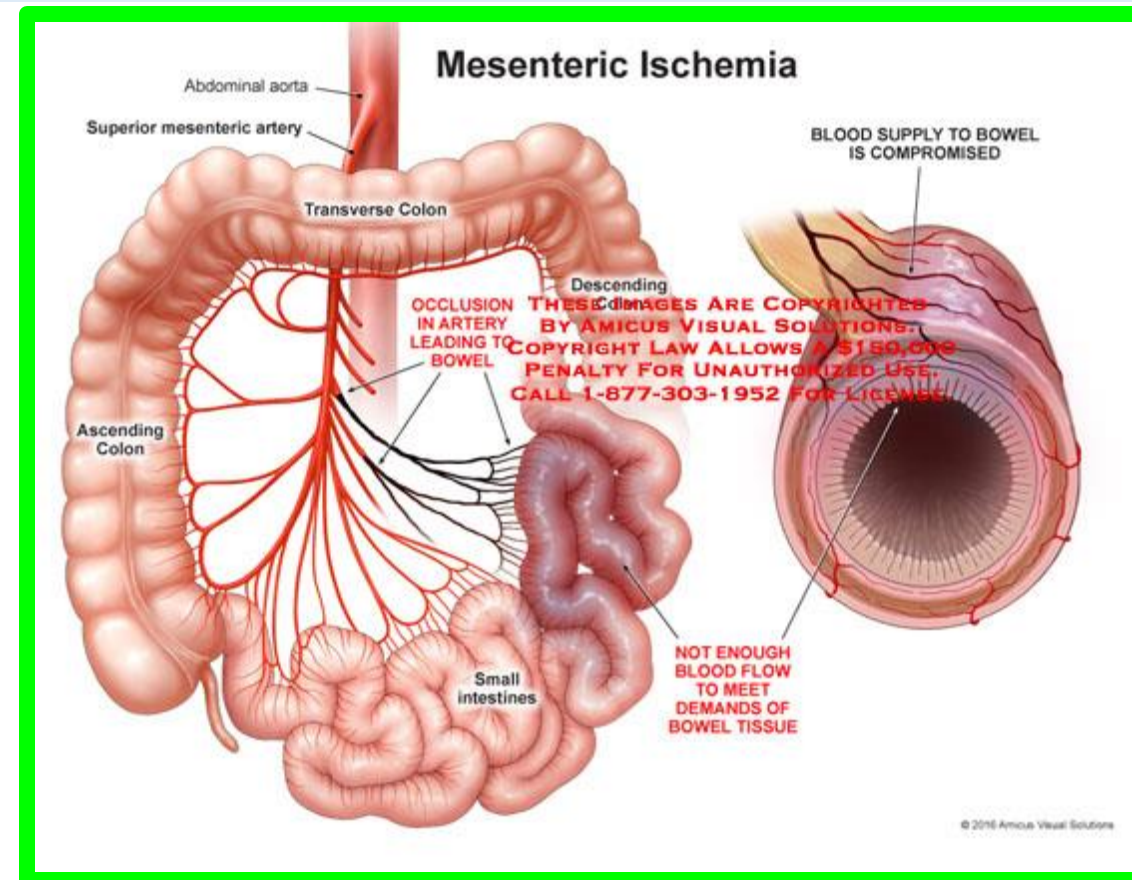


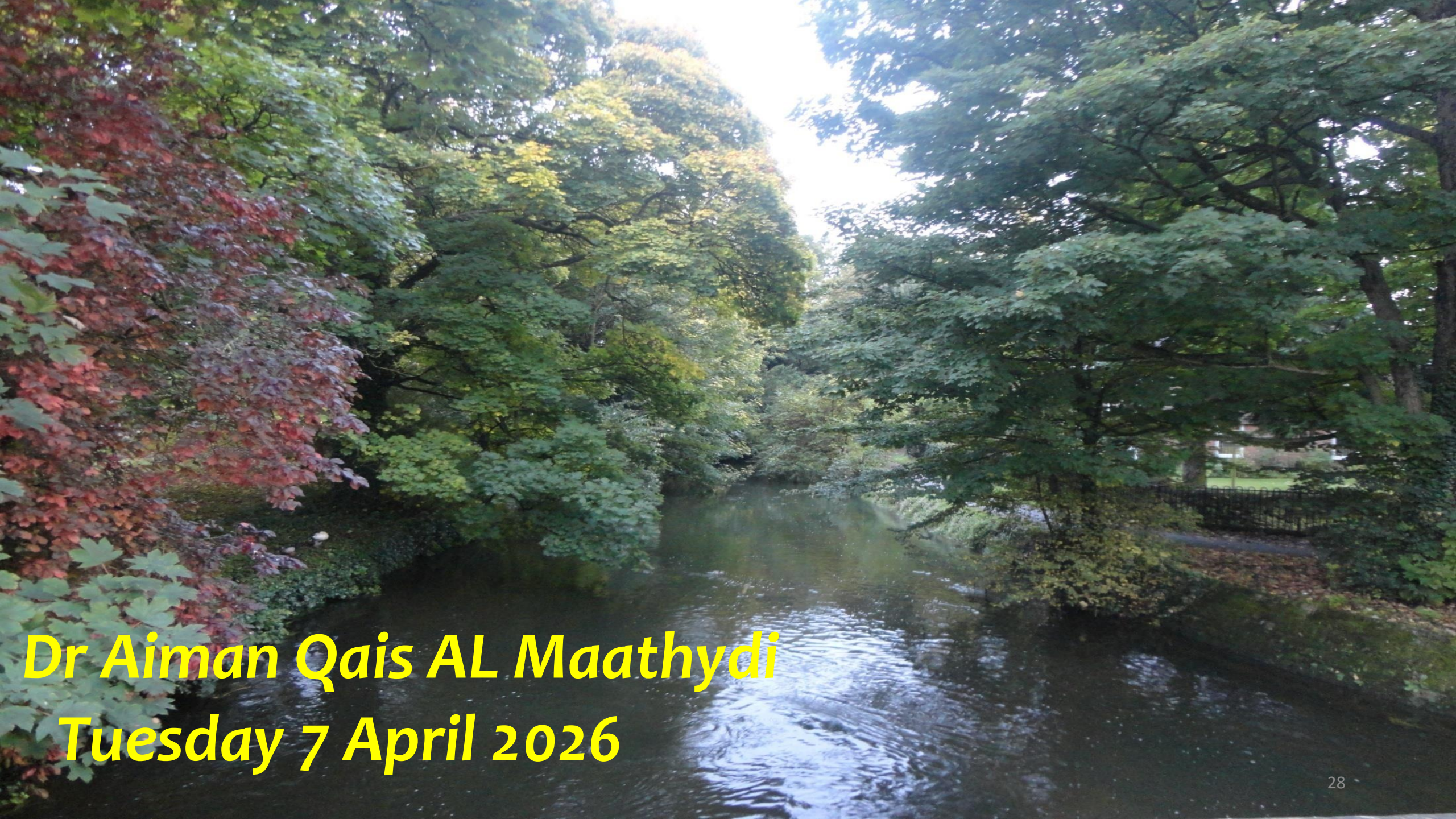# Ischemia of Intestine

Occlusion of the vasa recta by emboli (e.g., blood clots) results in **ischemia of the part of the intestine** concerned. If the ischemia is severe, **necrosis** (tissue death) of the involved segment results **and ileus** (obstruction of the intestine) of the paralytic type occurs.

Ileus is accompanied by a severe colicky pain, along with abdominal distension, vomiting, and often fever and dehydration.

If the condition is diagnosed early (e.g., using a superior mesenteric arteriogram), the obstructed part of the vessel may be **cleared surgically**.





***Dr Aiman Qais AL Maathydi***  
***Tuesday 7 April 2026***