

وسهلا



أهلا

يُمنع أخذ السلايدات بدون
إذن المحرر واي اجراء
يخالف ذلك يقع تحت طائلة
المسؤولية القانونية
جميع المعلومات للاستخدام
التعليمي فقط

الأستاذ الدكتور يوسف حسين

كلية الطب - جامعة مؤتة - الأردن

دكتورة من جامعة كولونيا المانيا

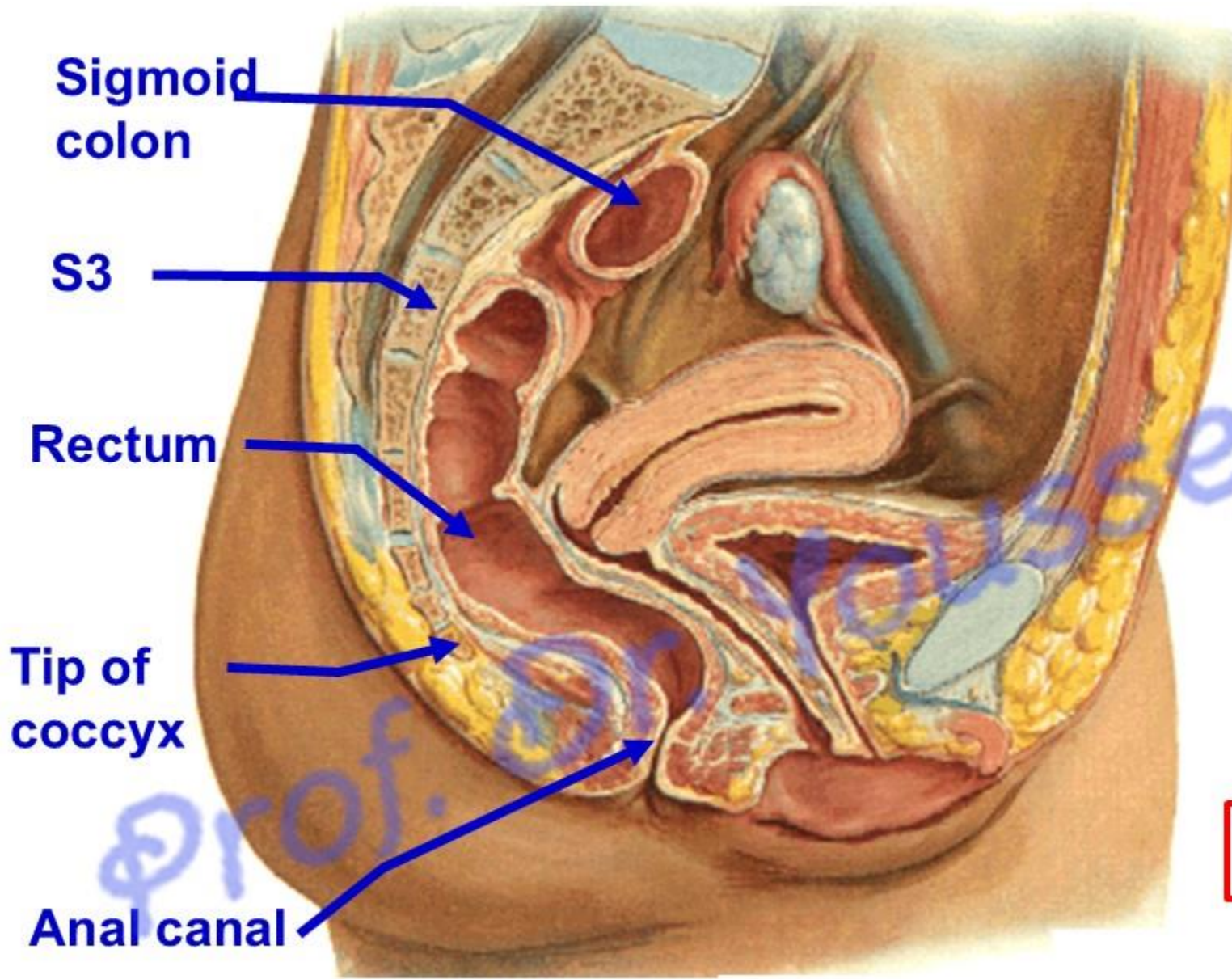
Prof. Dr. Youssef Hussein Anatomy - YouTube

الواتس 00201224904207

dr_youssefhussein@yahoo.com

Rectum

اليو تيوب د. يوسف حسين



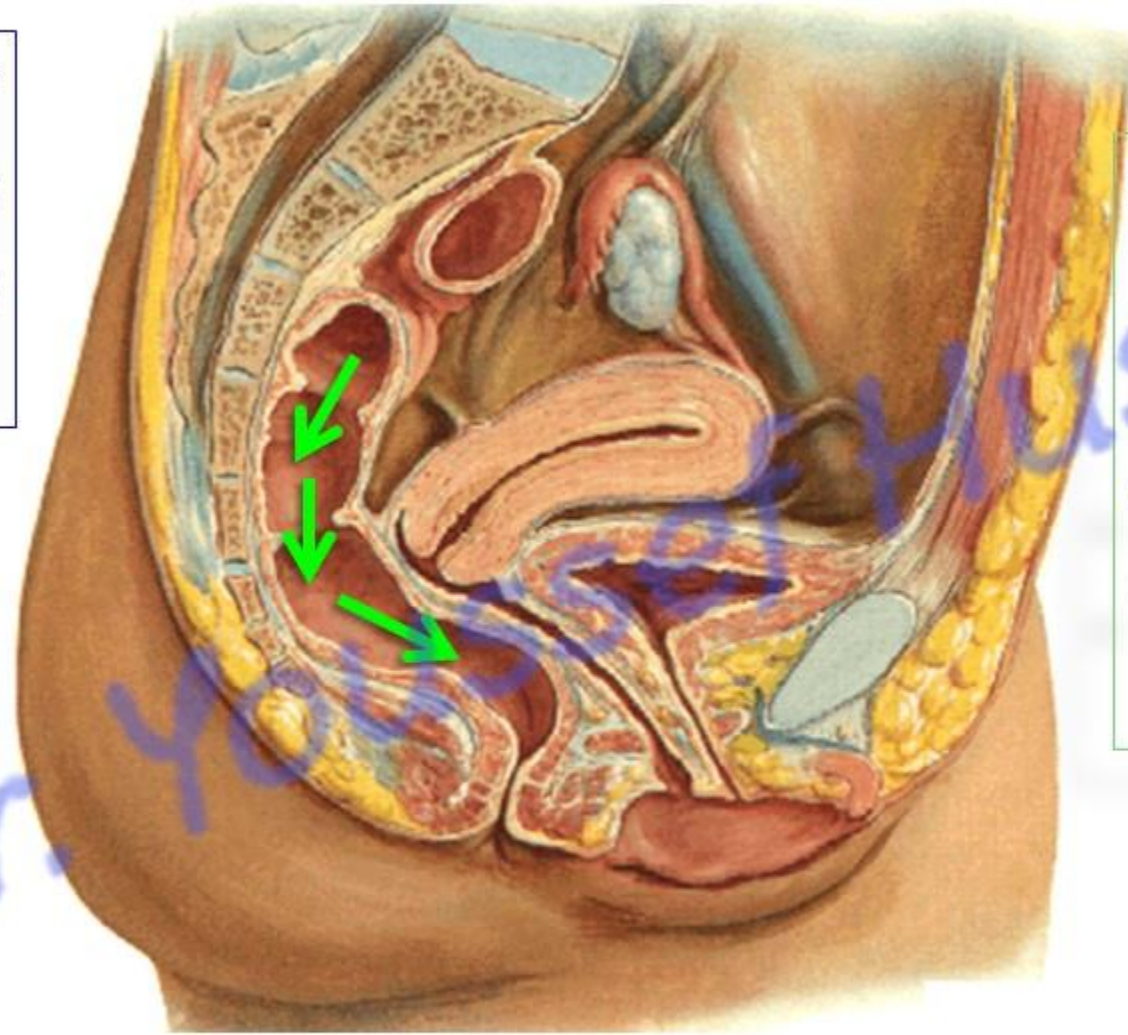
**** Beginning:** a continuation of the sigmoid colon at the 3rd sacral vertebra.

**** End:** at anorectal junction; one inch below and in front the tip of the coccyx.

**** Length,** it is about 12 cm long.

اليوطيوب د. يوسف حسين

- Follows the curvature of the sacrum and coccyx (**Sacral flexure**, **convex backward**).



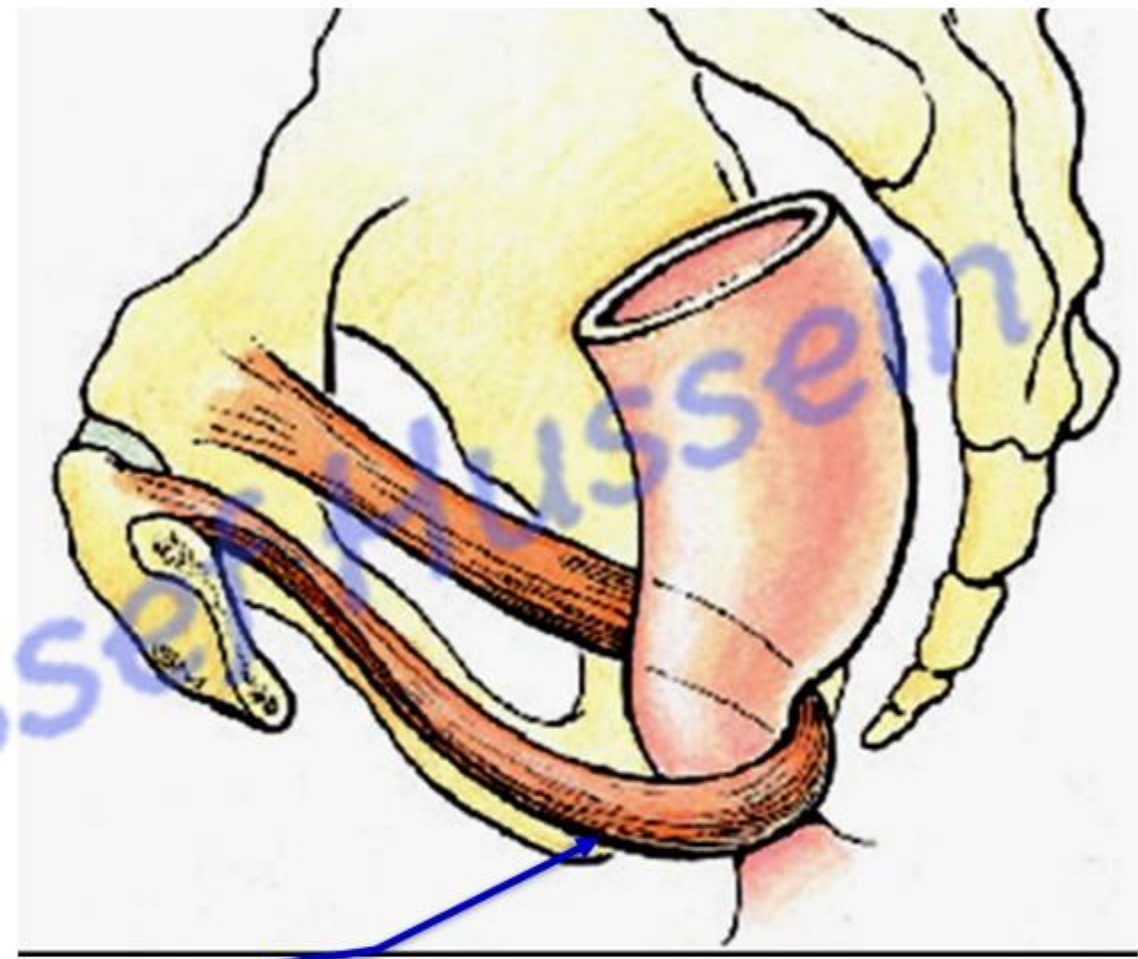
- It descends **Downwards and backwards**
- **Downwards**
- **Downwards and forwards**

اليو تيوب د. يوسف حسين

dr_youssefhusseini@yahoo.com

- **Anteroposterior flexure**

- At anorectal junction (**convex forward**): puborectalis portion of levator ani muscles forms **a sling** at the junction of rectum with anal canal and pulls this part forward.
- It is an important mechanism for **fecal continence** during the resting state by its active contraction during peristaltic contractions if defecation is not to occur



puborectalis

اليو تيوب د. يوسف حسين

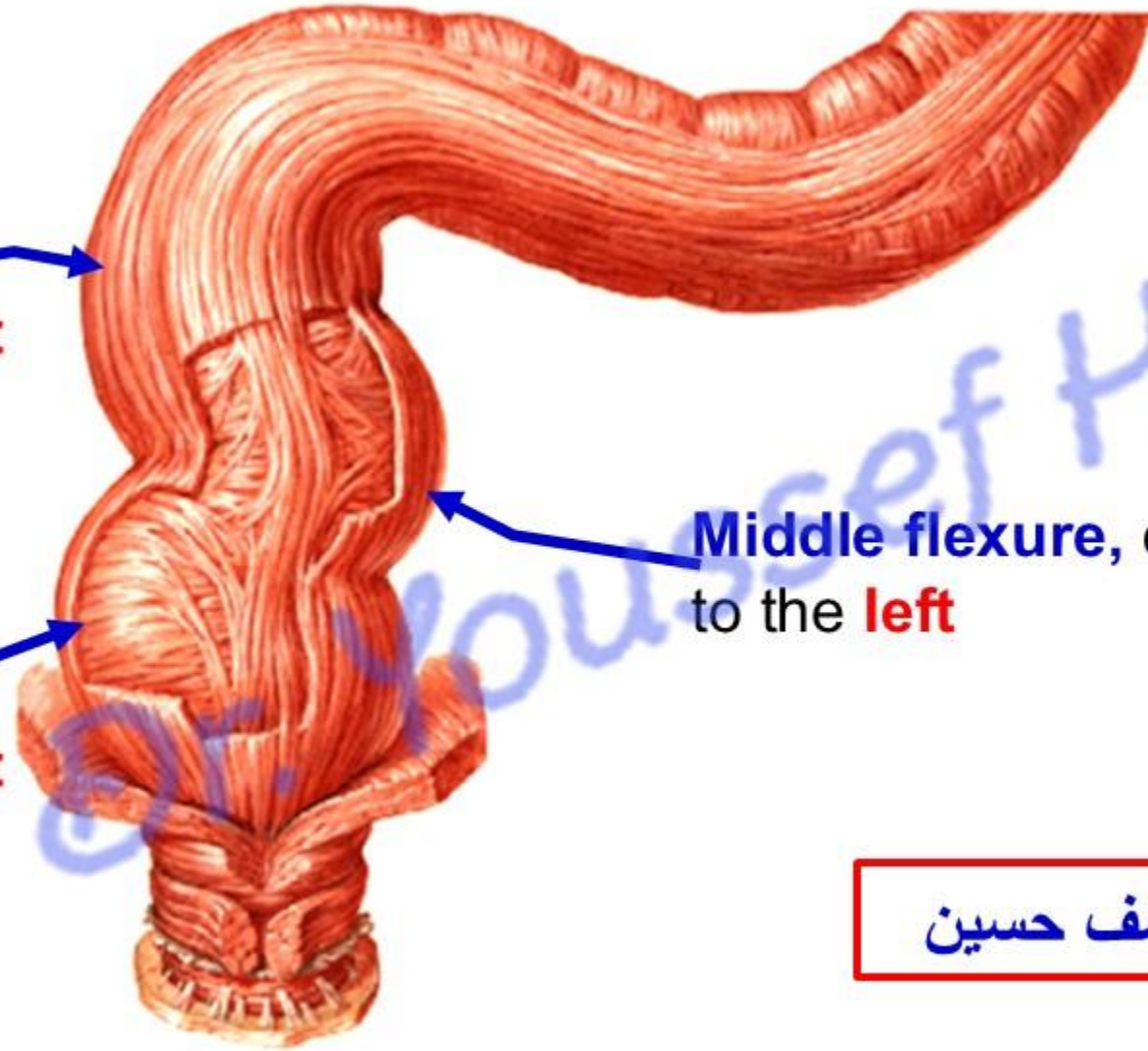
Right

- 3 Lateral rectal flexures

Upper flexure,
convex to the **right**

Lower flexure,
convex to the **right**

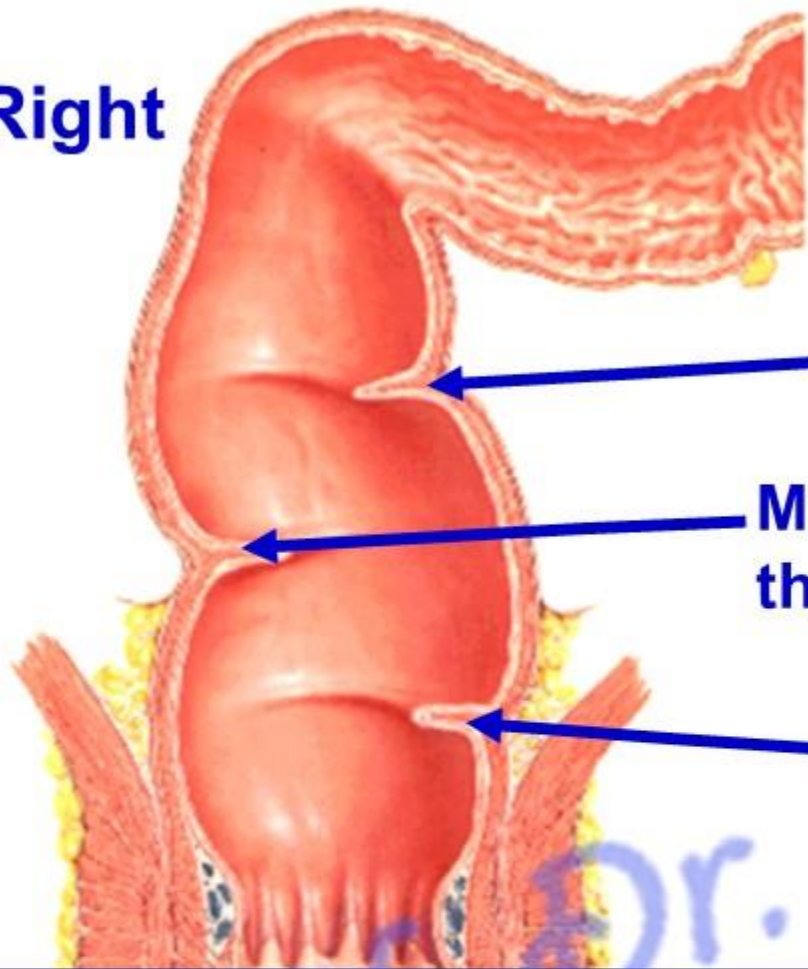
Middle flexure, convex
to the **left**



اليوثيوب د. يوسف حسين

dr_youssefhussein@yahoo.com

Right

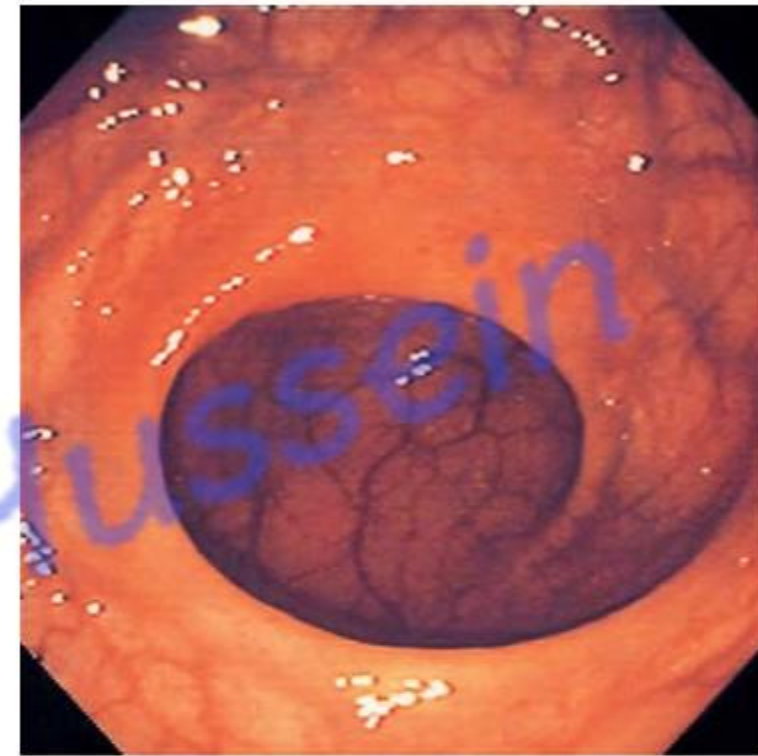


- 3 Lateral rectal folds (Houston's valves)

Superior rectal valve

Middle rectal valve, the largest

Inferior rectal valve



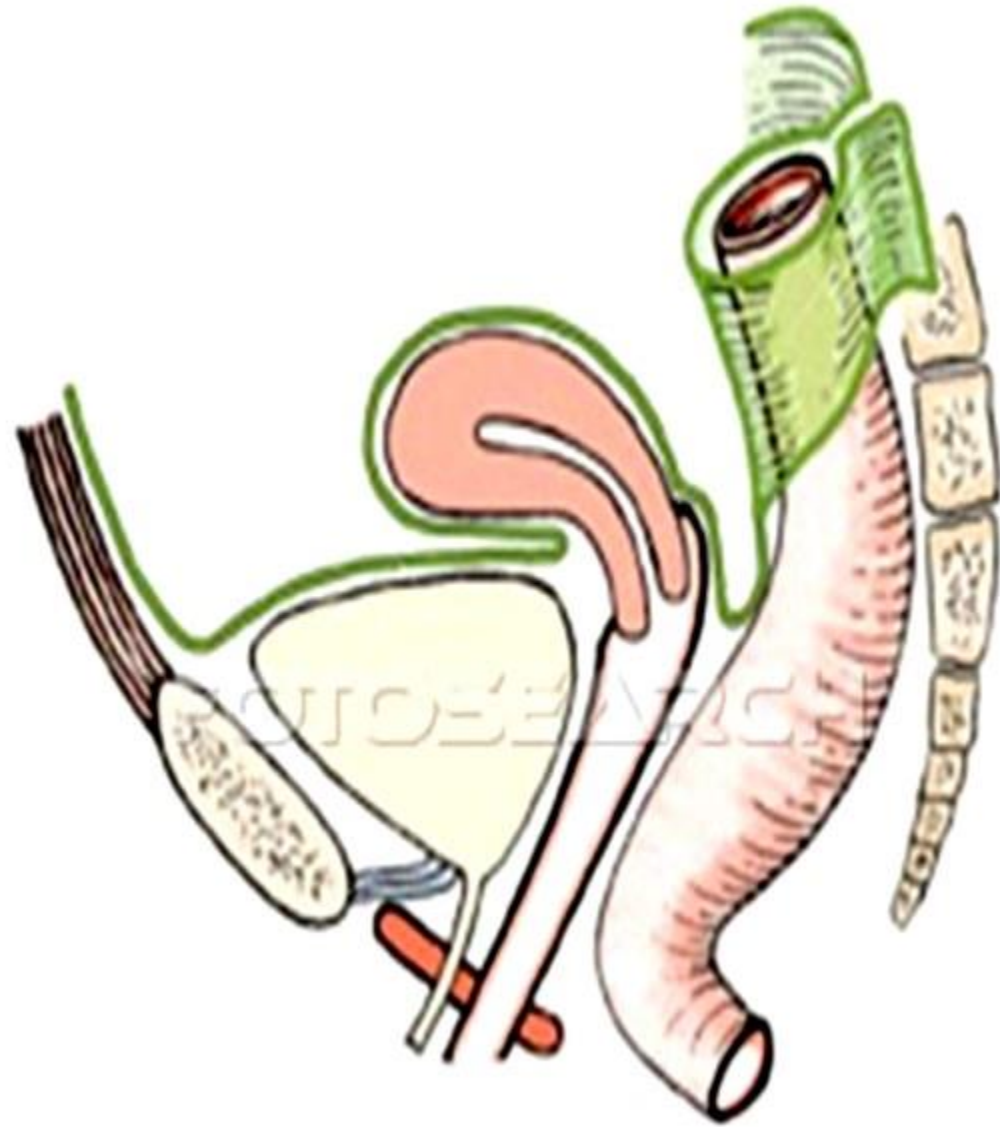
- Endoscopic appearance

- Rectal shelves- Houston's valve: 3 transverse folds lie close to inner aspect of **concave side** of 3 lateral flexures.

- Functions; support the **weight of the stool**, and prevent its urging toward the anus.

dr_youssefhussein@yahoo.com

اليوثيوب د. يوسف حسين



**** Peritoneal covering;**

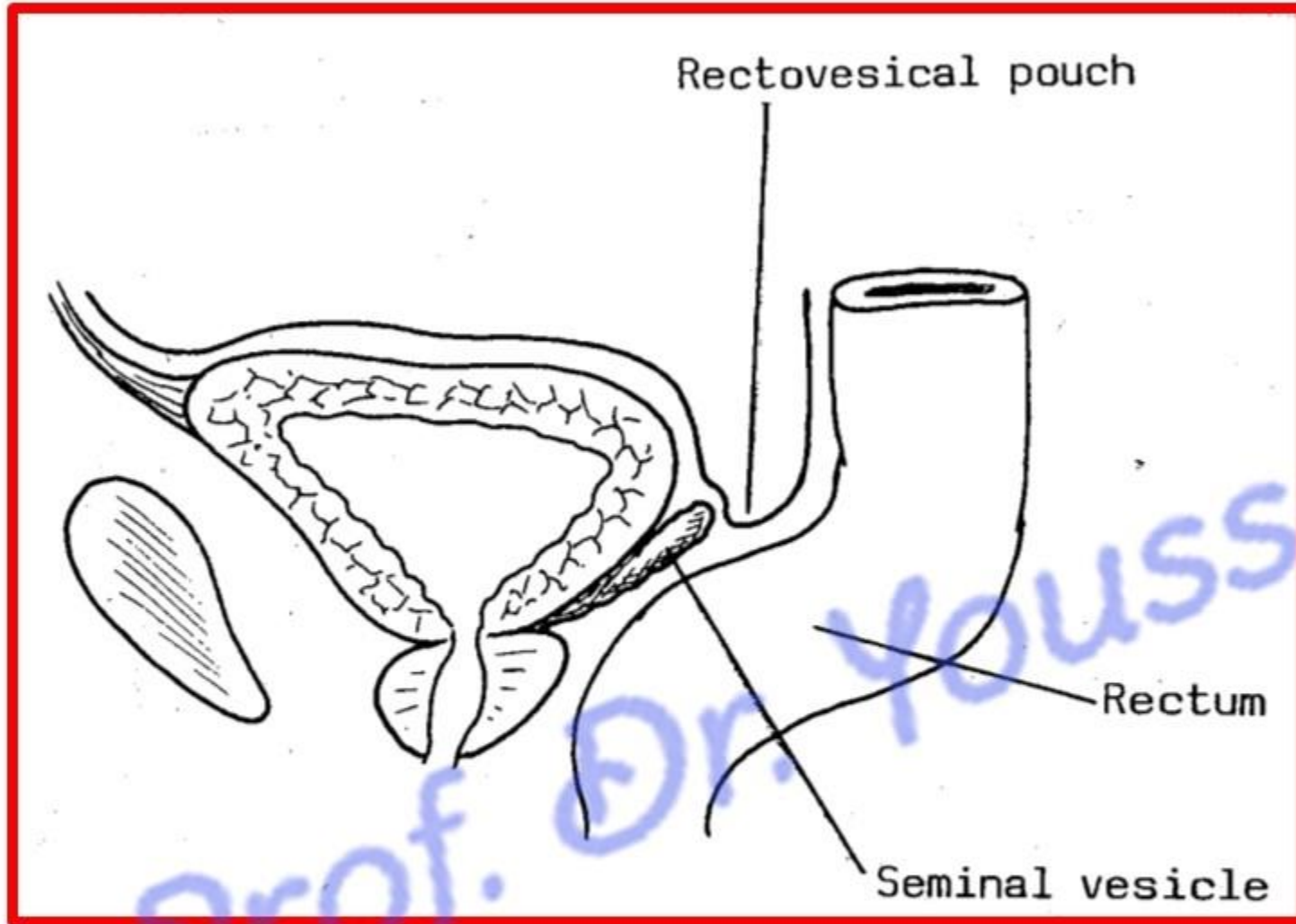
1- The upper third, is covered by peritoneum on the front and sides.

2- The middle third is only covered by peritoneum anteriorly.

3- The lower third has no peritoneal covering.

a- In female; - Reflection of peritoneum occurs from the front of the rectum at the Junction of its middle 1/3 and lower 1/3 on to the upper part of **the posterior wall of the vagina** to form the **rectovaginal, or**

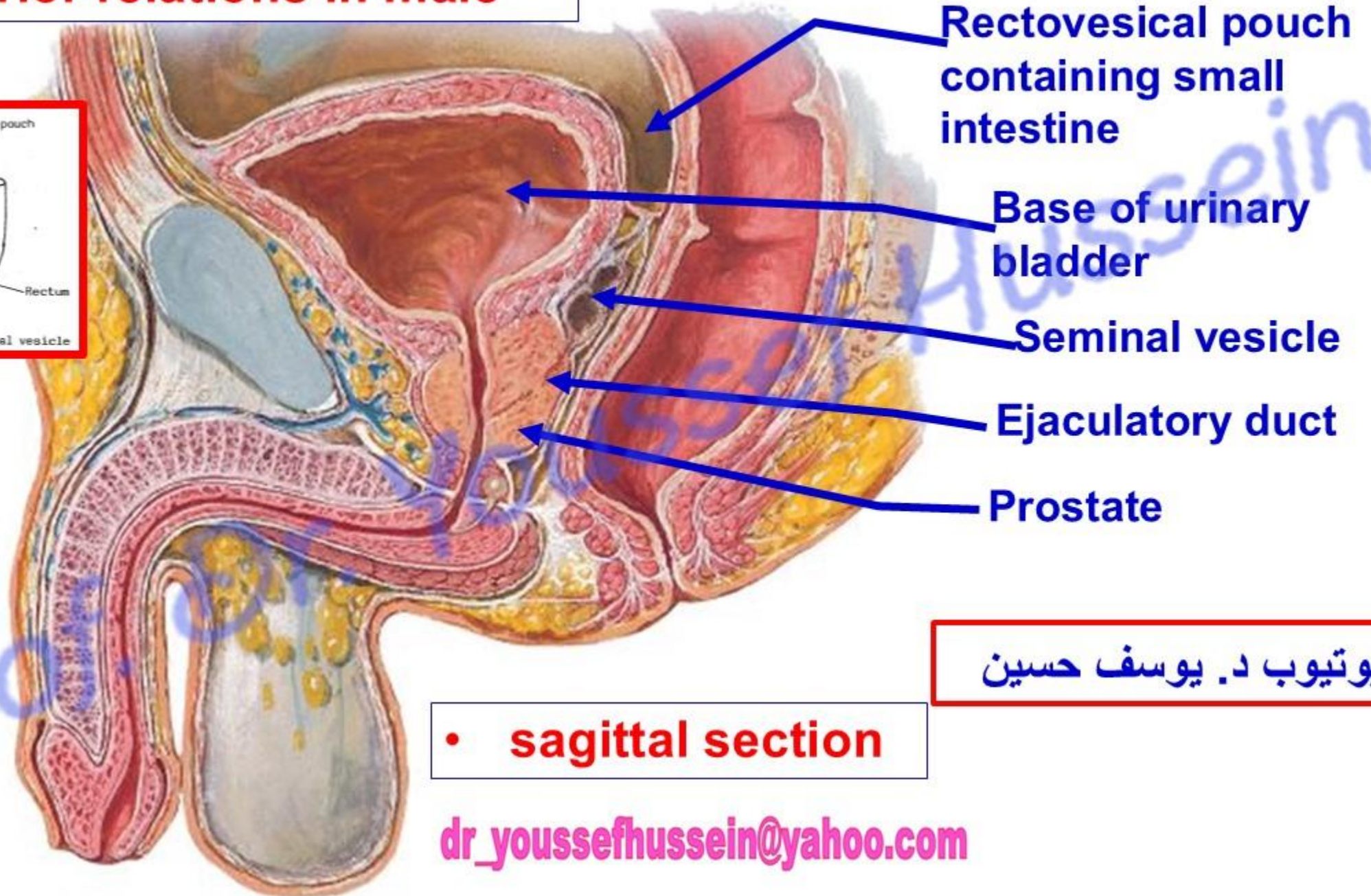
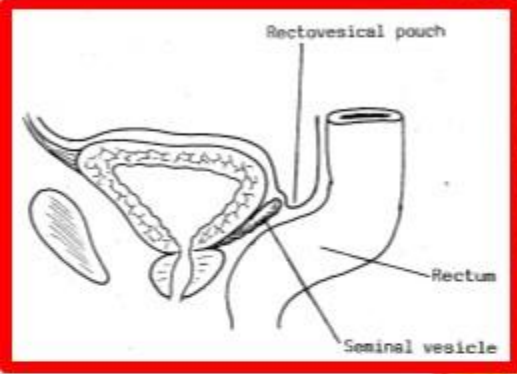
Douglas pouch (5.5 cm from anal orifice).



b- In male; Reflection of peritoneum occurs from the front of the rectum at the junction of its middle 1/3 and lower 1/3 to the upper part of the **posterior surface (base) of urinary bladder**, called the **rectovesical pouch of Denonviller (7.5 cm from anal orifice)**

اليوتوب د. يوسف حسين

- **Anterior relations in male**

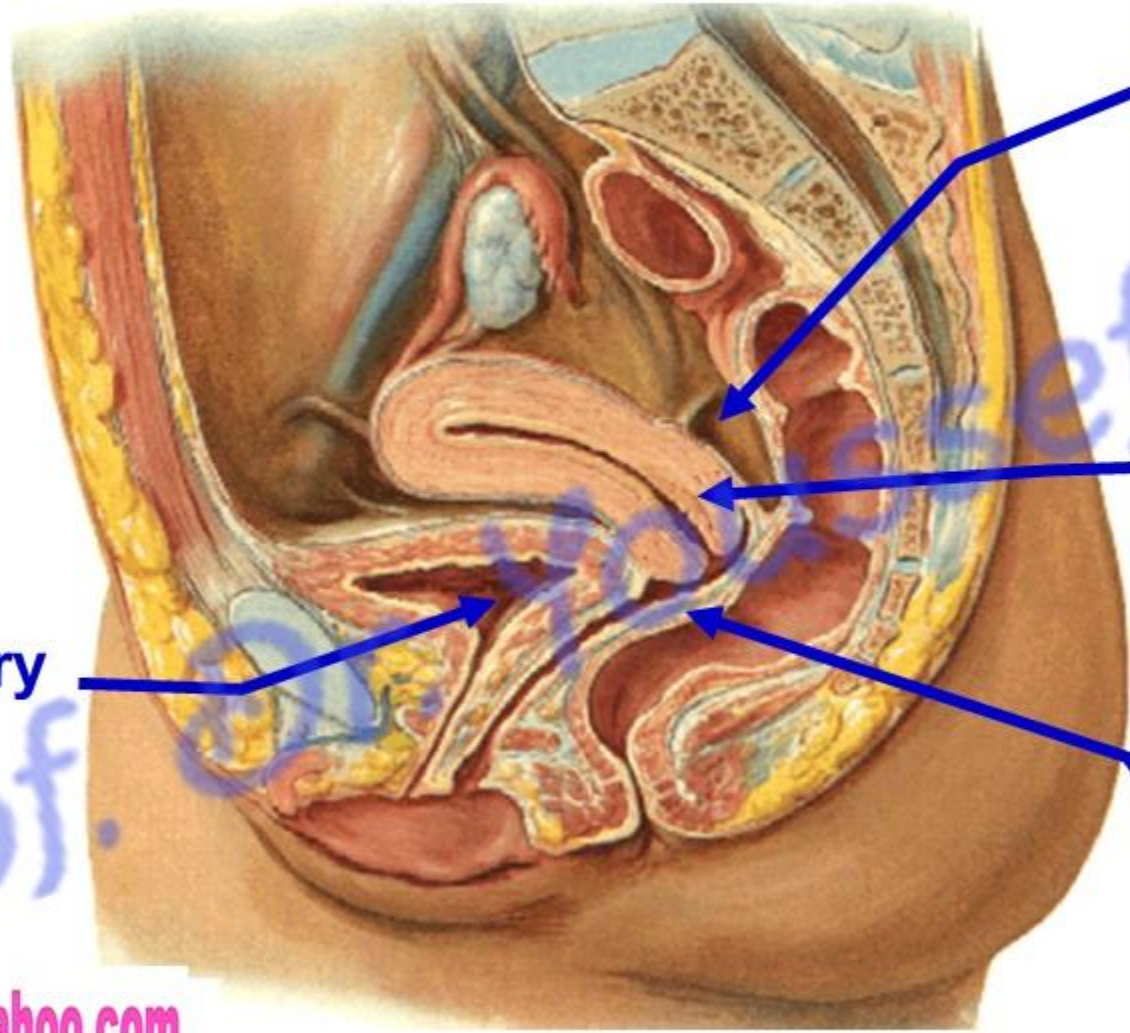


اليوتيوب د. يوسف حسين

- **sagittal section**

dr_youssefhussein@yahoo.com

- Anterior relations in female



Rectovaginal pouch
containing small
intestine

Cervix of uterus

Base of urinary
bladder

Posterior wall of Vagina

اليوثيوب د. يوسف حسين

Posterior relations both sexes

اليوتيوب د. يوسف حسين

Piriform

Median sacral Vs

Sympathetic trunk

Ventral rami of Sacral nerve

Ventral rami of coccygeal nerve

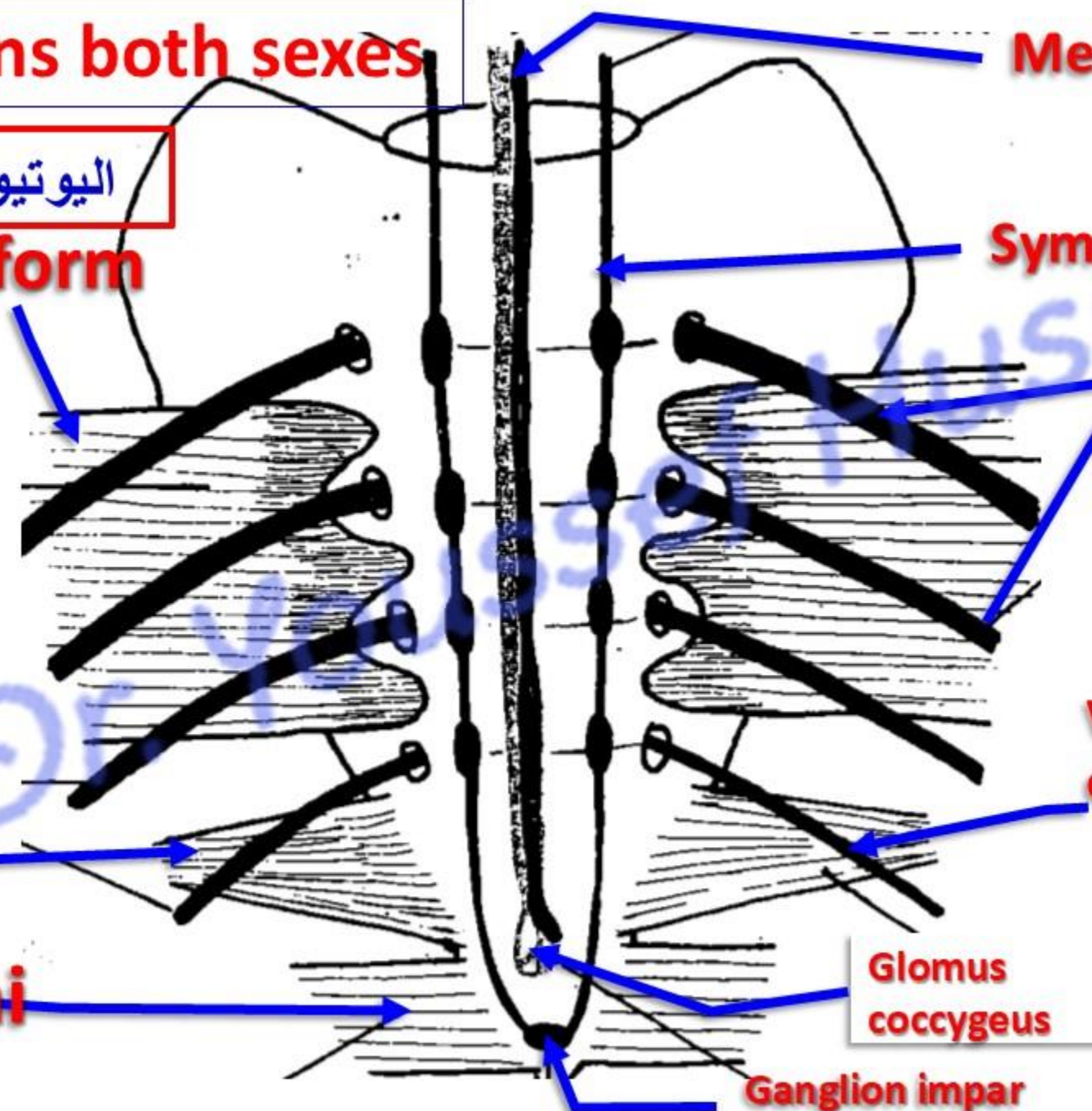
Glomus coccygeus

Ganglion impar

Coccygeus

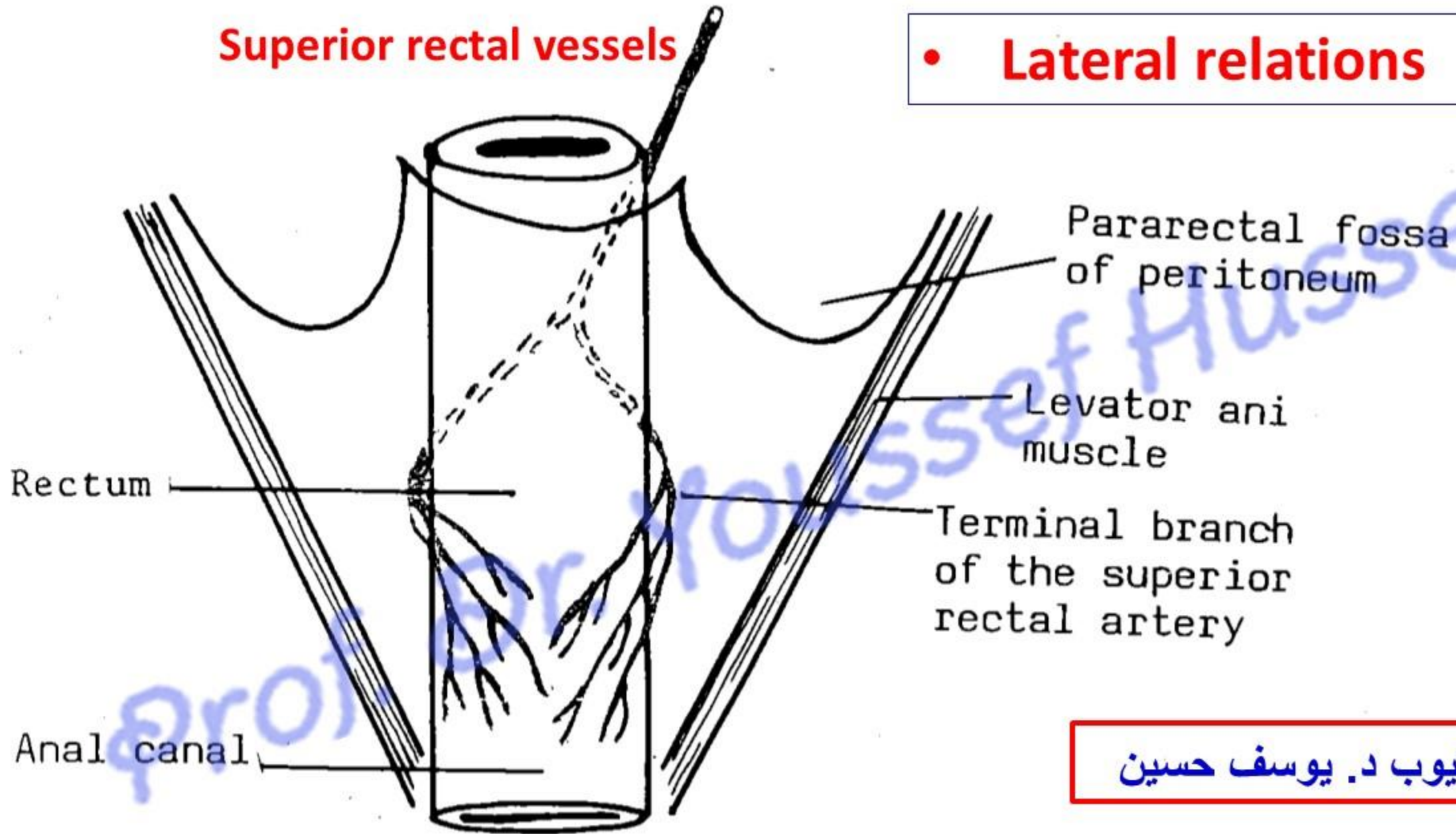
Levator ani

dr_youssefhussein@yahoo.com



Superior rectal vessels

- **Lateral relations**



اليوتيوب د. يوسف حسين

- **Factors support the rectum**
(Store of the stool)

1. **Pelvic diaphragm** (levator ani and coccygeus).
 2. **Perineal body.**
 3. **Lateral ligament of the rectum:** condensation of pelvic fascia.
 4. **Rectovesical fascia of Denonviller in male (anterior):** from the rectum to the back of the urinary bladder.
 5. **Rectovaginal fascia of Douglas in female (anterior):** from the rectum to the back of the vagina.
 6. **Fascia of Waldeyer (posterior):** condensation of pelvic fascia, connects rectum to the sacrum
- *** **Rectal prolapse:** the rectum protrudes from the anal canal

- **Ulcerative colitis**

- is chronic ulceration of the colon and rectum with cramping abdominal pain, rectal bleeding, diarrhea, and loose discharge of pus and mucus with scanty fecal particles.
- Complications include hemorrhoids, abscesses, anemia, electrolyte imbalance, perforation of the colon, and carcinoma.

- **Irritable bowel syndrome (Nervous colon)**

- Causes: unknown, Genetic factors, Food sensitivity, bacterial overgrowth and neurotransmitter
- Abdominal cramps, bloating, diarrhea or constipation

قائمة بالأطعمة والمشروبات المسببة للانتفاخ والقولون العصبي :

1. البقوليات: الفاصوليا، العدس، الحمص، البازلاء.
2. الخضروات الصليبية: الملفوف، البروكلي، القرنبيط، براعم بروكسل.
3. منتجات الألبان: الحليب، الجبن، الزبادي (بسبب اللاكتوز) الآيس كريم.
4. البصل والثوم: يحتويان على الفركتانز (ألياف قابلة للذوبان).
5. المشروبات الغازية: تحتوي على غاز ثاني أكسيد الكربون.
6. الأطعمة الدهنية والمقلية: الكعك، الزبدة، الدهون المهدرجة. الوجبات السريعة، النقانق (السجق)، واللحوم المصنعة
7. بعض الفواكه (التفاح، الكمثرى، البطيخ)، الفواكه المجففة (المشمش، الخوخ، الزبيب)..
8. المحليات الصناعية: السوربيتول الموجودة في العلكة، المانيتول، الزيليتول. والحلوى
9. القمح: بسبب محتواه من الجلوتين.

نصائح لتخفيف الانتفاخ:

1. تناول الطعام ببطء: لتجنب ابتلاع الهواء.
2. تقليل الأطعمة الدهنية: لأنها تبطئ عملية الهضم.
3. تجنب المشروبات الغازية والمضغ: (العلكة) التي تزيد من الغازات.
4. مراقبة الأطعمة: تحديد الأطعمة التي تسبب لك الانتفاخ تحديداً وتجنبها.
5. شرب الماء: وتناول الألياف تدريجياً لتجنب الانتفاخ

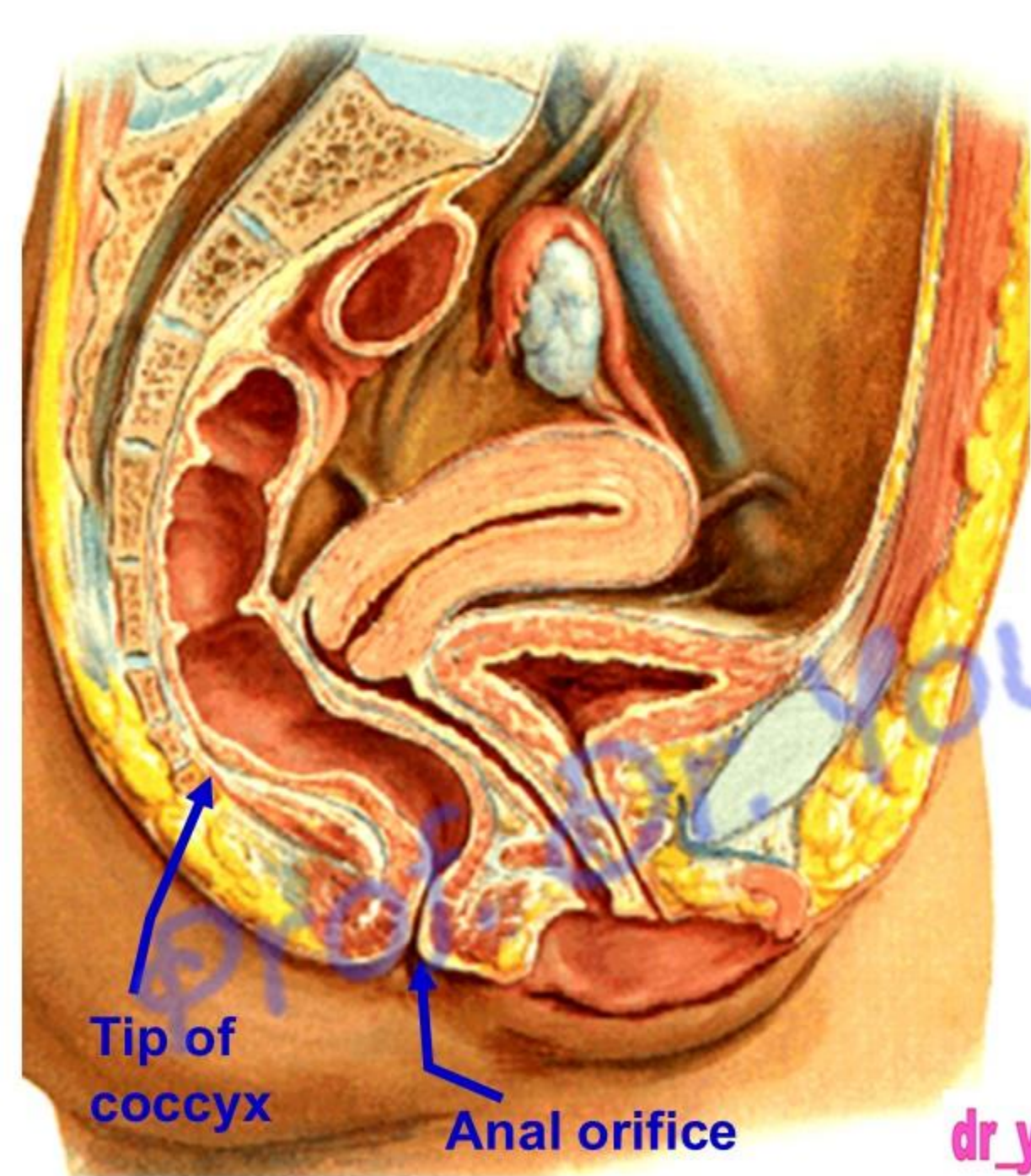
العلاج بالأعشاب: النعناع (لإرخاء العضلات)، الشمر (لطردهم الغازات)، اليانسون (لتهديئة الأمعاء)، البابونج (كمضاد

للتهاب)، الزنجبيل (لتحسين الهضم)، والكرم والكمون (يساهم في تقليل انتفاخ البطن والغازات) يُنصح بتناولها كمشروبات دافئة، يمكن مزج الشمر، اليانسون، الكمون، النعناع،

dr_youssefhussein@yahoo.com

Anal canal

اليو تيوب د. يوسف حسين



- **Anal Canal**

**** Beginning**, one Inch below and in front of the tip of the coccyx as a continuation of the rectum.

**** Length**; It is about 4 cm long.

**** End**: It descends downwards and backwards to end at the anus (anal orifice).

اليوثيوب د. يوسف حسين

dr_youssefhusseini@yahoo.com

- **Posterior relations in female**

- **Relations in female**

- **Anterior relations in female**

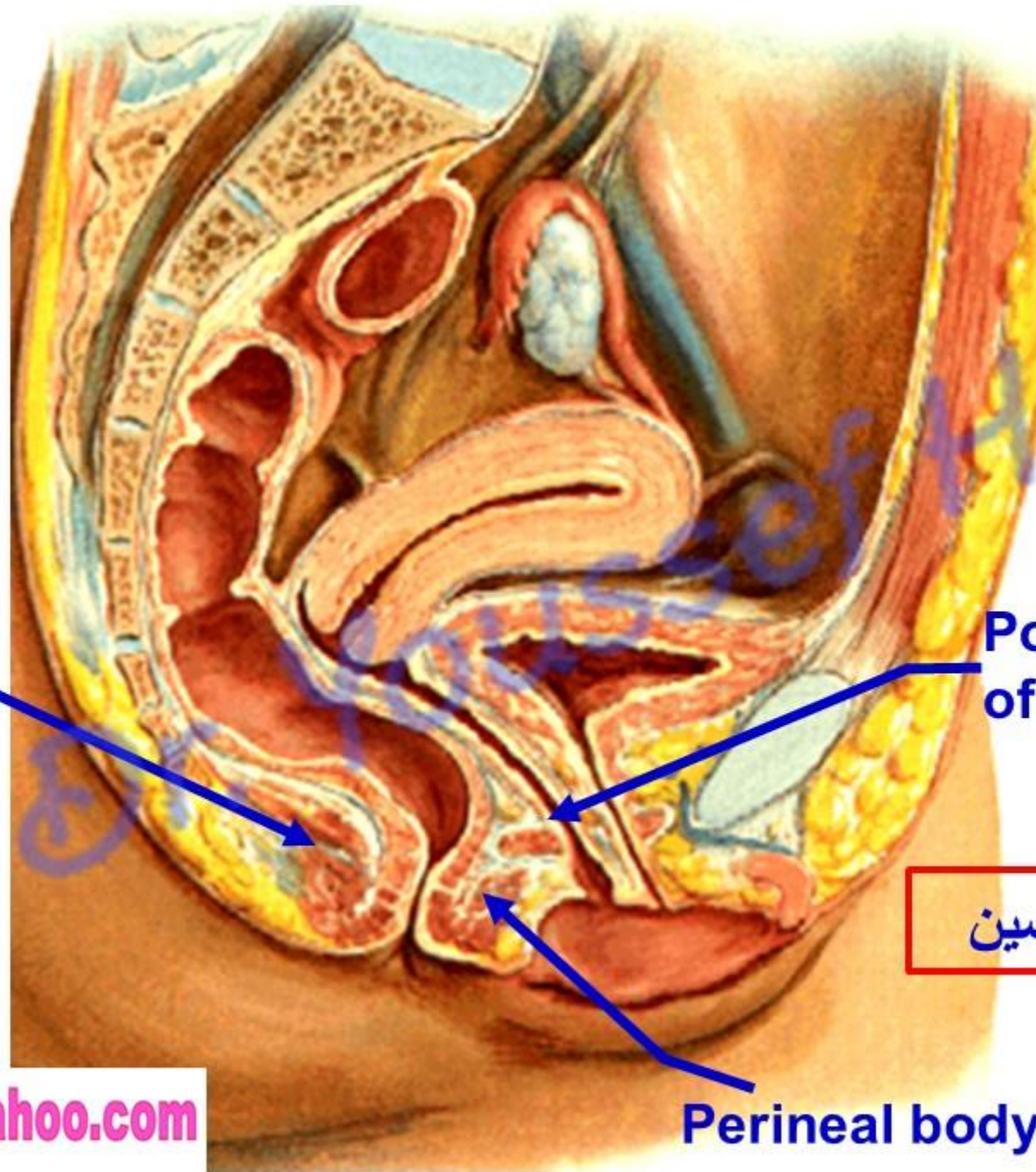
Anococcygeal raphe

Posterior wall of vagina

اليوتيوب د. يوسف حسين

Perineal body

dr_youssefhussein@yahoo.com



• **Relations in male**

• **Posterior relations**

Anococcygeal raphe

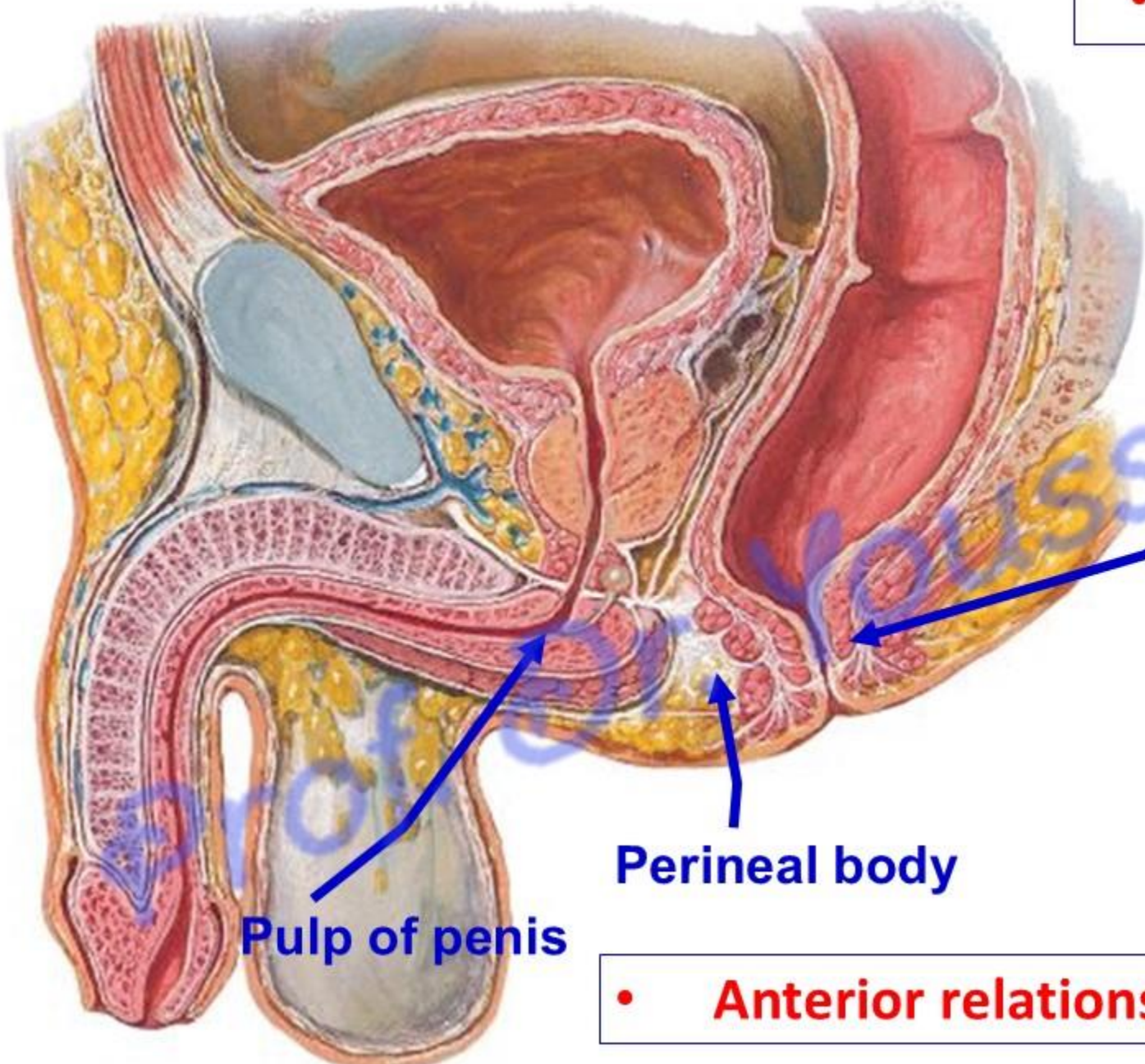
Perineal body

Pulp of penis

• **Anterior relations**

اليو تيوب د. يوسف حسين

dr_youssefhussein@yahoo.com



- **Lateral Relations
in both sex**

Levator ani
(above)

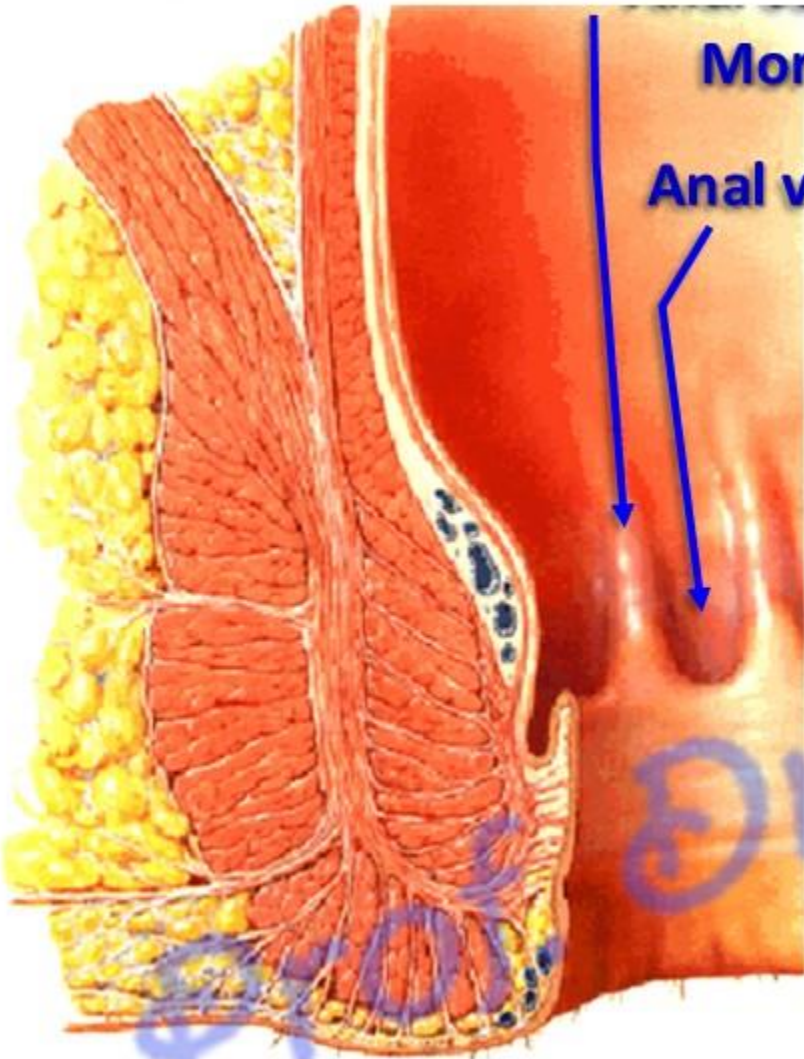
Ischiorectal fossa
(below)

اليوثيوب د. يوسف حسين

dr_youssefhussein@yahoo.com

Morgagni

Anal valve of Ball



اليوتيوب د. يوسف حسين

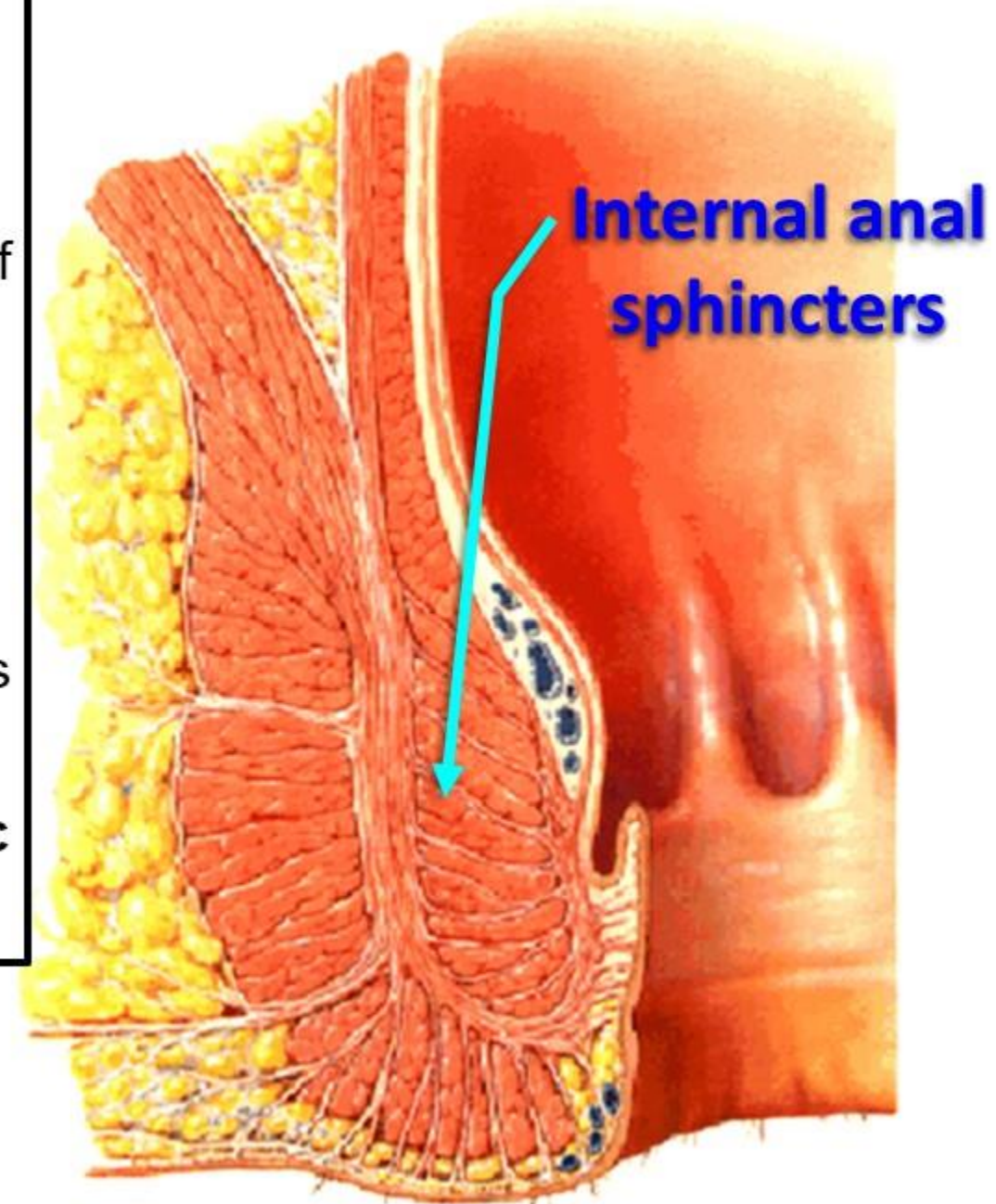
** Internal appearance (Mucous membrane) of the anal canal

- **1. Upper part**, (1.5 cm) mucous part, endodermal
 - It shows 6-10 vertical folds called **anal columns of Morgagni**.
 - The lower end of the anal columns is connected by crescentic folds called **anal valves of Ball**.
 - Above each anal valve there is a small recess called **anal sinus** receiving the opening of the anal gland.
- **2- Middle part** (1.5 cm); transitional zone;
 - It is devoid of sweat and sebaceous glands.
- **3- Lower part**, (1 cm), ectodermal in origin,
 - It is lined by true skin containing sweat and sebaceous glands
- **Anal fissure**, tear of the lining of the anal canal leading to severe pain and bleeding.

- **Sphincters of the anal canal**

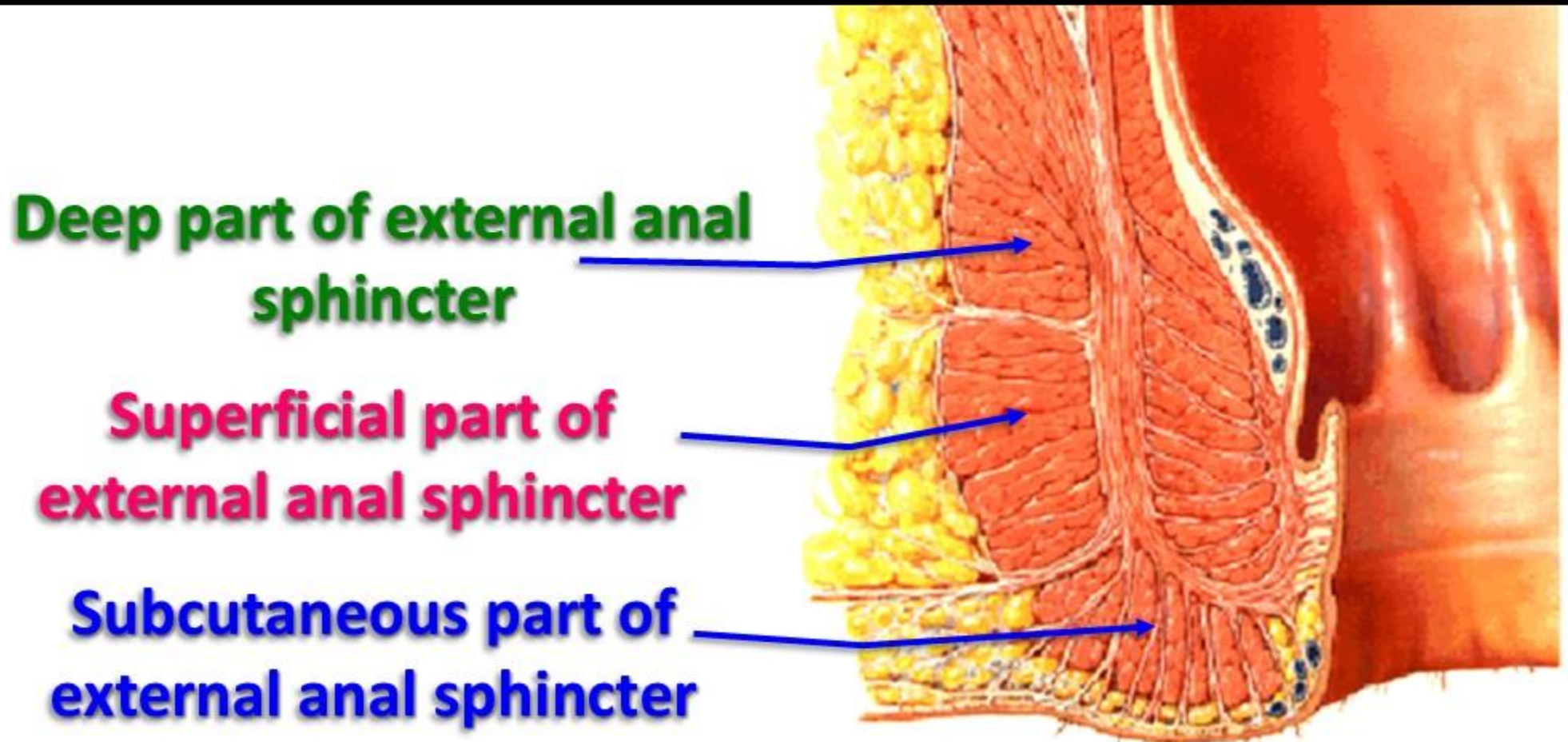
- A- Internal anal sphincter:**

- It surrounds the **upper 2/3** of the anal canal.
 - It is a thickening of **circular smooth muscle** layer of the gut.
 - It is thickened in chronic constipation.
 - It is an **involuntary** muscle.
 - **Nerve supply** by autonomic nerves.
 - **Parasympathetic** fibers from **S2, 3, 4**, produces **relaxation** of the sphincter.
 - **Sympathetic** fibers from **inferior hypogastric plexus**, produces **contraction** of sphincter.



B- External anal sphincter (L.S.);

- It surrounds the **whole length** of the anal canal; outside the internal anal sphincter.
- It is formed of **striated muscle** fibers.
- It is a **voluntary** muscle.
- **Nerve supply** by inferior rectal nerve from pudendal nerve.



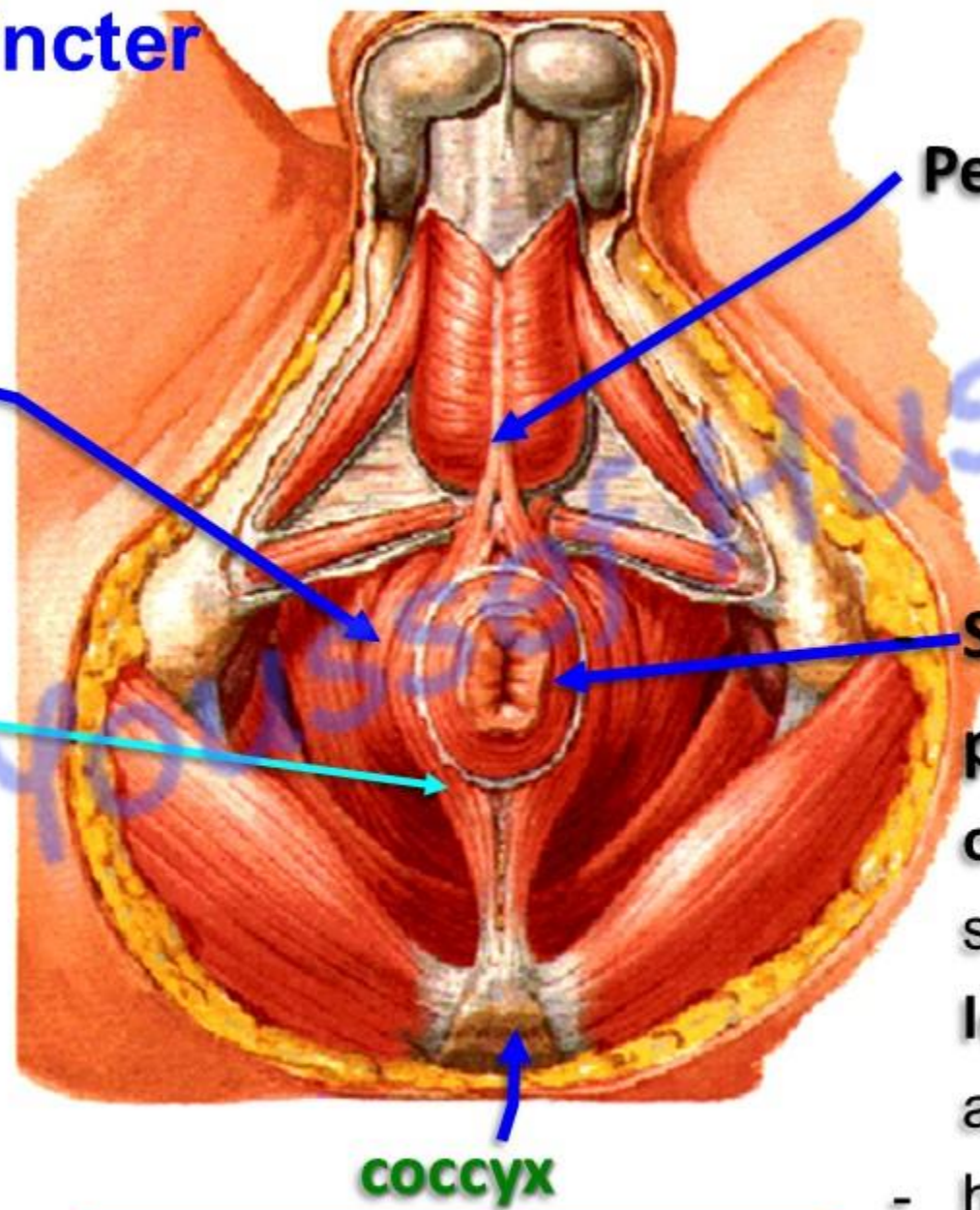
T.S. External anal sphincter

Deep part

- It is a **thick circular band** surrounding the **upper part** of the internal anal sphincter. has **no bony** attachment

Superficial part

- It is formed of **two bands** surrounding **lower part** of the internal anal sphincter.
- They arise from the coccyx and inserted into the perineal body.



Perineal body

Subcutaneous

part: It is a **thick circular band** surrounding the **lower part** of the anal canal.

- has **no bony** attachment

COCYX

اليو تيوب د. يوسف حسين

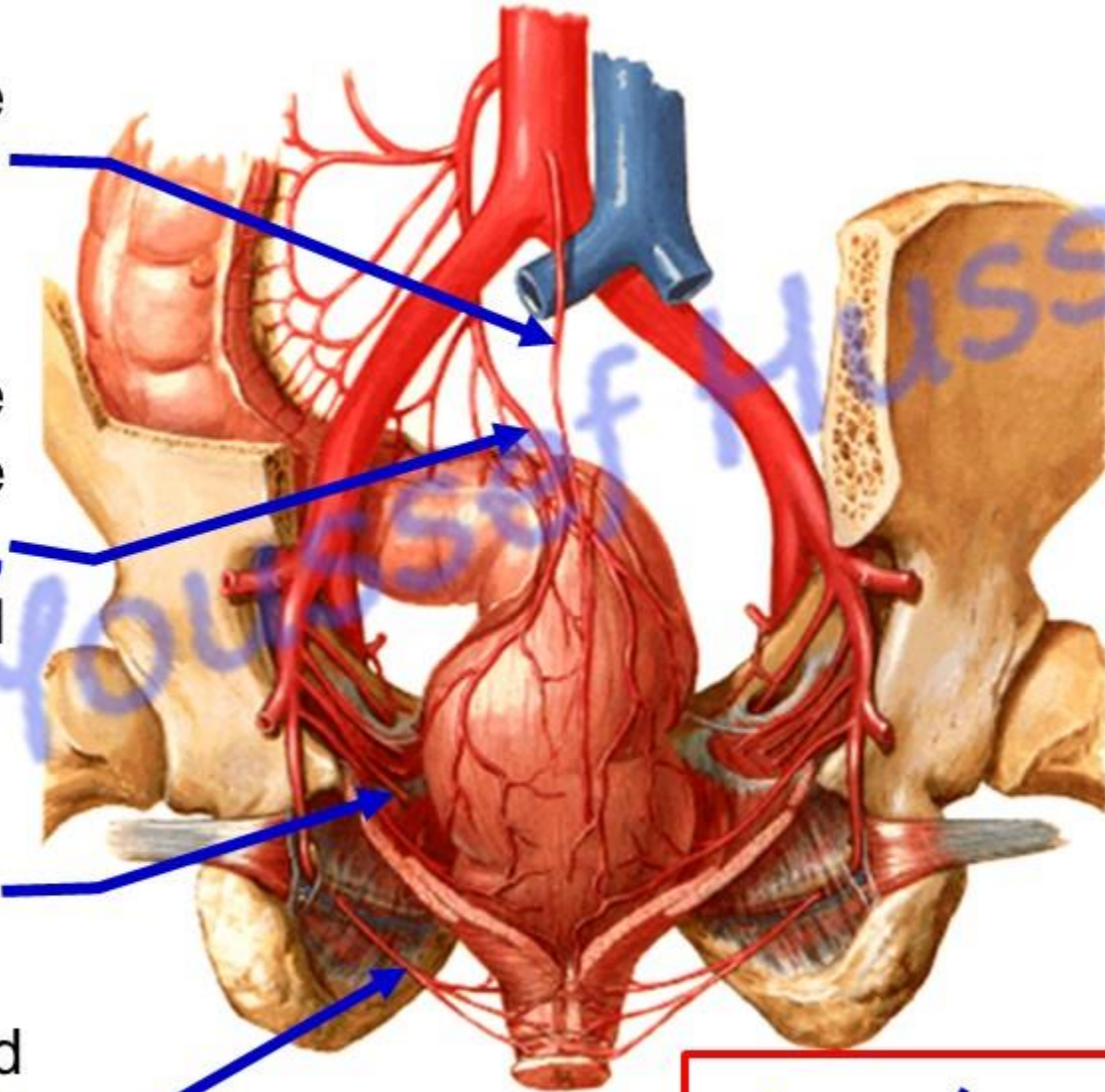
Arterial supply of the rectum and anal canal

Median sacral artery, (single branch) from **abdominal aorta**.

Superior rectal artery, (single branch) continuation of the **inferior mesenteric artery**, anastomosis with the middle and inferior rectal arteries

Middle rectal arteries (right and left) from the **internal iliac artery**

Inferior rectal arteries (right and left) from the **internal pudendal artery**.



اليوثيوب د. يوسف حسين

dr_youssefhussain@yahoo.com

Venous Drainage

Median sacral vein
ends in left common
iliac vein **or** IVC

IVC

Inferior Mesenteric Vein

Superior Rectal Vein

Internal iliac Vein

Middle Rectal Vein

Internal Pudendal
Vein

Inferior Rectal Vein

Six Radical Veins

Internal rectal
venous plexus

External rectal
venous plexus

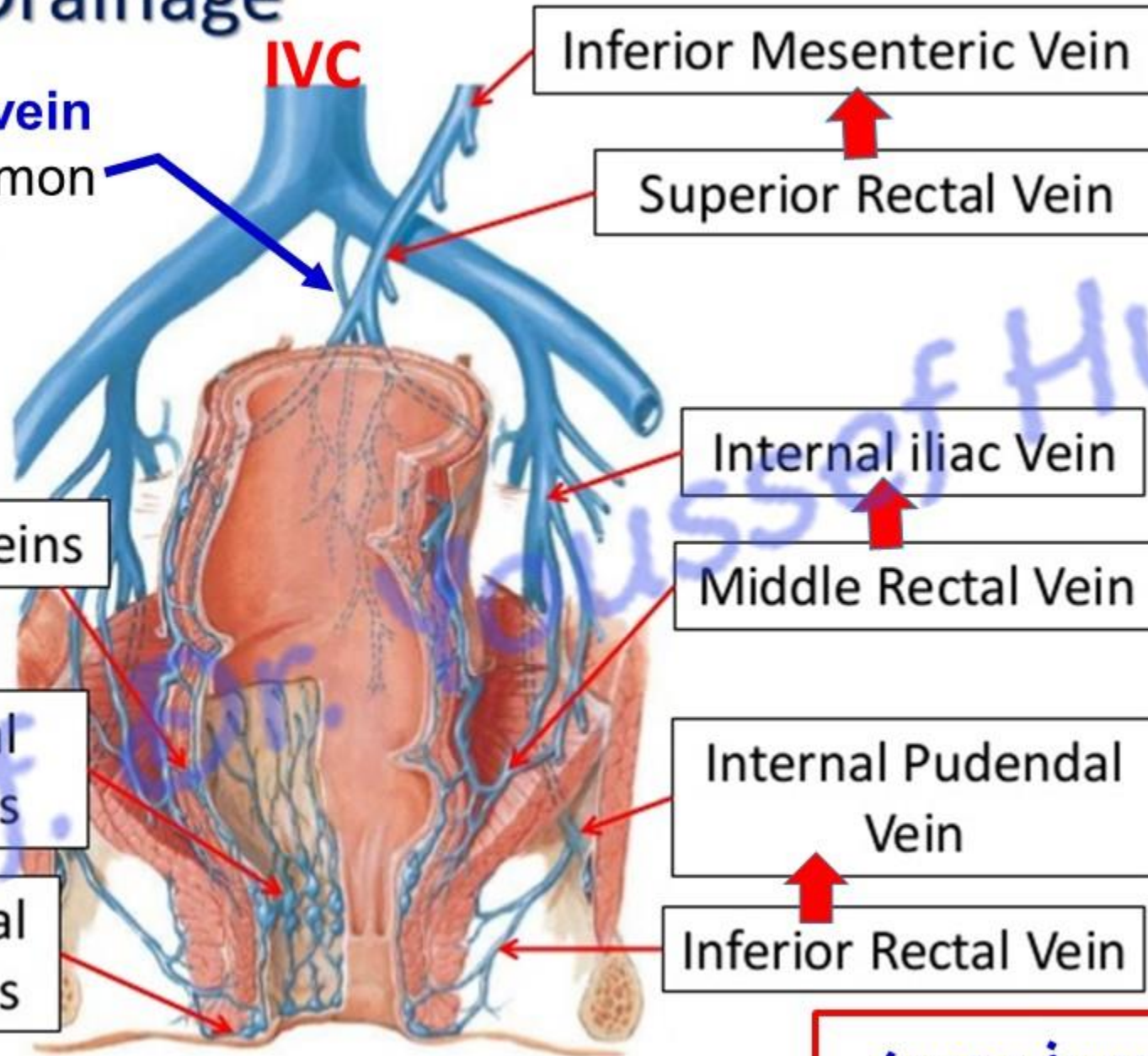
P

S

S

الـيـوتـيـوب د. يـوسـف حـسـين

dr_youssefhussein@yahoo.com

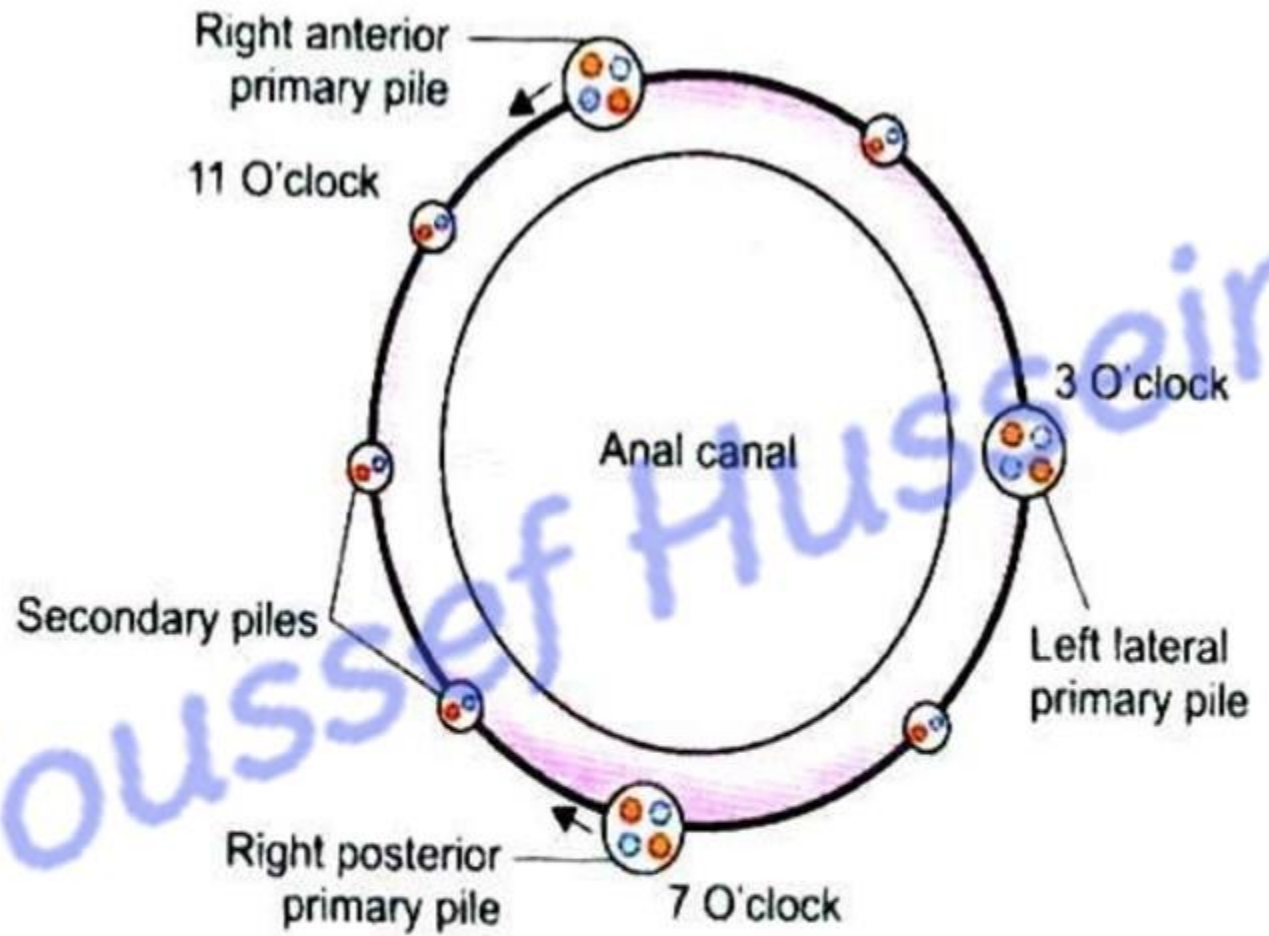
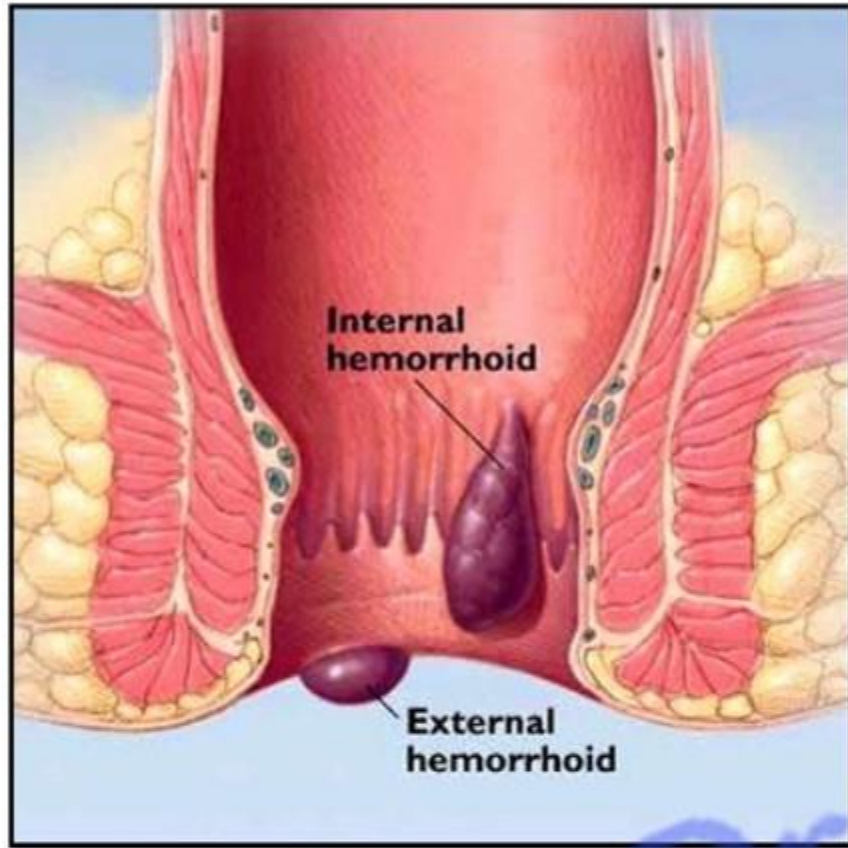


Internal rectal venous plexuses

- It lies in the **submucosa**.
- It is drained mainly by **superior** rectal vein (**portal**).
- Dilatation of this plexus leads to **internal piles**.
- It occurs mainly at the **3, 7, 11** O'clock positions.
- **Painless, bleeding** and prolapse from the anal opening

External rectal venous plexuses

- It lies **outside** the muscle wall
- It is drained mainly by **middle** and **inferior** rectal veins (**systemic**).
- Dilatation of this plexus leads to **external piles**.
- It occurs under the skin around the anus
- **Painful and bleeding.**



Hemorrhoids (Piles): Swollen (enlarged) and inflammation of veins in the wall of the anal canal leading to bleeding and pain

اليوتيوب د. يوسف حسين

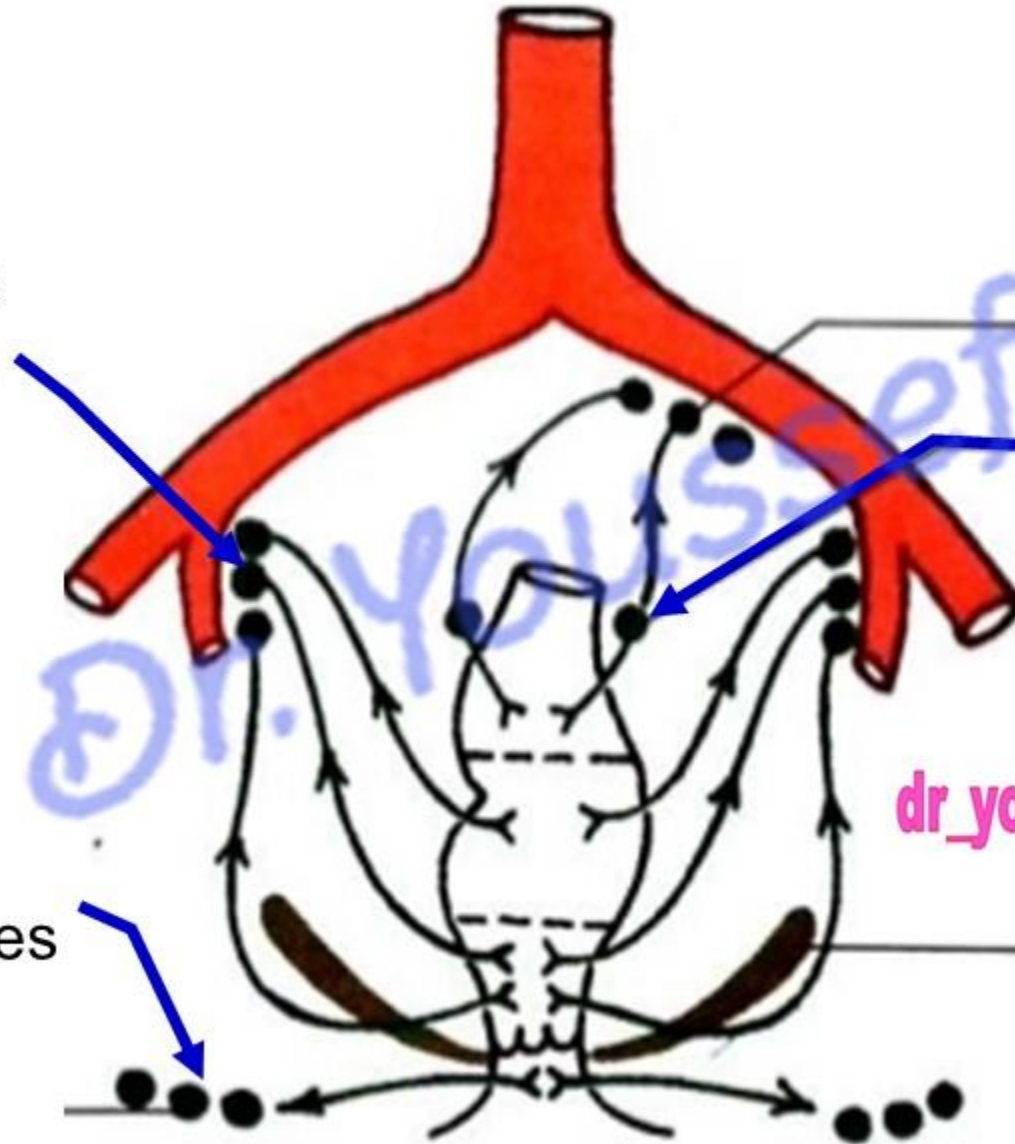
dr_youssefhussein@yahoo.com

Lymphatic drainage of the rectum & anal canal

Middle part into the **internal iliac** lymph nodes

Upper part drains into **pararectal** then to inferior mesenteric lymph nodes.

Lower part drains into the **superficial inguinal** lymph nodes




dr_youssefhussein@yahoo.com

اليوثيوب د. يوسف حسين

https://www.youtube.com/channel/UCVSNqbibj9UWYaJdd_cn0PQ

يُمنع أخذ السلايدات بدون
إذن المحرر واي اجراء
يخالف ذلك يقع تحت طائلة
المسؤولية القانونية
جميع المعلومات للاستخدام
التعليمي فقط

اليوتيوب د. يوسف حسين



<https://www.youtube.com/@ProfDrYoussefHusseinAnatomy/playlists>