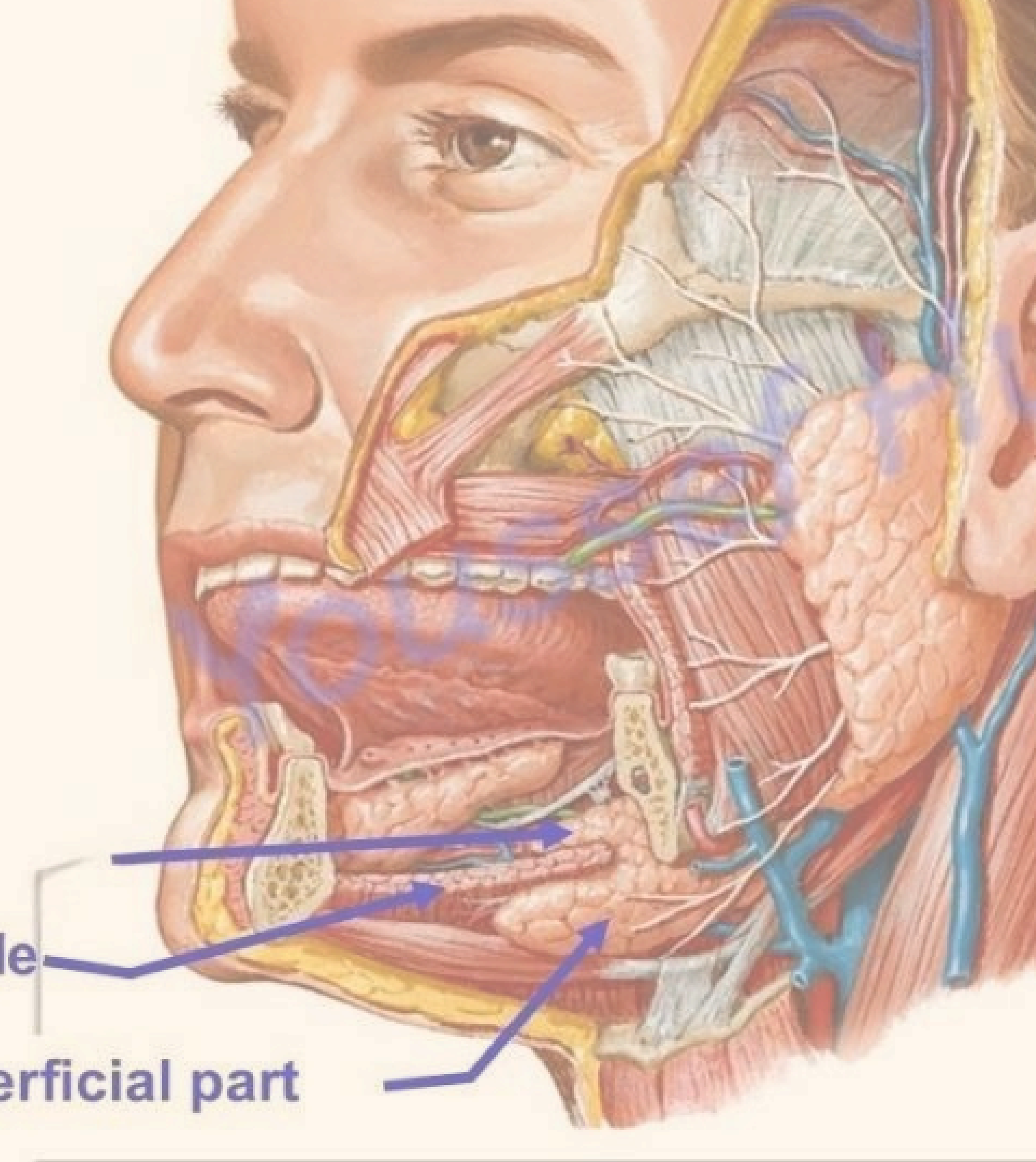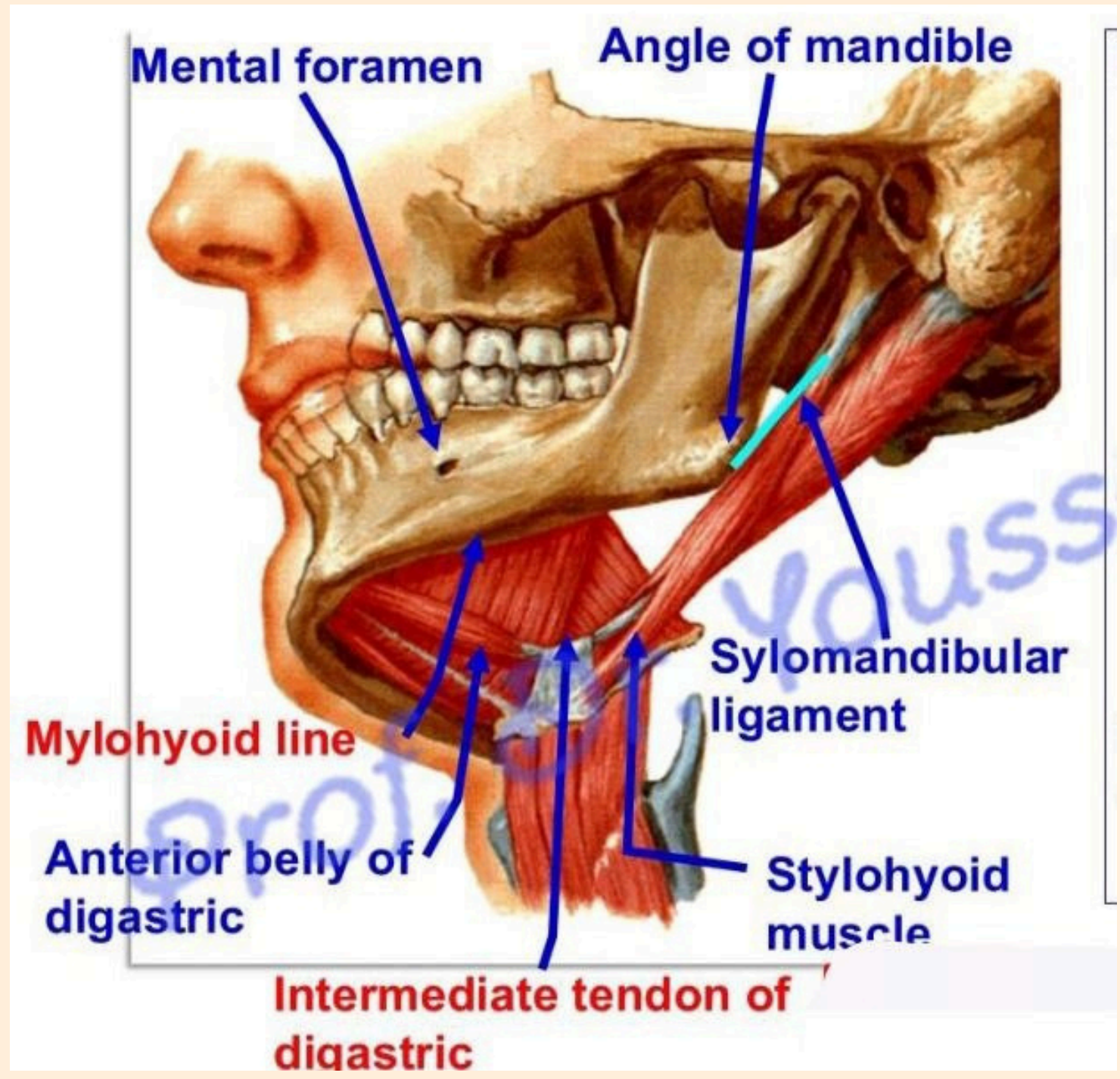
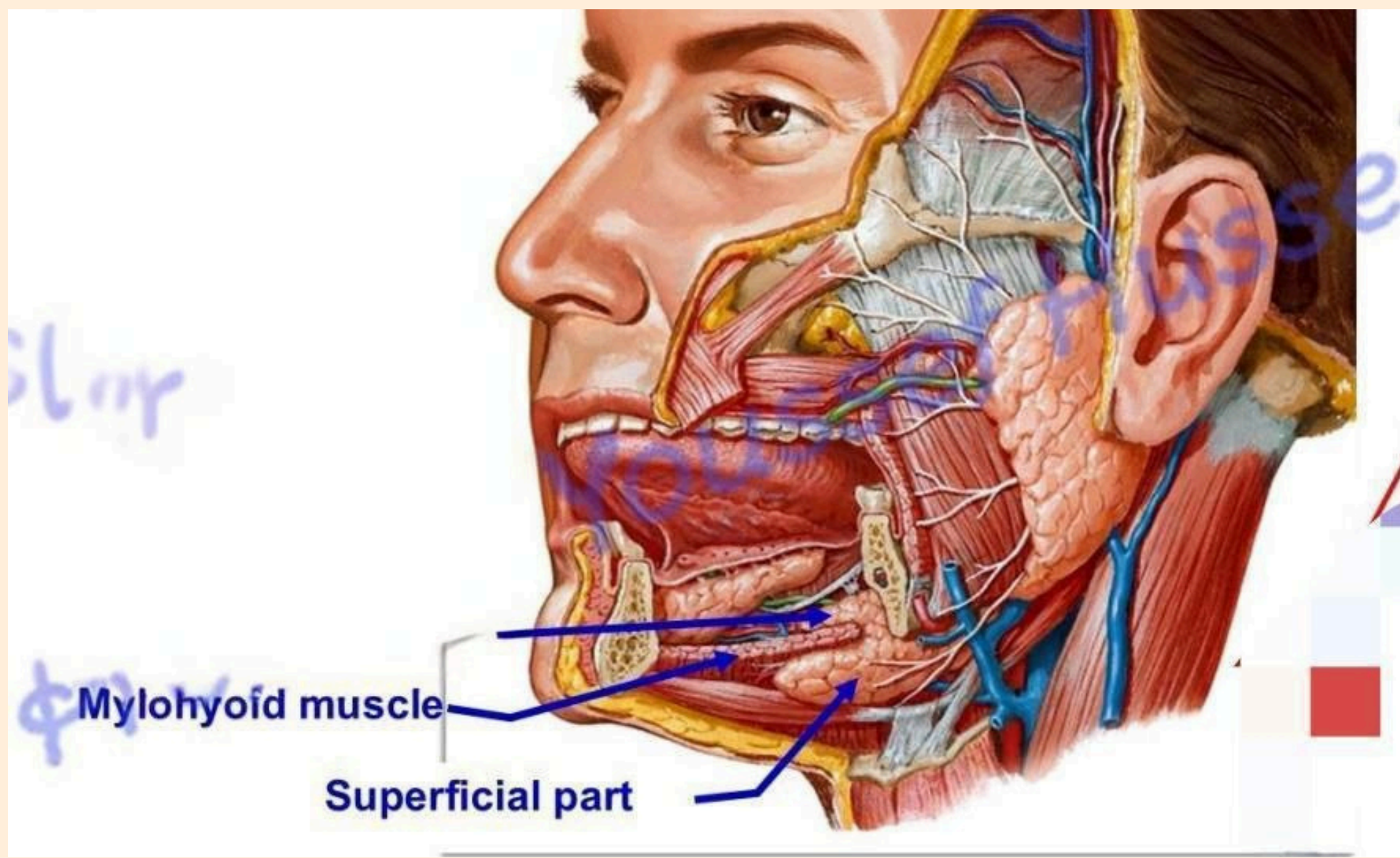
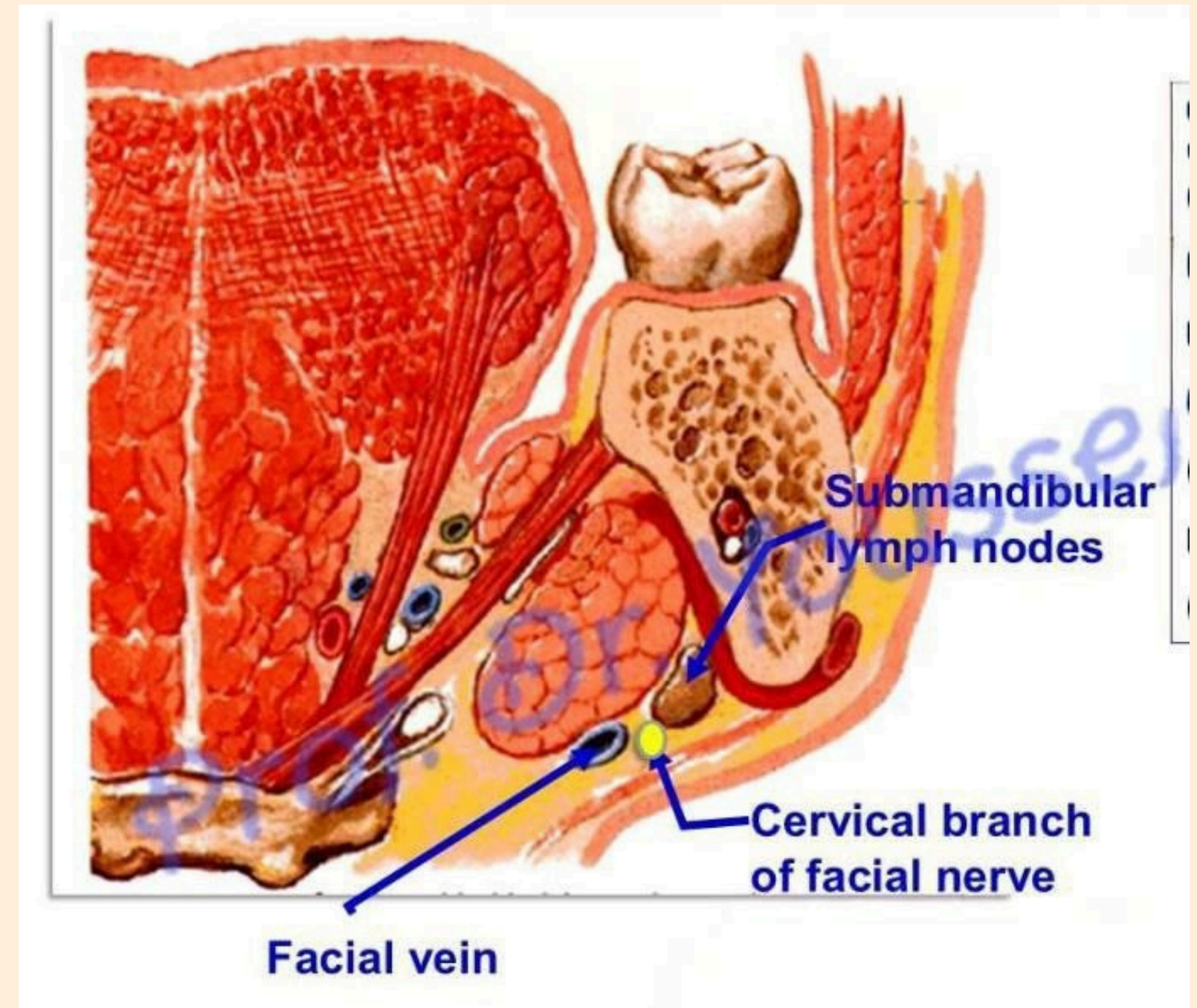
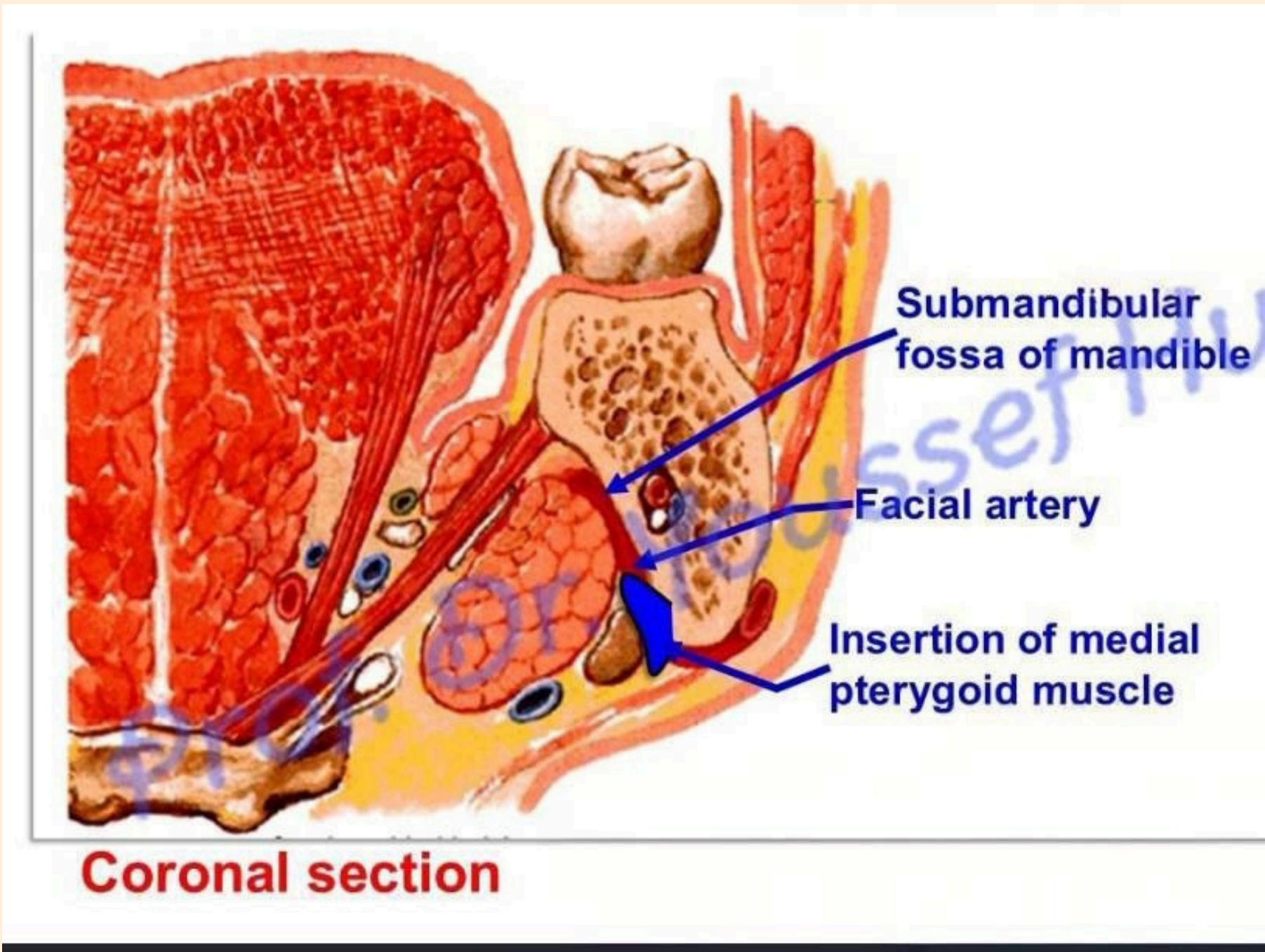


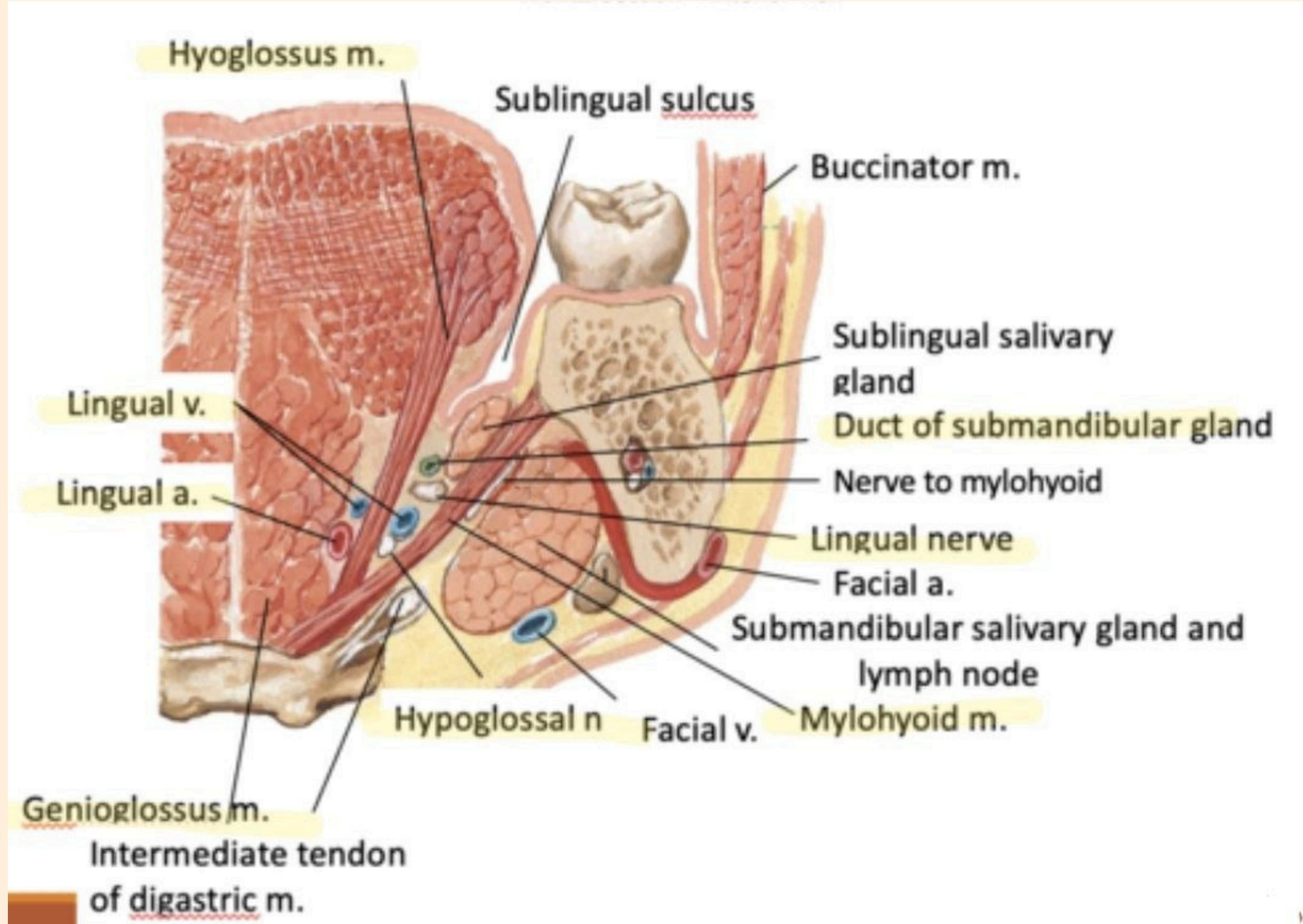
# Anatomy

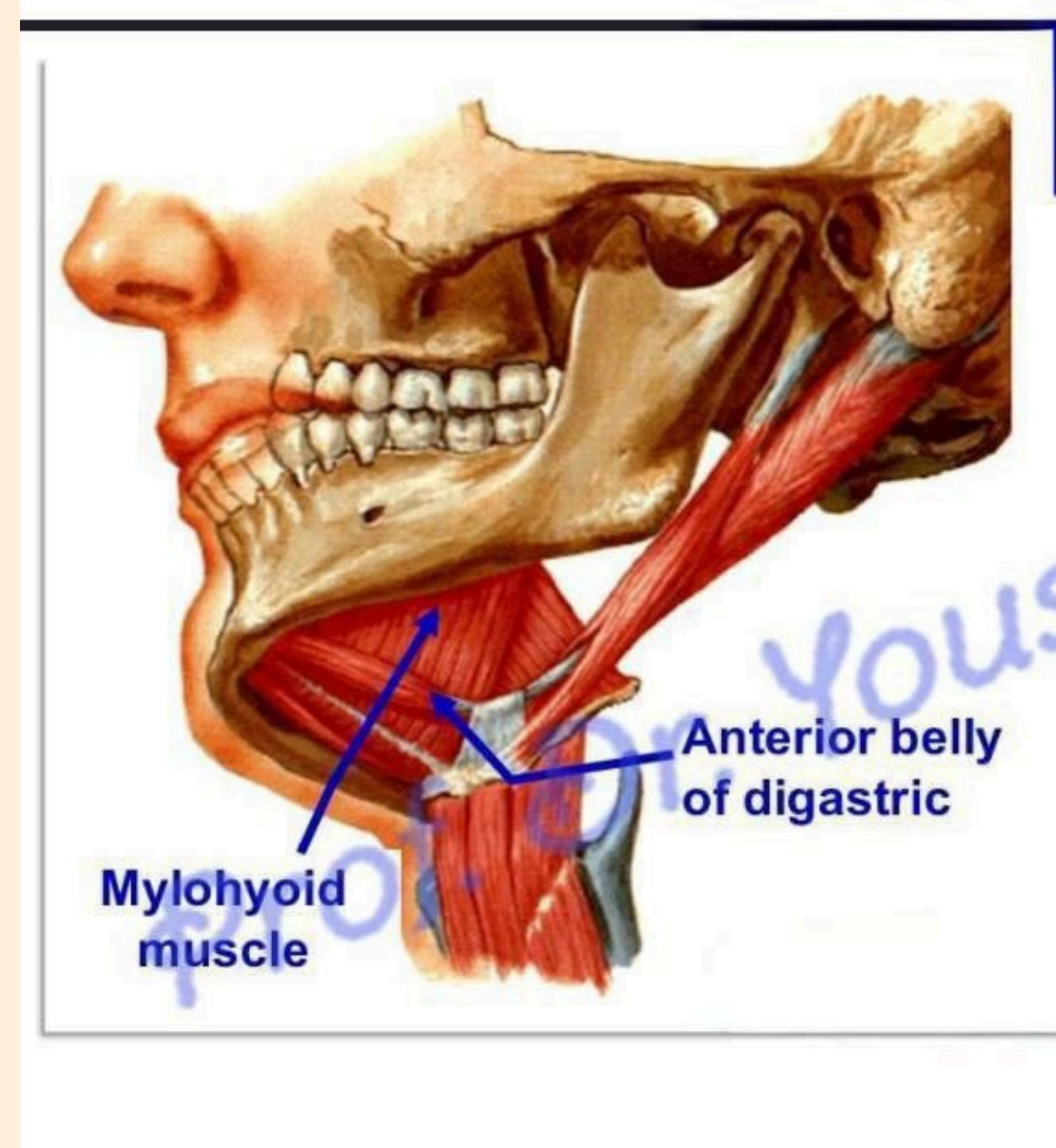
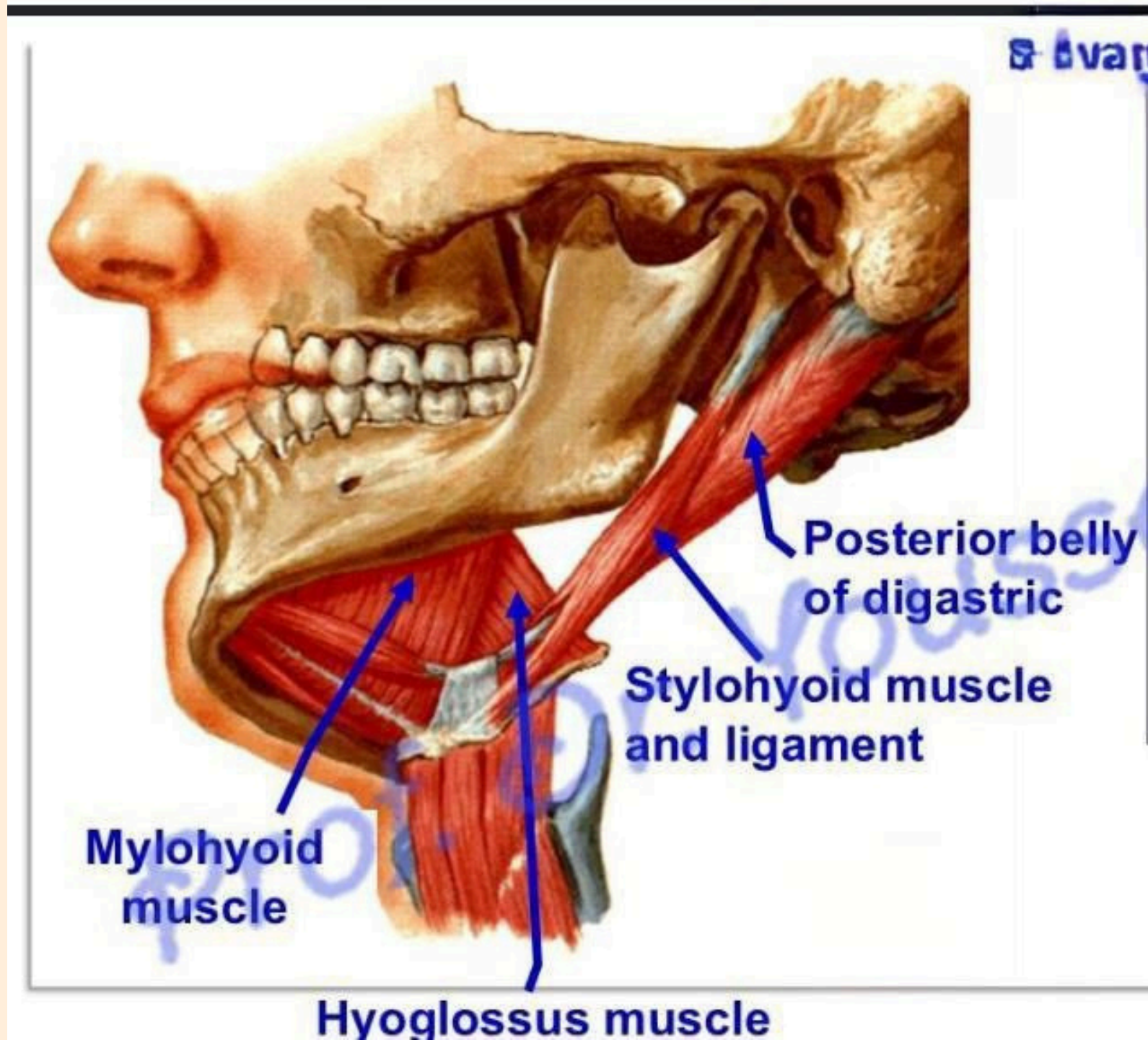
## LAB 3

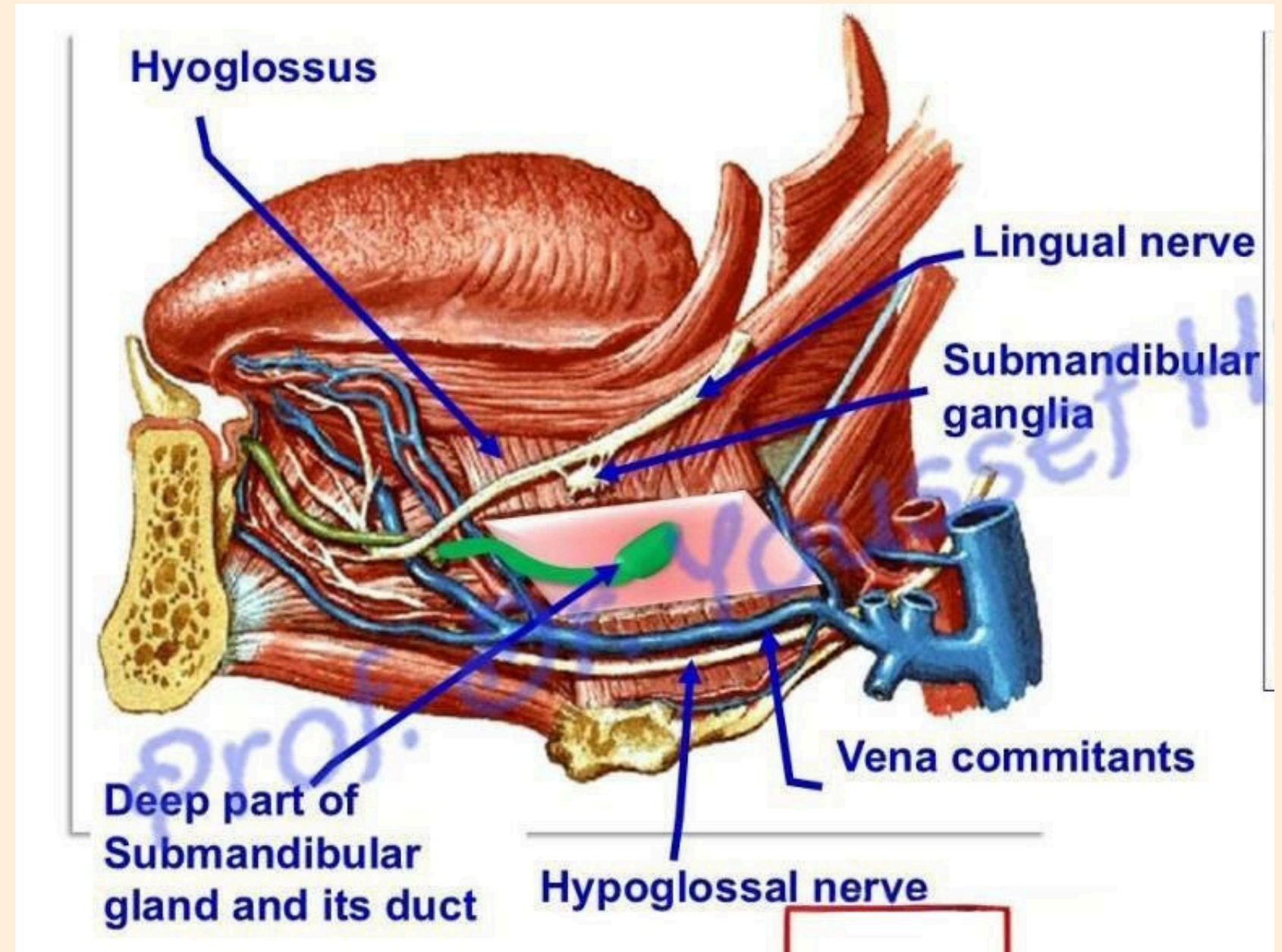
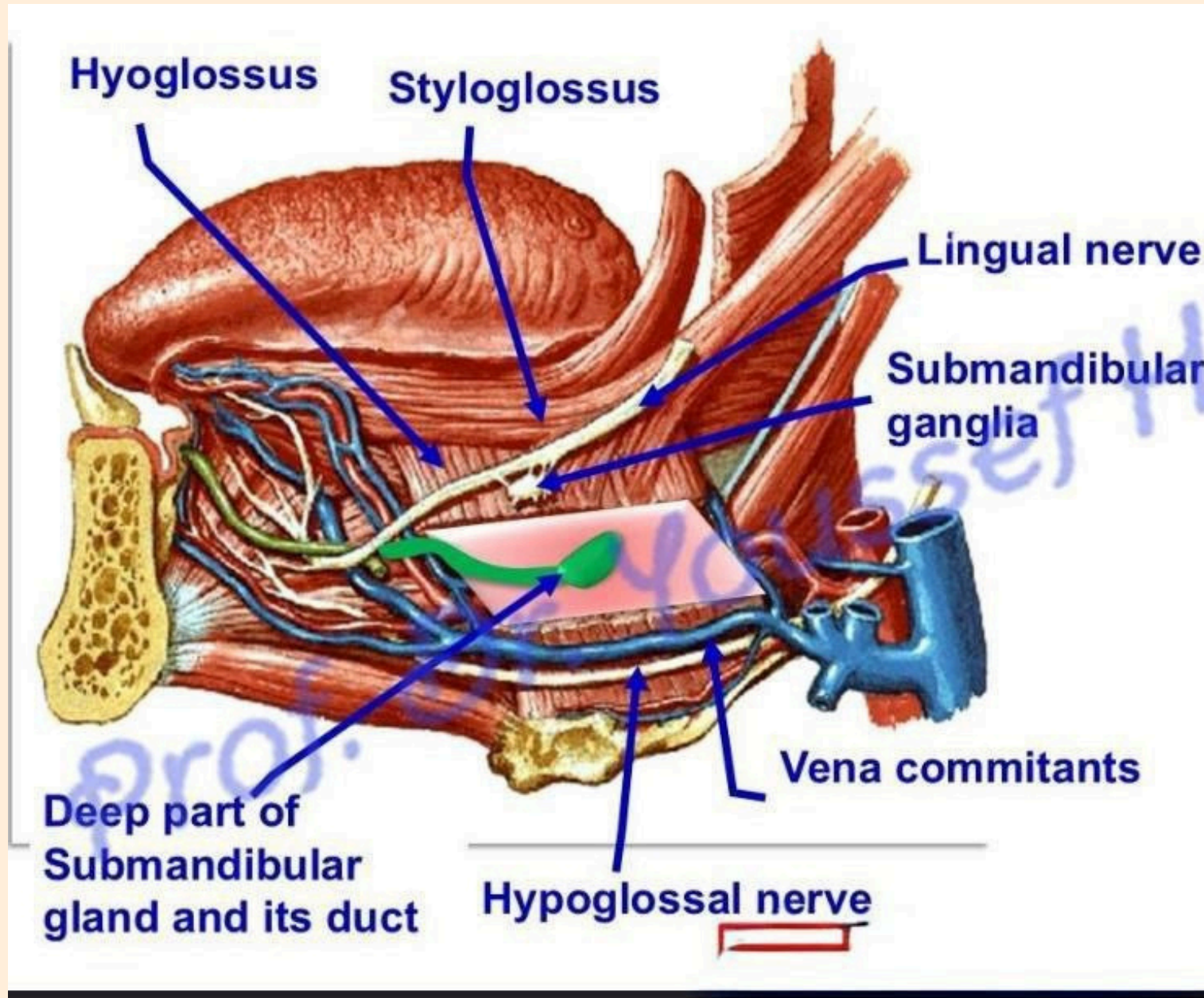
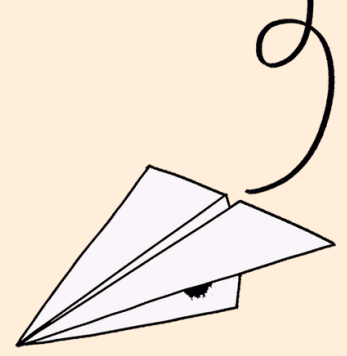


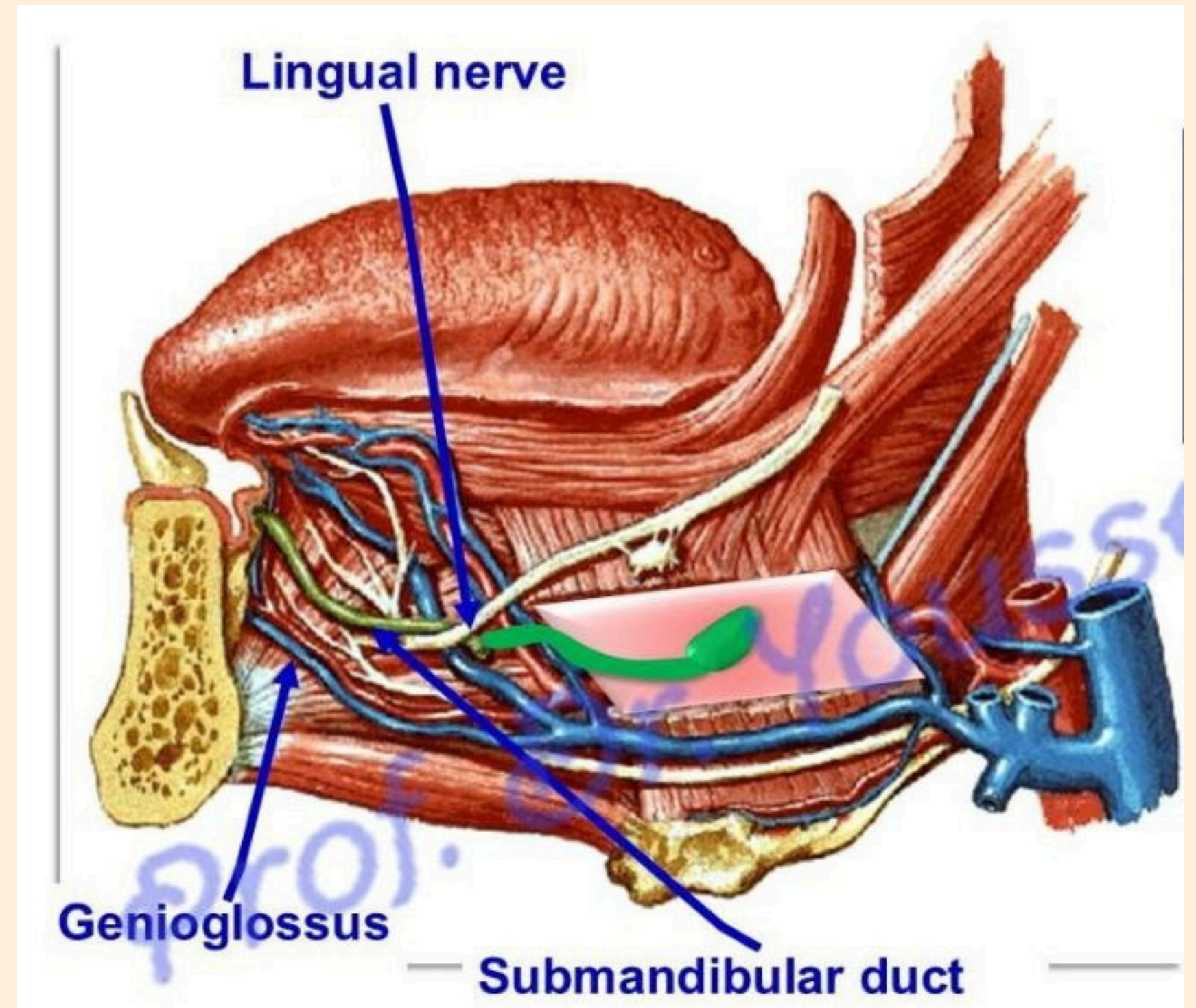
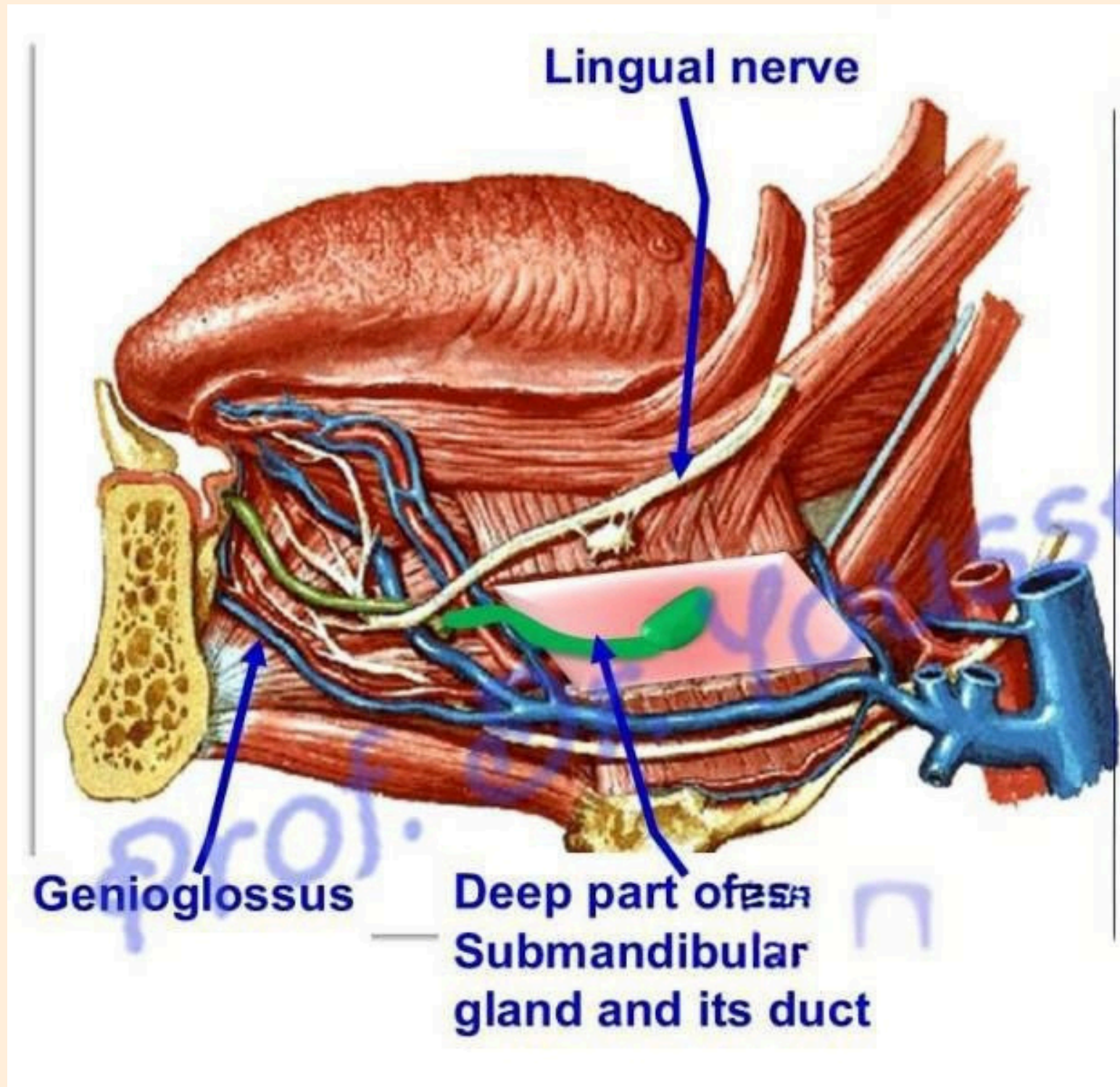


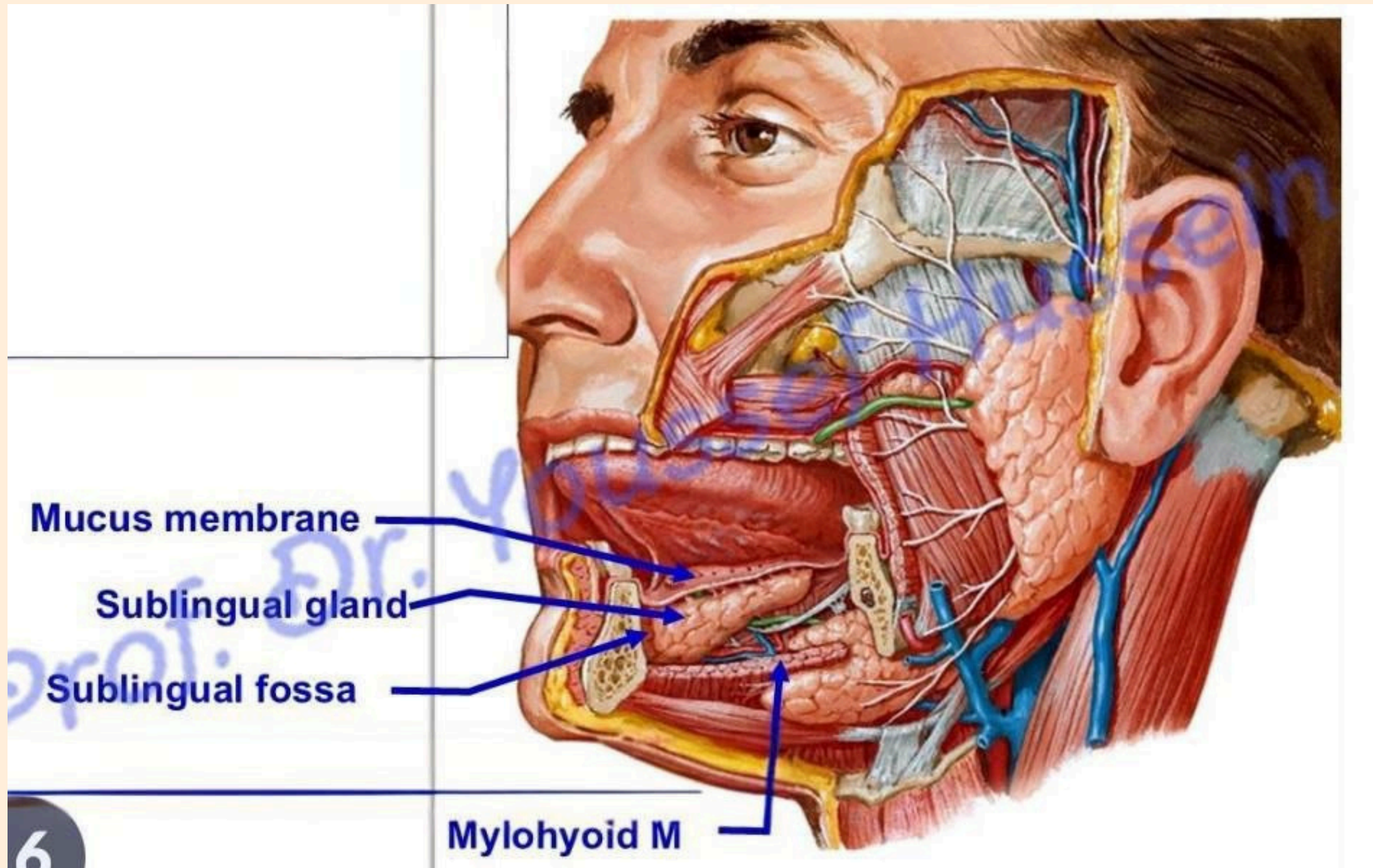
صورة خارجية ماهو محدد باللون الأصفر ذكرها الدكتور وطالب بها



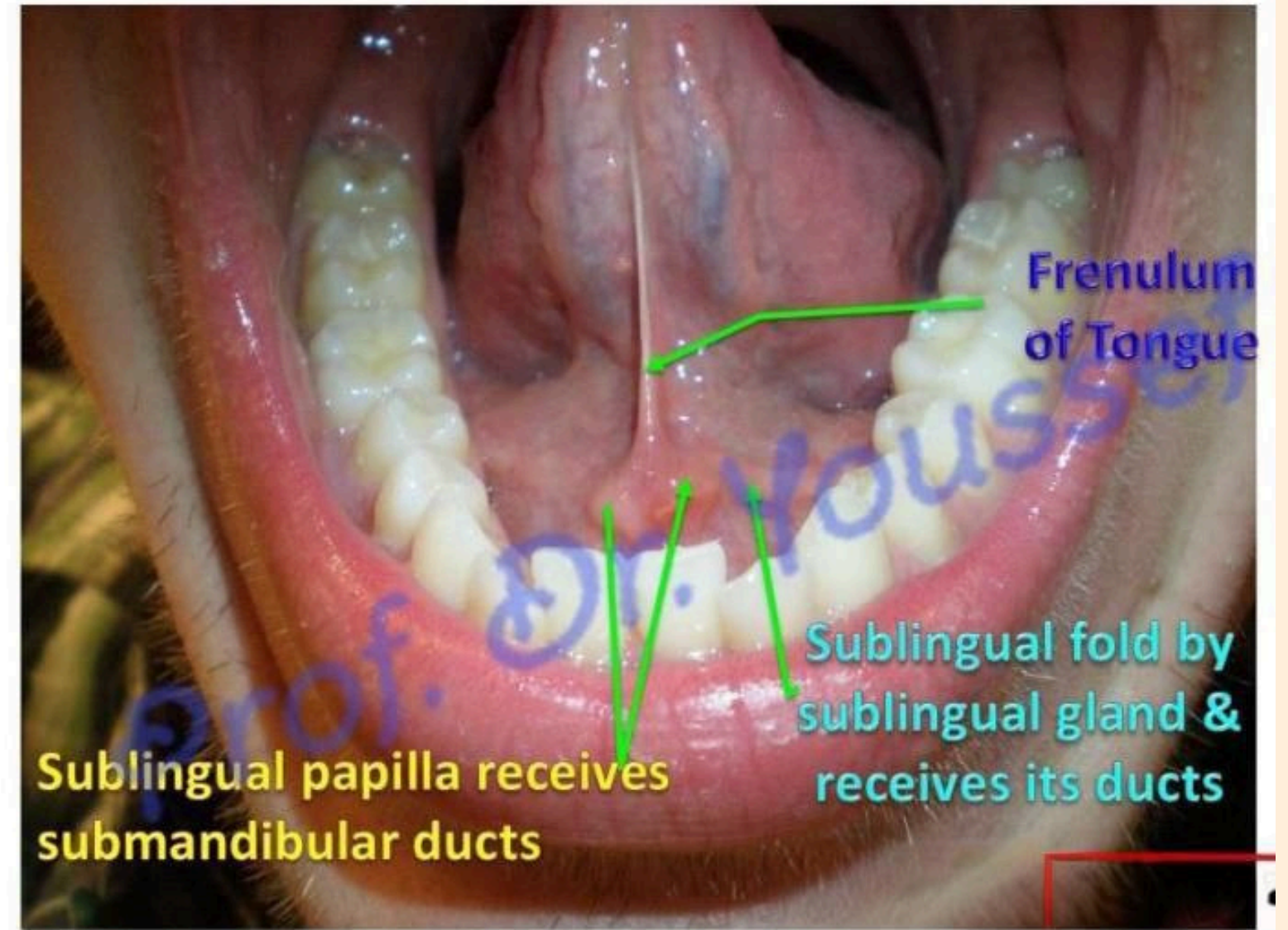


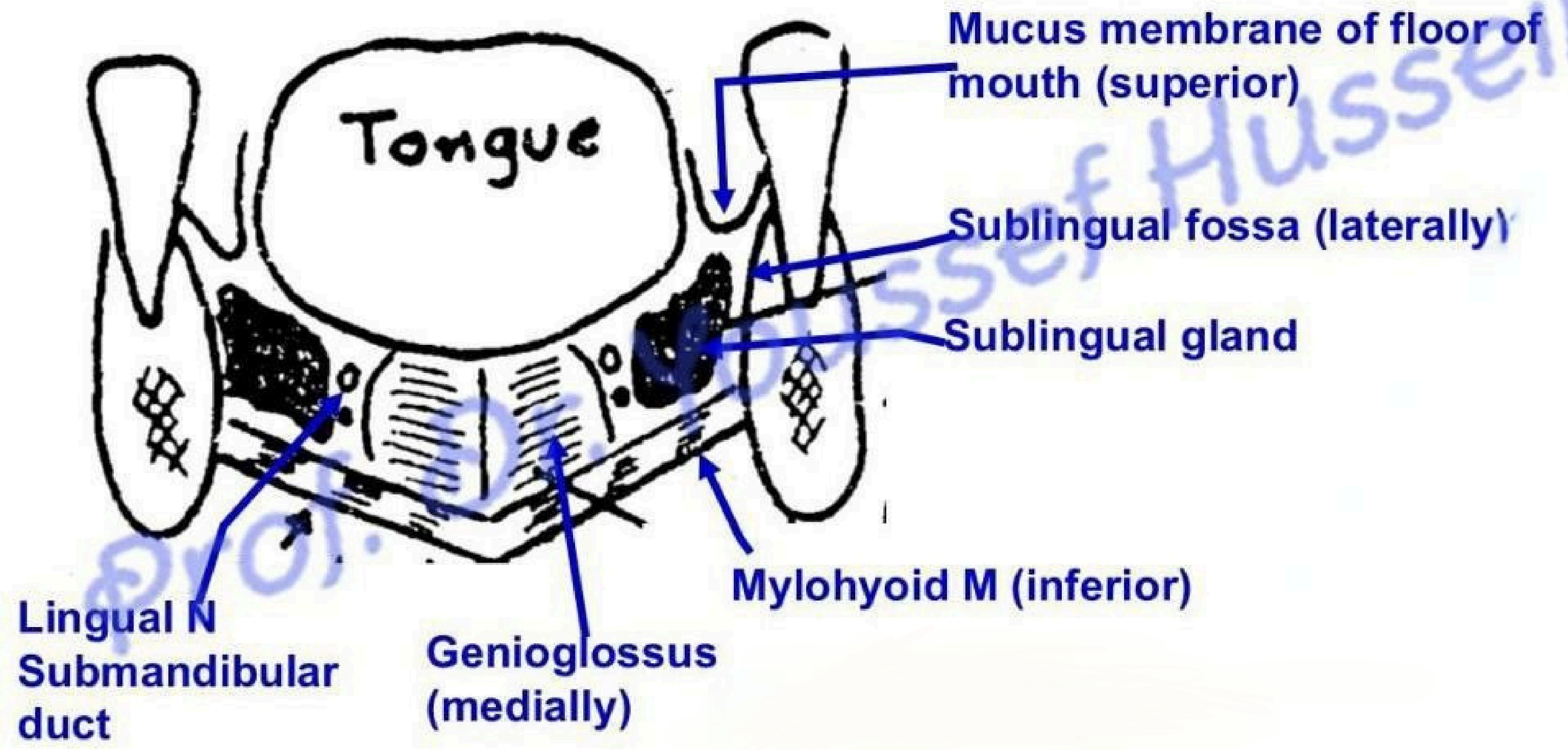


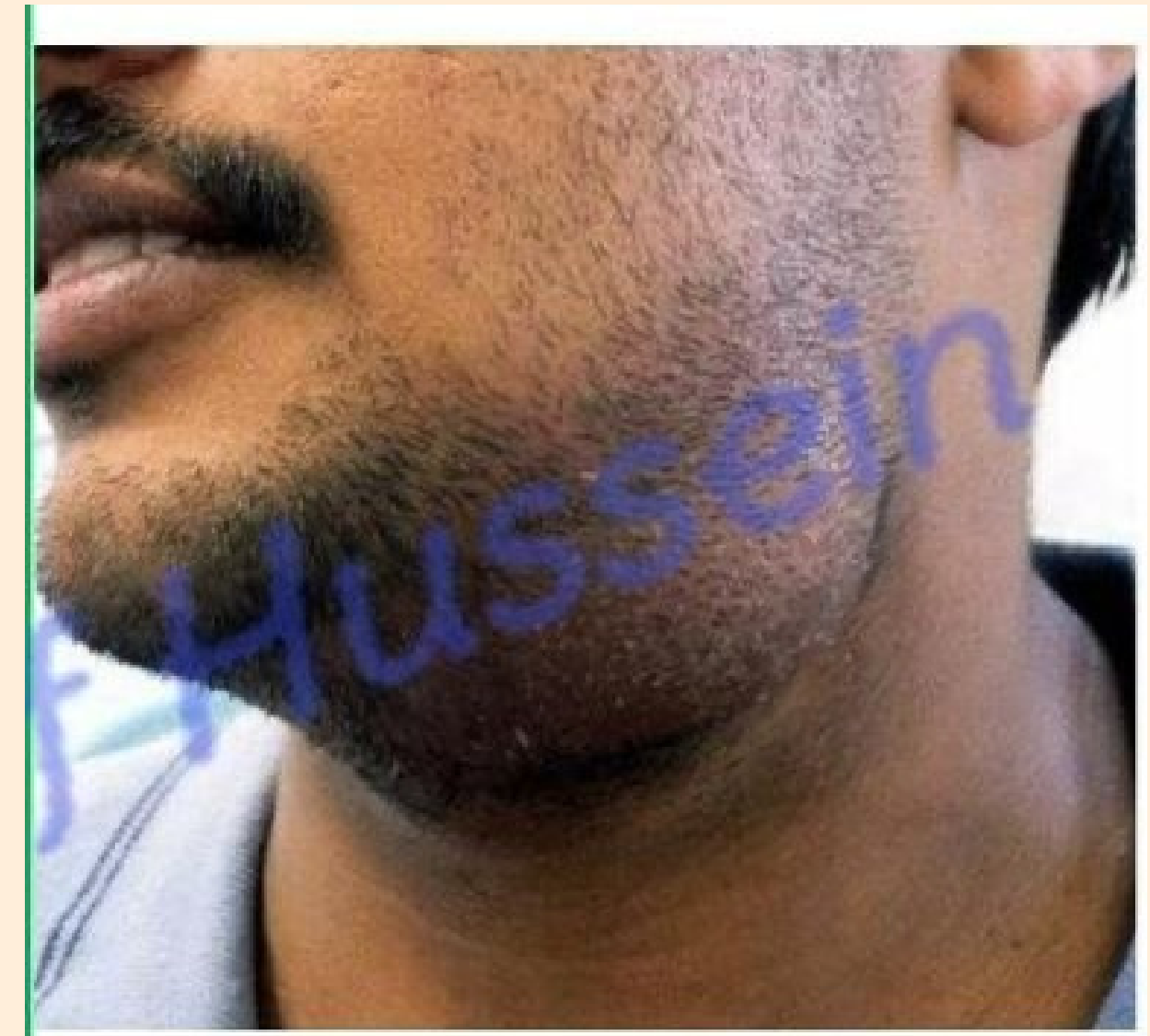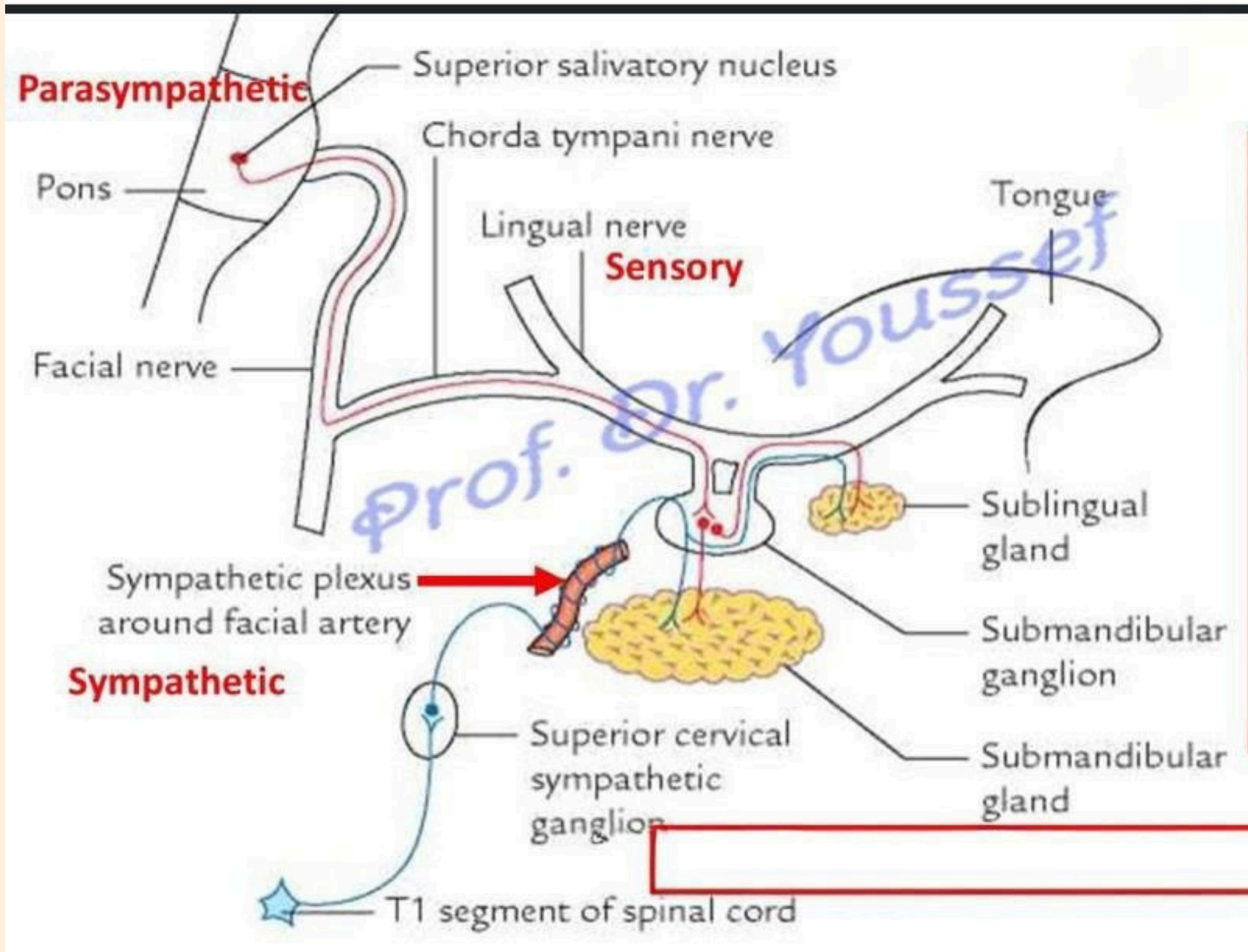




### Floor of mouth cavity







بالتوفيق... لا تنسونا من صالح دعائكم

الطب والجراحة  
لجنة