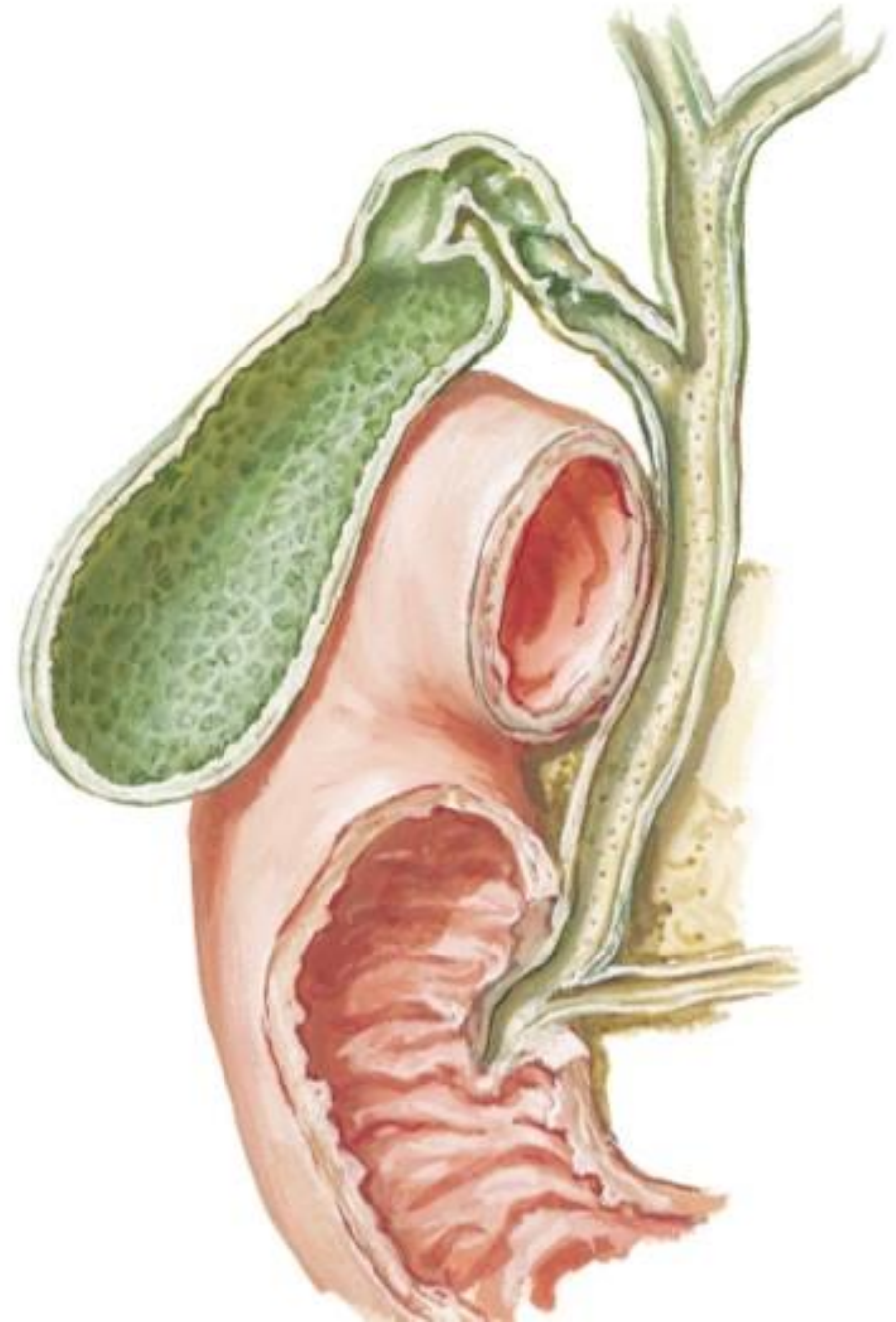


BILIARY SYSTEM

BY

DR ABULMĀTY MOHAMED
ASSISTANT PROFESSOR
ANATOMY & EMBRYOLOGY
MUTAH UNIVERSITY



PARTS OF THE BILIARY SYSTEM

intra hepatic biliary system

- 1-Bile canaliculi
- 2-Bile ductules

Extrahepatic biliary system

- 1- 2 hepatic ducts (Rt, Lt) :-

- 2- common hepatic duct:-

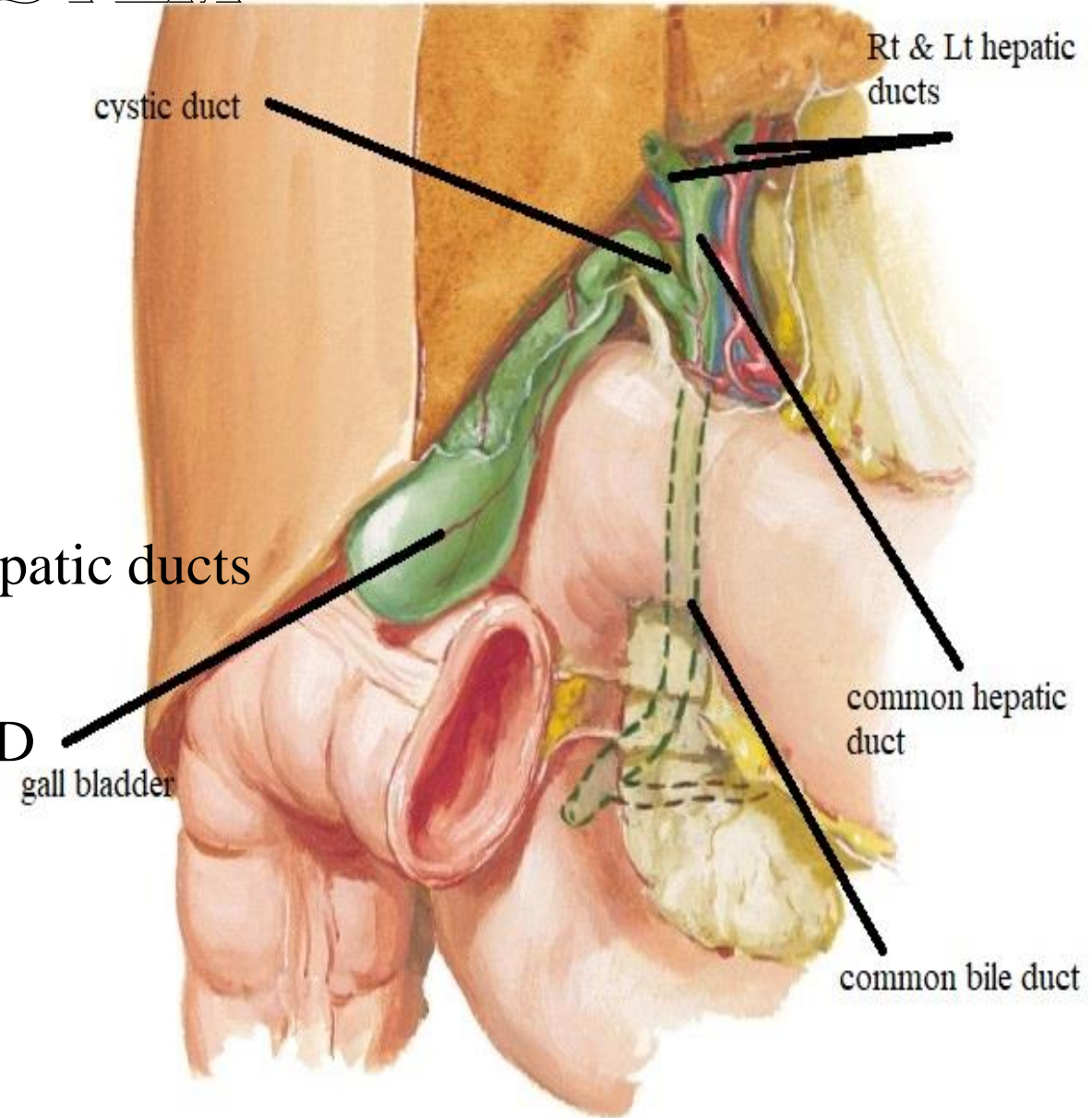
-formed at porta hepatis by union of the rt. & lt. hepatic ducts

-4 cm

-Joined by cystic duct (at acute angle) to form CBD

- 3- gall bladder & cystic duct

- 4-common bile duct CBD



GALL BLADDER

site:- fossa for gall bladder on inferior surface of rt. lobe liver.

Size :- 10 cm **capacity:-** 30-50 ml

Shape :- pear shape has

fundus: the part projecting beyond the inferior border of the liver

body: the central part of the gall bladder

neck:- the narrow upper end

Hartmann's pouch:-

projects backwards from the wall of the neck

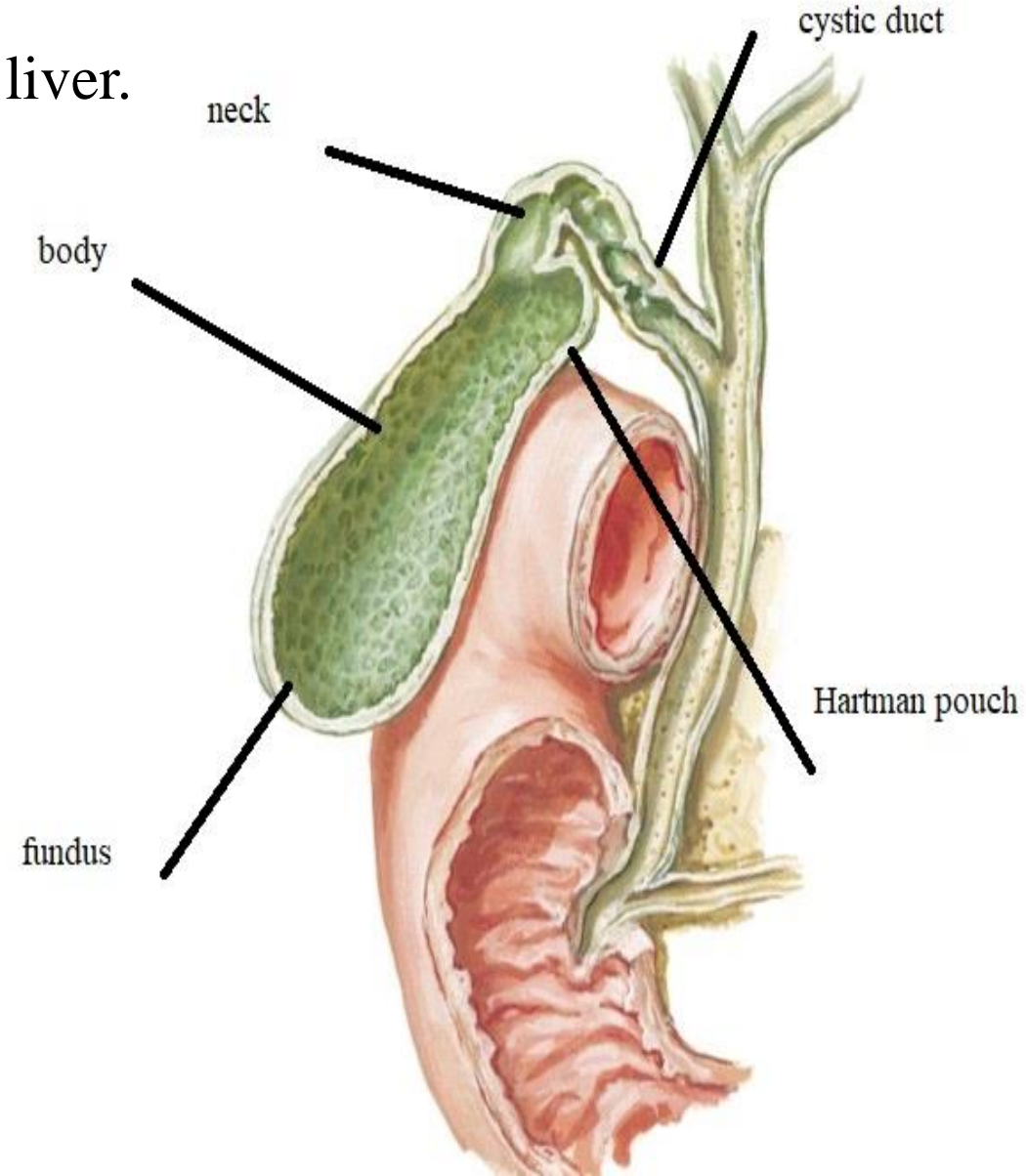
cystic duct:- passes downwards , backwards & left.

Function of gall bladder:-

1- storage & concentration of bile

2-contract in response of CCK

produced by m.m. of duodenum on arrival of fat.



GALL BLADDER

parts & relations:-

fundus:

anterior: ant. abd. wall at tip of 9th c. c.

posterior: transverse colon.

body:

antero-superior:

fossa for gallbladder on inferior surface of liver

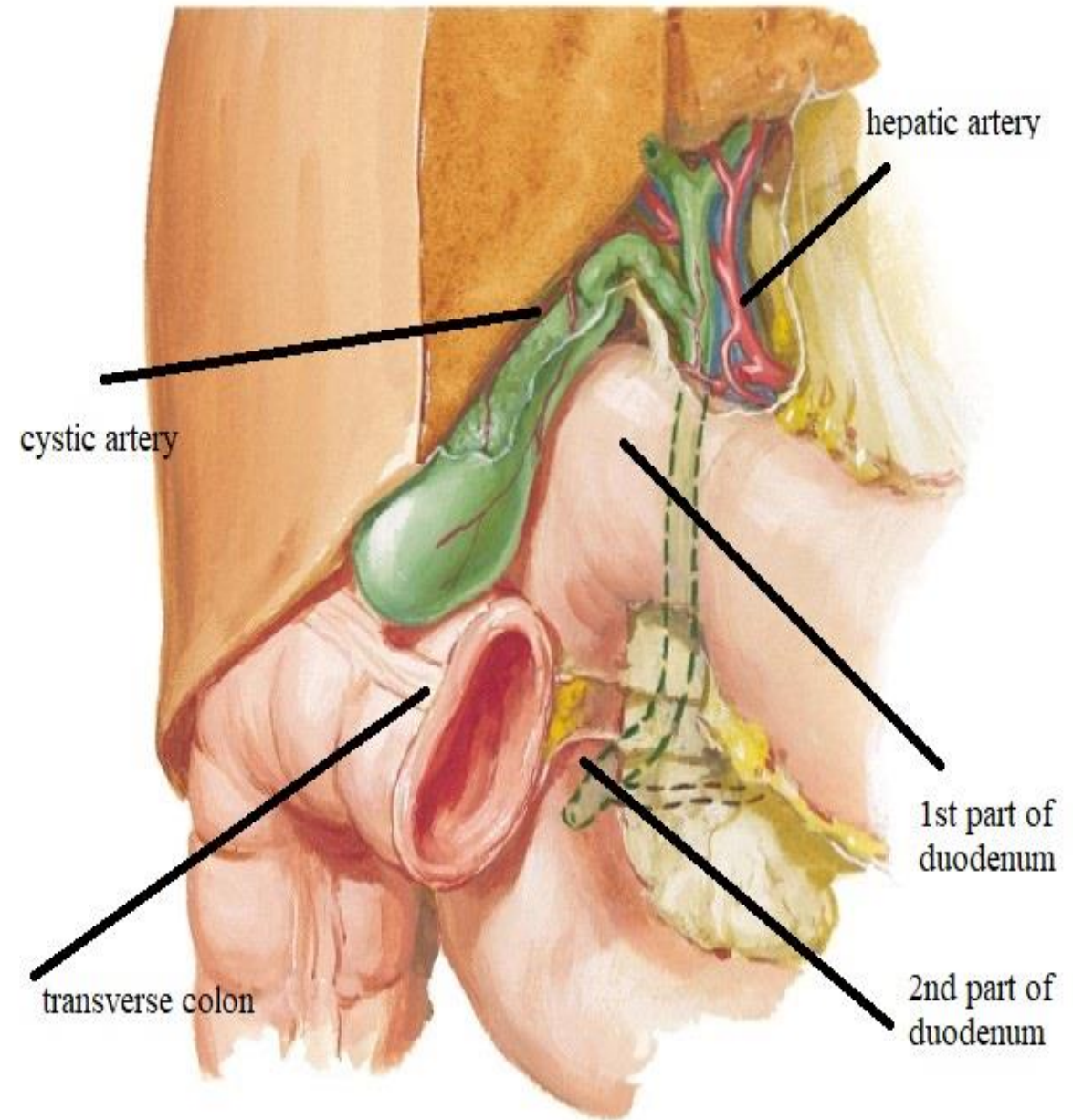
postero-inferior:

transverse colon ,1st.,& 2nd. parts of duodenum .

neck:-

superior: liver& cystic artery in ()

inferior: 1st part of duodenum.



GALL BLADDER

parts & relations:-

cystic duct:

Begins at the neck of gall bladder

End by joining the common hepatic duct to form CBD .

N.B: cystic l.n. lies at this junction,
its enlargement leads to obstructive jaundice.

N.B. mucous membrane of neck & cystic duct
projects in the lumen to form a spiral fold
(Hoister valve) which keep the lumen always patent.

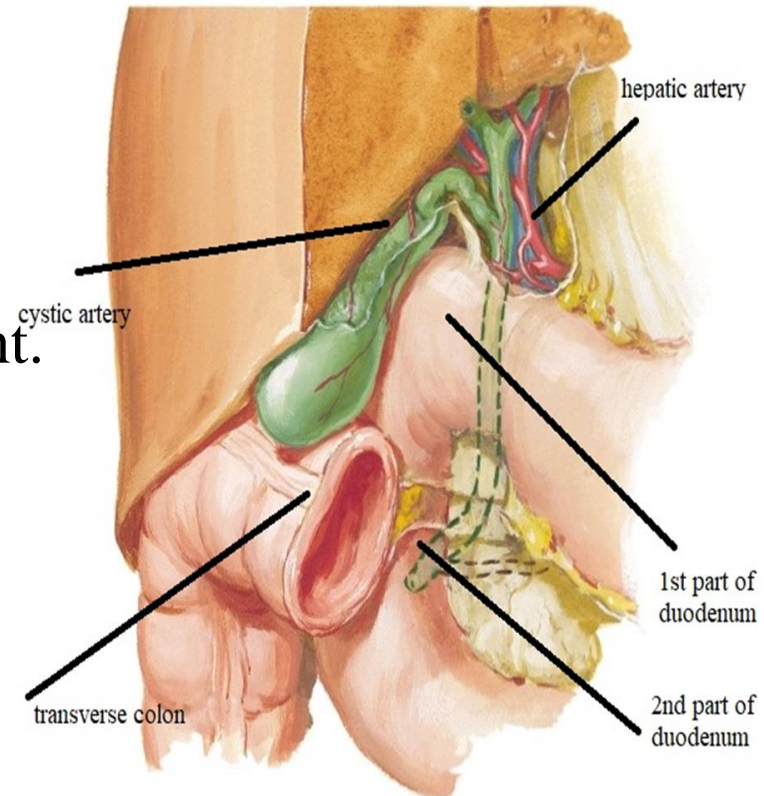
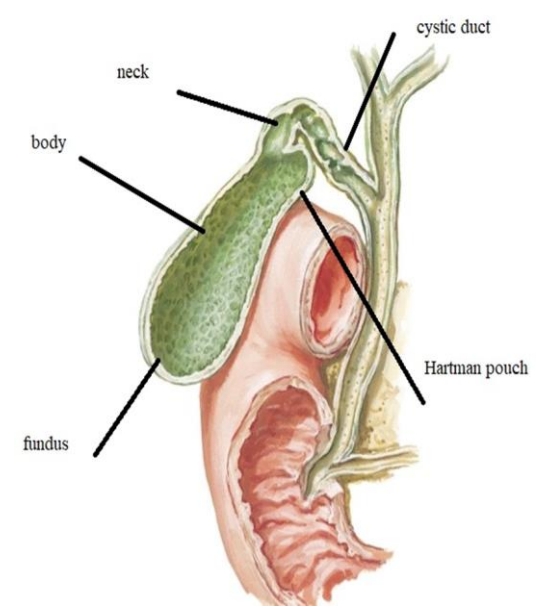
Peritoneal relation:-

Fundus :- completely covered by peritoneum

Body & Neck :- inferior surface only is covered

Cystic duct:- run in free border of lesser omentum.

Surface anatomy of fundus:- tip of rt. 9th. C.c.



GALL BLADDER

A.S.:-

cystic artery

O.:- from Rt branch of hepatic art.,

C. & R. :- run behind CHD & cystic duct to be () neck & liver

E.:- end by dividing into superficial & deep branches

V.D.:-

cystic vein:- that ends in Rt branch of portal v

Small veins from gall bladder pierce liver to join tributaries of hepatic veins.

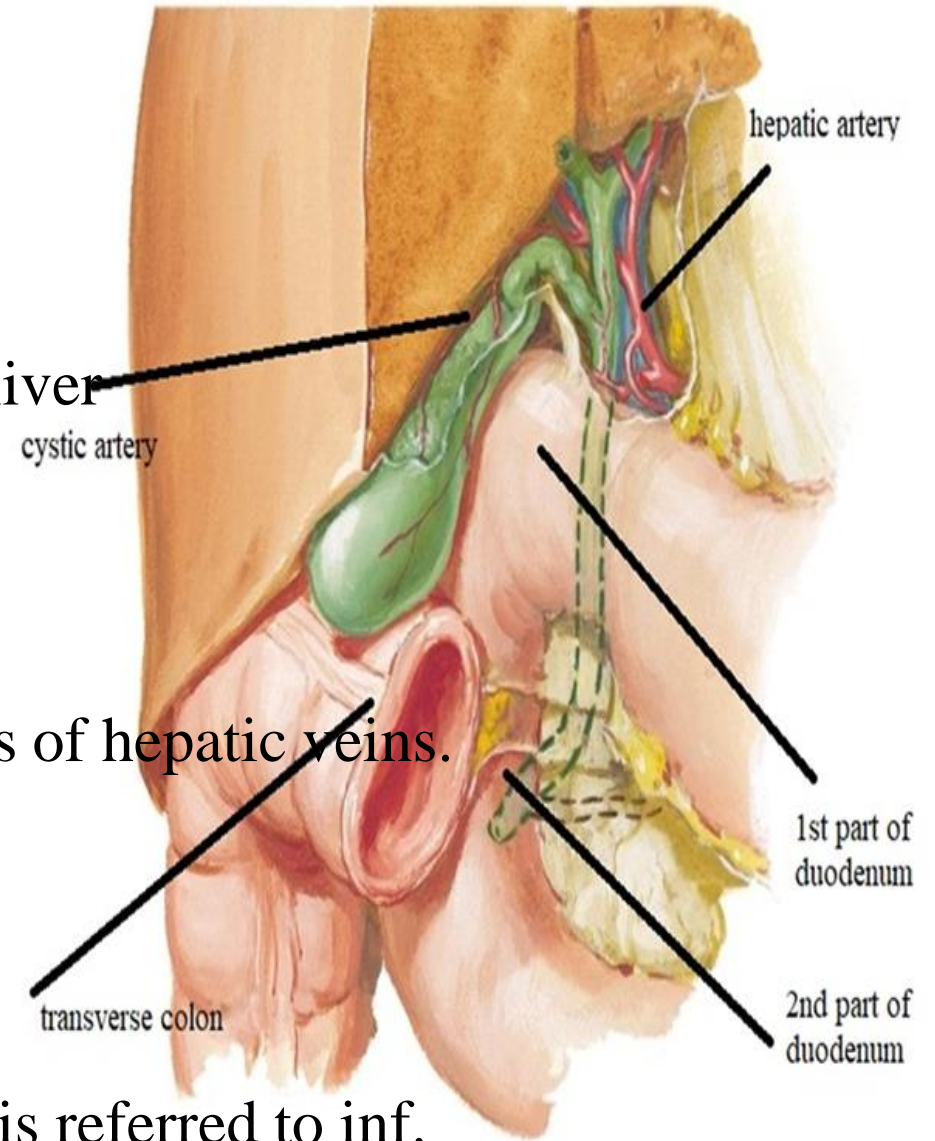
L.D.:- cystic L.N. to hepatic L.N. to coeliac L.N.

N.S.:-

Sensory:- by rt. phrenic n. so pain is referred to rt. shoulder

Sympathetic:- by greater splanchnic nerve (T7-T9) so pain is referred to inf.
angle of scapula

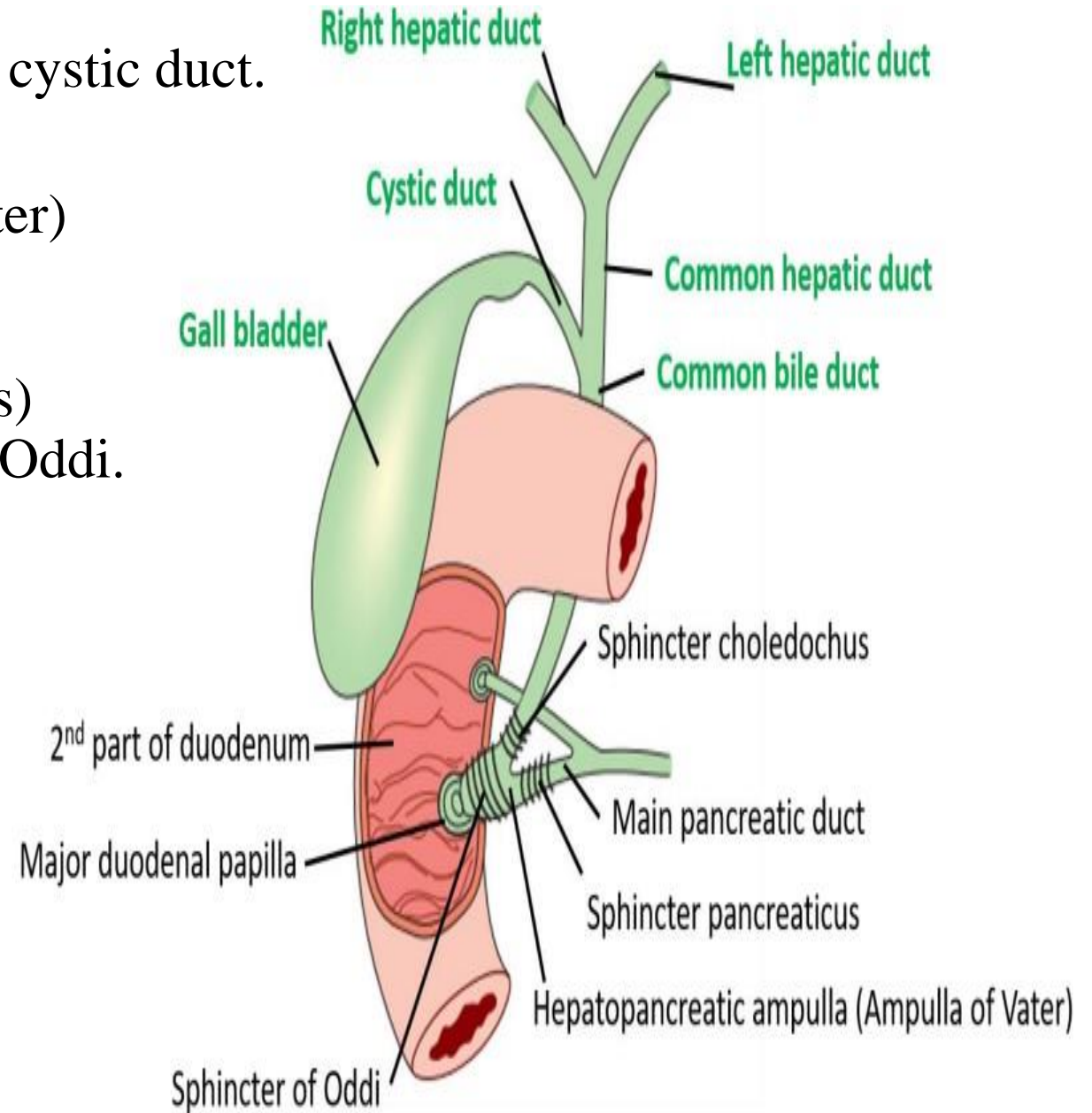
Parasympathetic:- by rt. vagus n. so pain is referred to stomach



COMMON BILE DUCT

Begin: below porta hepatis by union of CHD & cystic duct.

End: the CBD and main pancreatic ducts unite forming hepato pancreatic ampulla (of Vater) to open on major duodenal papilla in the middle of medial wall of 2nd part of duodenum(10 cm from pylorus) this ampulla is surrounded by sphincter of Oddi.



COMMON BILE DUCT

Parts & Course & relations:

supra duodenal part:

in free border of lesser omentum

lt.: - hepatic art.

post.: - portal vein & I.V.C.

retro duodenal part:

ant.: 1st part of duodenum.

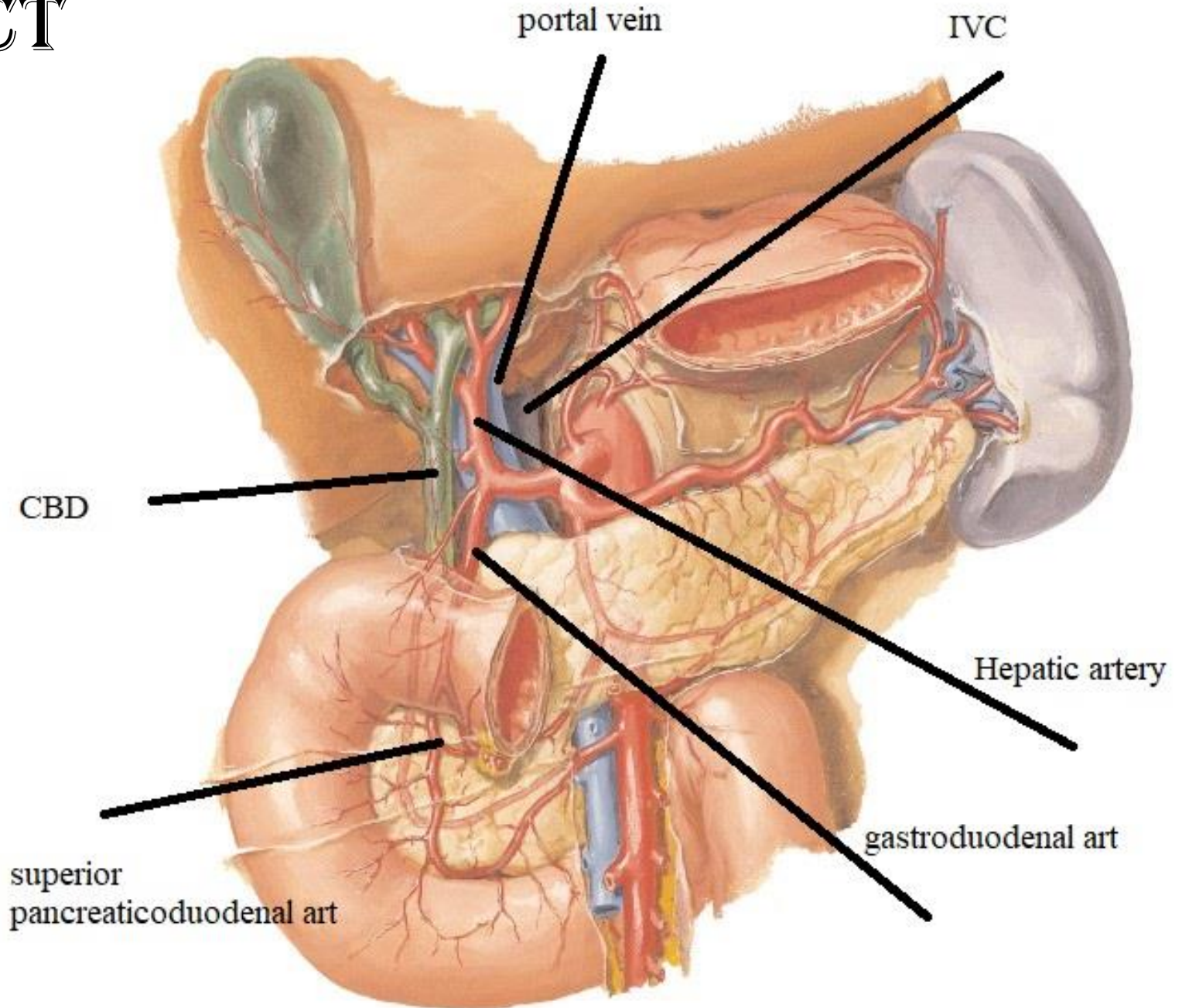
lt.: gastro duodenal art.

post.: portal vein & I.V.C.

Infra duodenal part:

ant.: head of pancreas.

Post.: I.V.C.



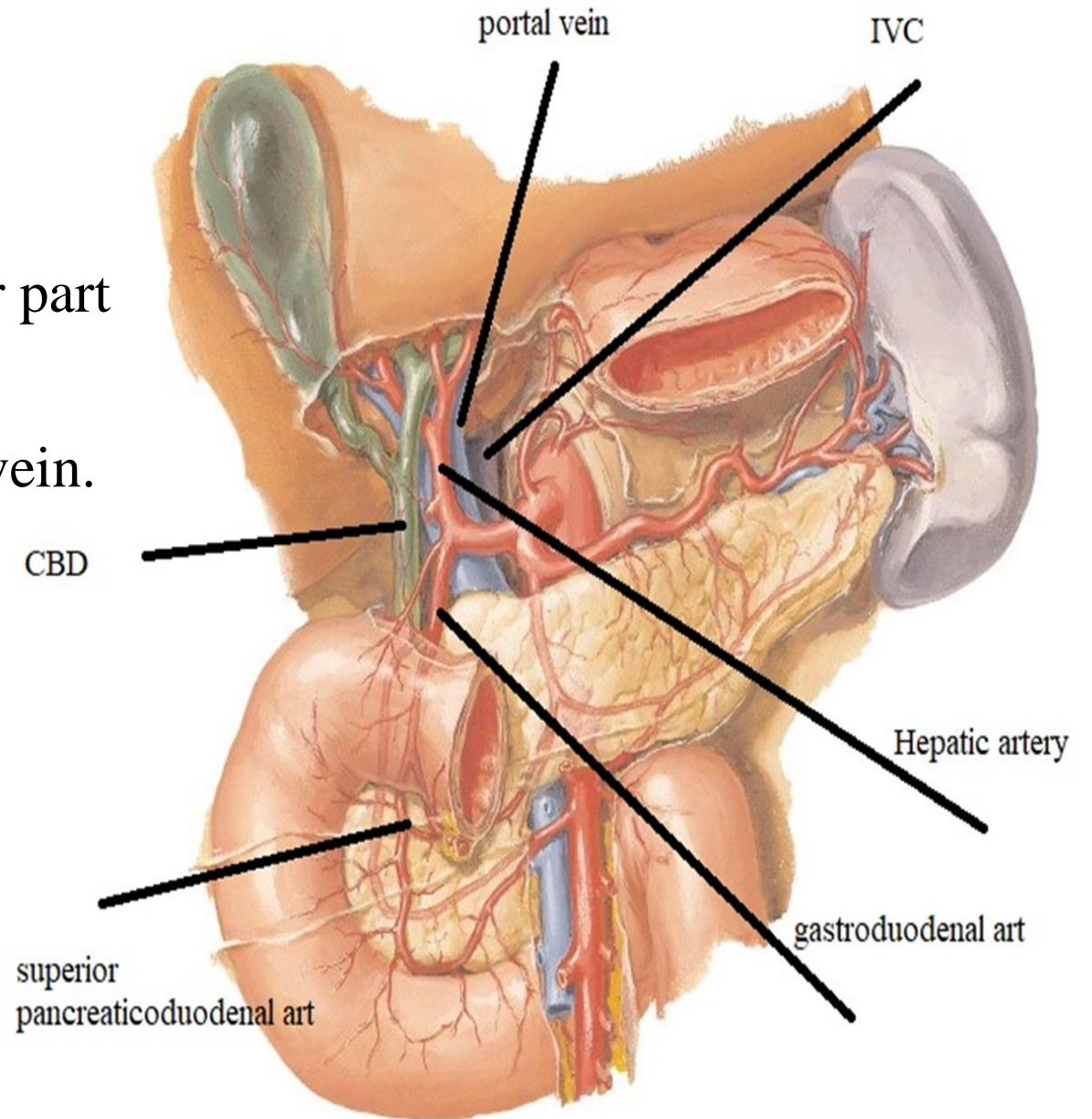
COMMON BILE DUCT

A. S.:

- 1- cystic artery for upper part
- 2- superior pancreatico-duodenal artery for lower part

V.D.:- upper part by veins end directly in liver
lower part by veins end directly in portal vein.

L.D.:- hepatic N. To coeliac L. N.



THANQ