

# **THE VENUOS DRAINAGE OF GIT**

## **Portal Circulation**

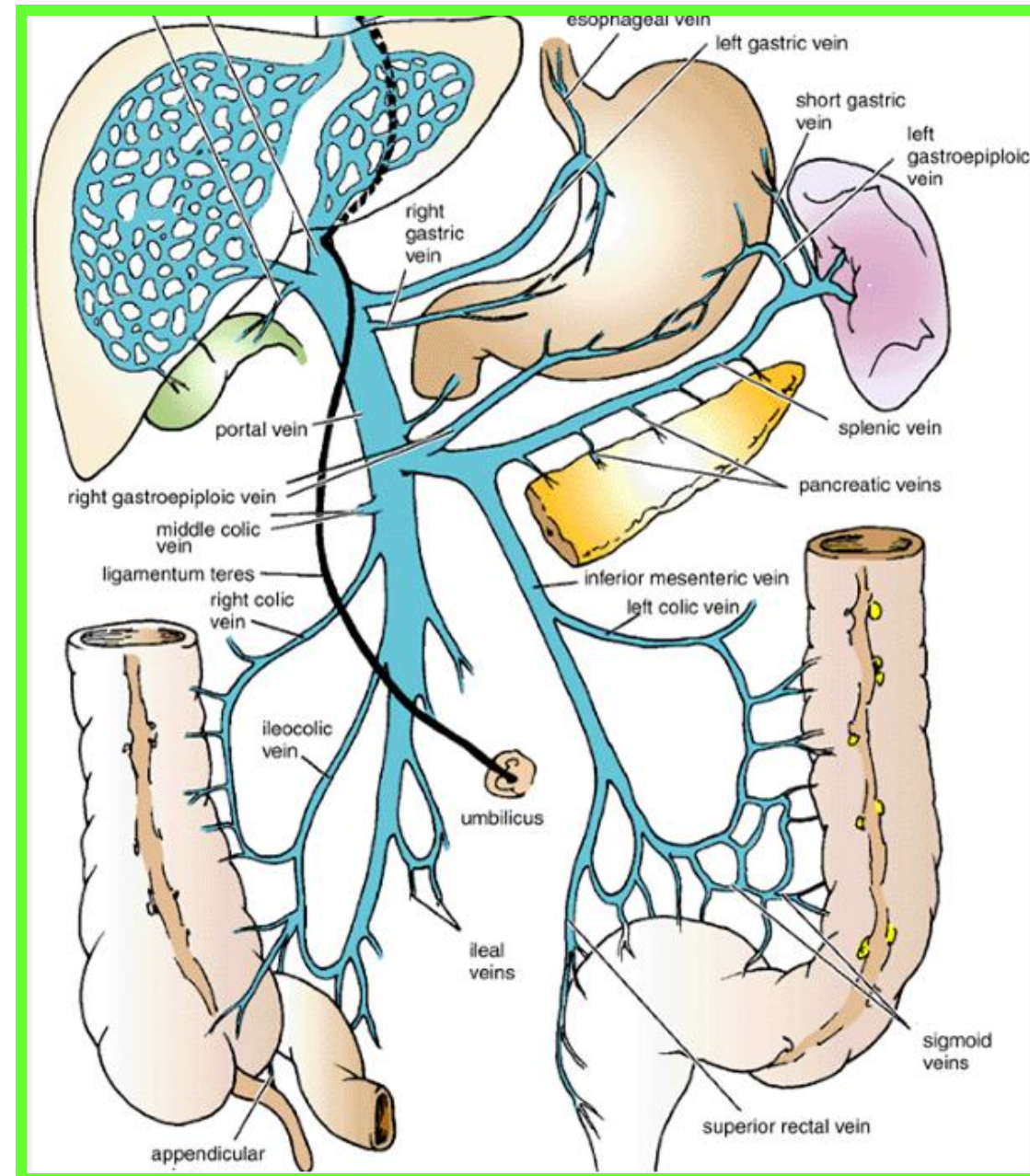
**Dr. Aiman Qais Afar**  
**Surgical Anatomist**

**College of Medicine / University of Mutah**  
**2025-2026**

**Wednesday 22 April 2026**

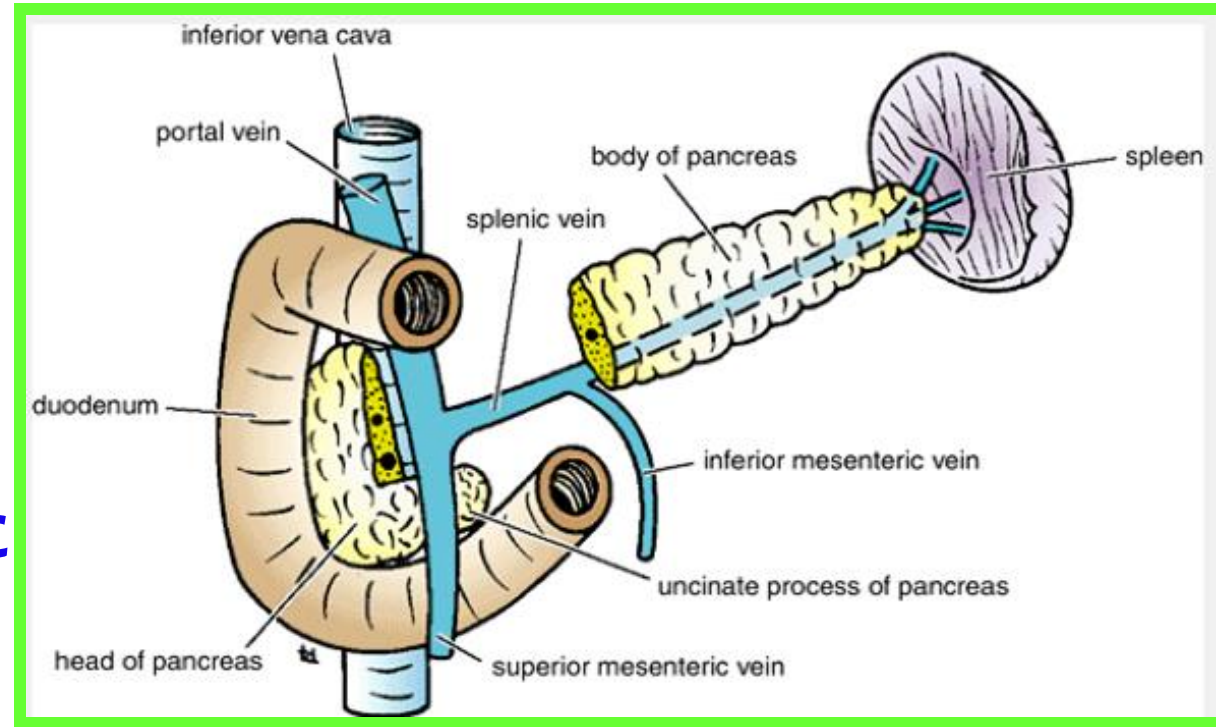
# Portal Vein (Hepatic Portal Vein)

- ❖ The portal vein drains blood from the abdominal part of the gastrointestinal tract **from the lower third of the esophagus to halfway down the anal canal**; it also drains blood from the **spleen, pancreas, and gallbladder**
- ❖ The portal vein enters the liver and breaks up into sinusoids, from which blood passes into **the hepatic veins** that join the **inferior vena cava**



## Portal Vein (Hepatic Portal Vein)

❖ The portal vein is about 2 in. (5 - 8 cm) long and is formed behind the neck of the pancreas by the union of the superior mesenteric and splenic veins.



✓ It ascends to the right, behind the first part of the duodenum, and enters the lesser omentum

✓ The portal vein and its tributaries have no valves.

# Portal Vein (Hepatic Portal Vein)

Dr. Aiman Al Maathidy  
Wednesday 22 April 2026

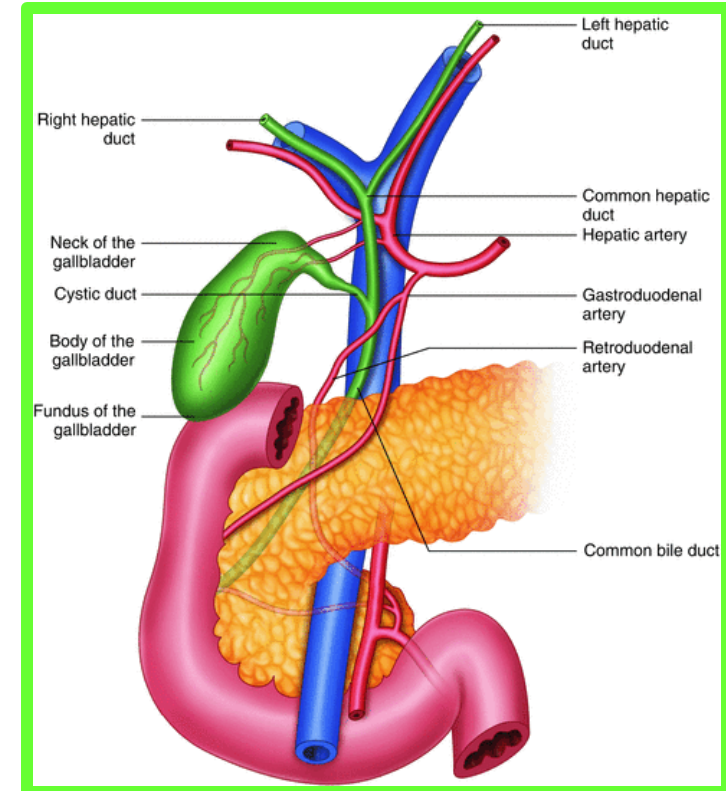
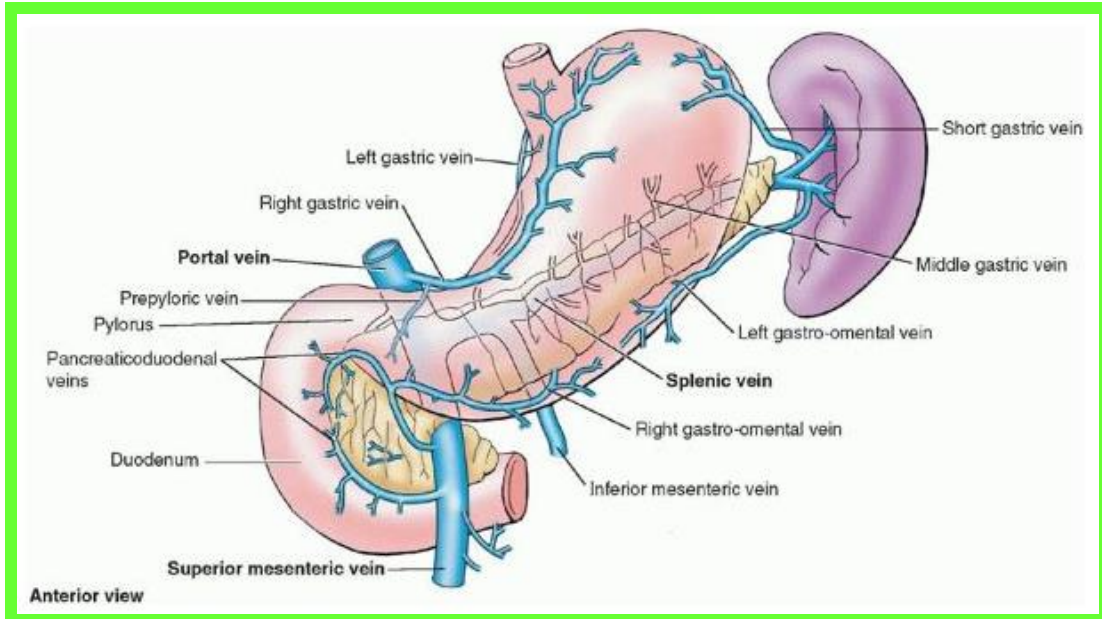
4

## A. The retro-duodenal

### a. Anteriorly;

- 1) **Bile duct** (anterior and to the right).
- 2) **Gastroduodenal artery** (anterior and to the left).
- 3) **First part of the duodenum**

### b. Posteriorly, inferior vena cava



# Portal Vein (Hepatic Portal Vein)

5

Dr. Aiman Al Maathidy  
Wednesday 22 April 2026

B. The supra-duodenal, It ascends in the **right free margin of the lesser omentum.**

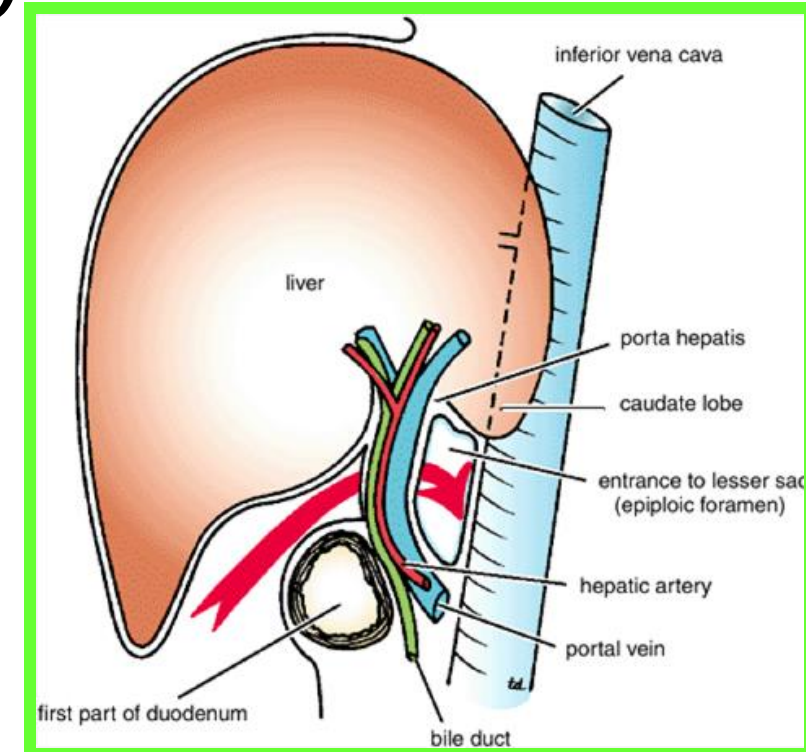
a. Anteriorly;

1) **Bile duct** (anterior and to the right).

2) **Hepatic artery** (anterior and to the left).

b. Posteriorly, **inferior vena cava** and epiploic foramen.

✓ It then runs upward in front of the opening into the lesser sac to **the porta hepatis**, where it divides into **right** and **left** terminal branches



# Portal Vein (Hepatic Portal Vein)

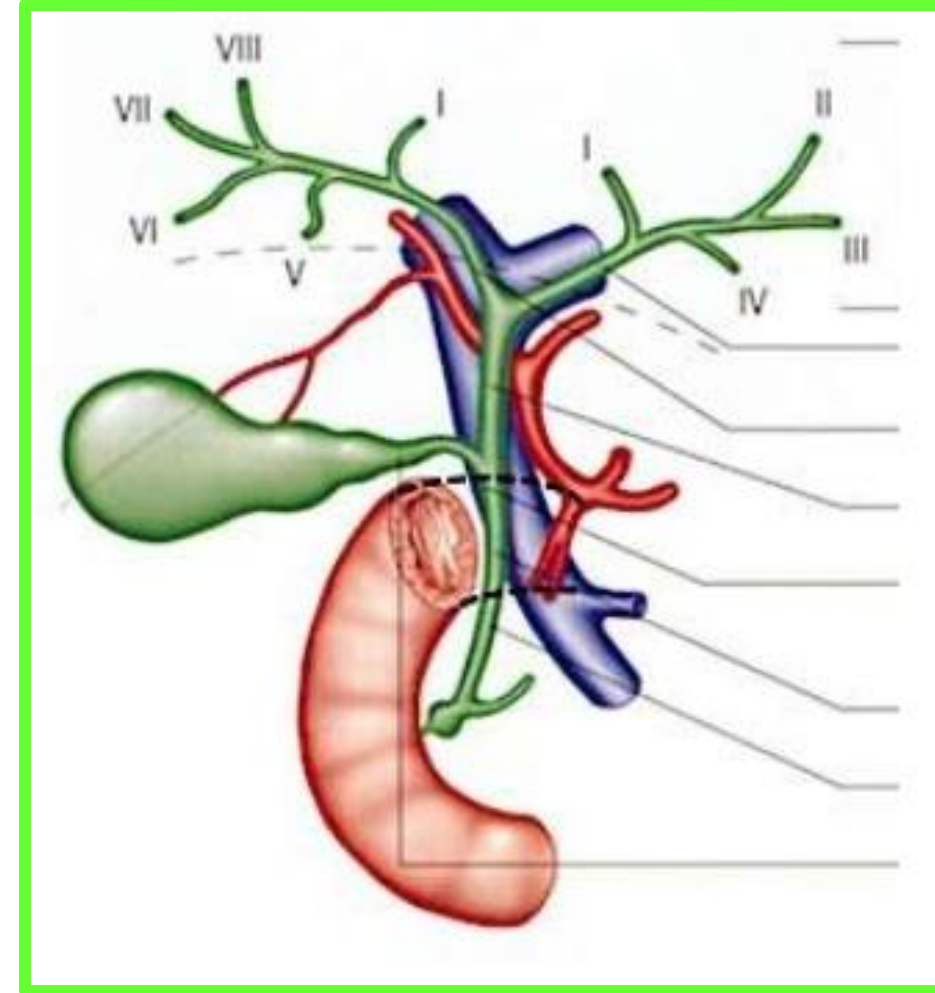
**C. Termination**, at the porta hepatis of the liver.

❖ It divides into **right** and **left branches** to the corresponding lobes of the liver.

a. Anteriorly,

- 1) **Right and left hepatic ducts** (most anterior).
- 2) **Right and left branches of hepatic artery** (in the middle).

b. Posteriorly, **inferior vena cava** and **caudate process**

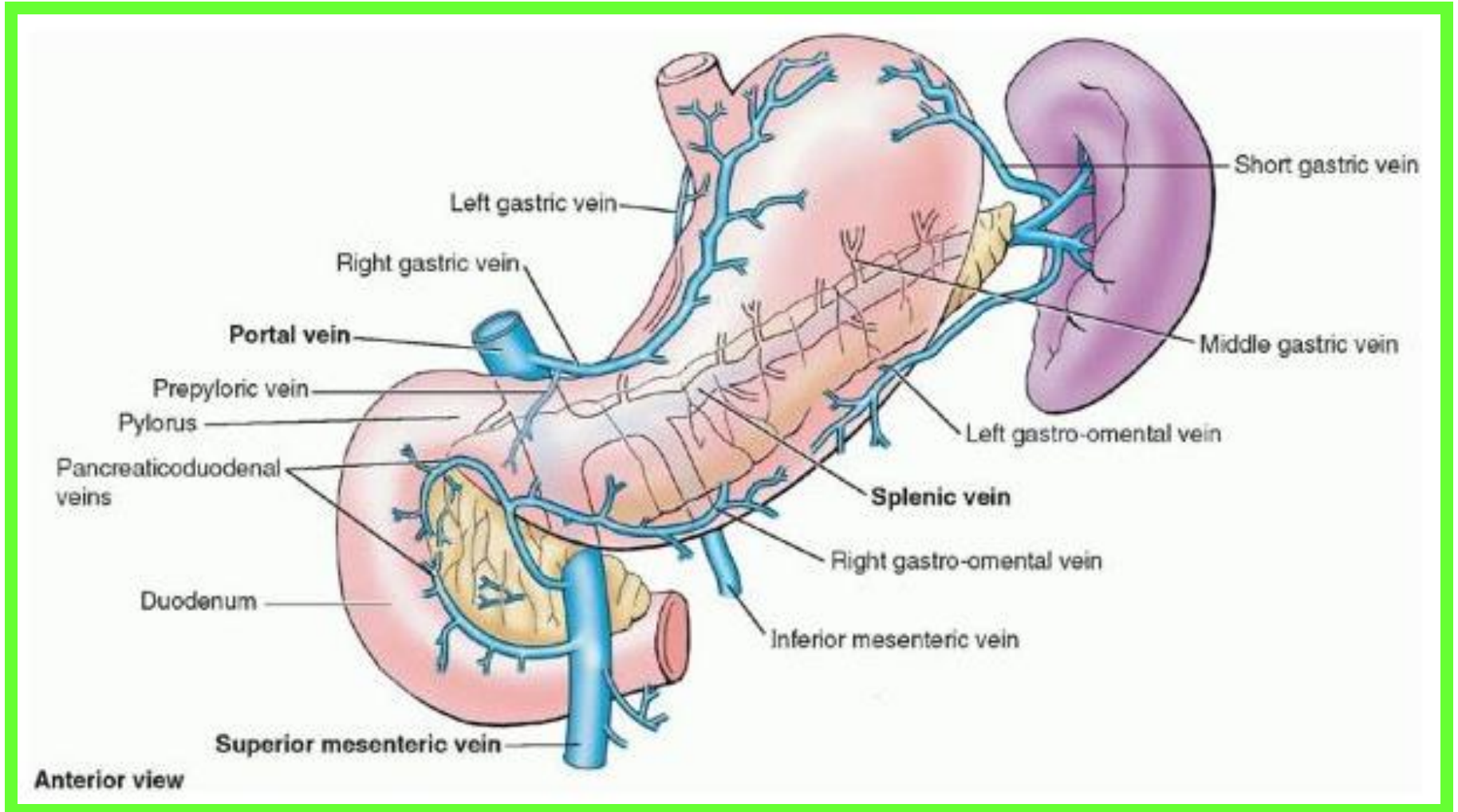


Dr. Aiman Al Maathidy

Wednesday 22 April 2026

# Portal Vein (Hepatic Portal Vein)

## Tributaries of the Portal Vein



# Portal Vein (Hepatic Portal Vein)

Dr. Aiman Al Maathidy  
Wednesday 22 April 2026

8

## Tributaries

A. 2 veins join each other to form the portal vein.

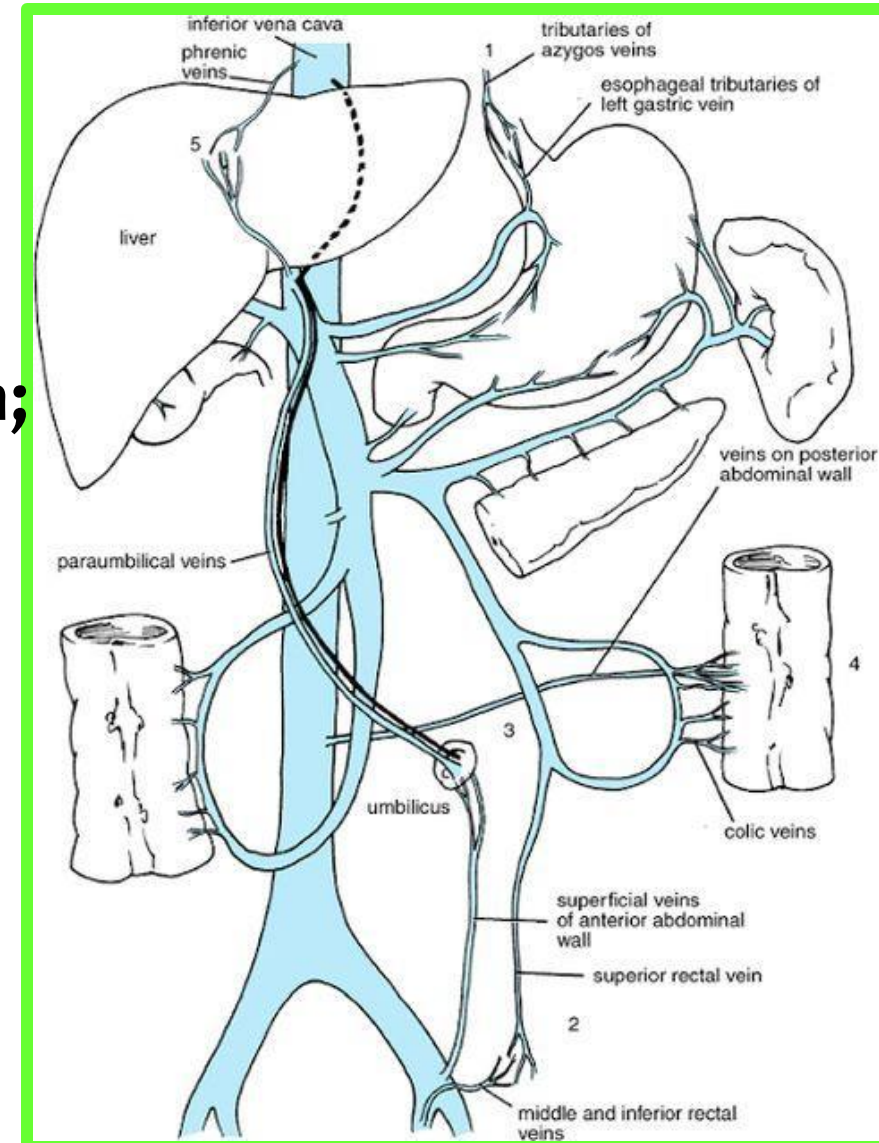
1. Superior mesenteric vein.
2. Splenic vein.

B. 2 veins from the lesser curvature of the stomach;

3. Right gastric vein.
4. Left gastric vein.

C. 2 veins end into the terminal branches;

5. Paraumbilical vein to the left terminal branch.
6. Cystic vein to the right terminal branch.

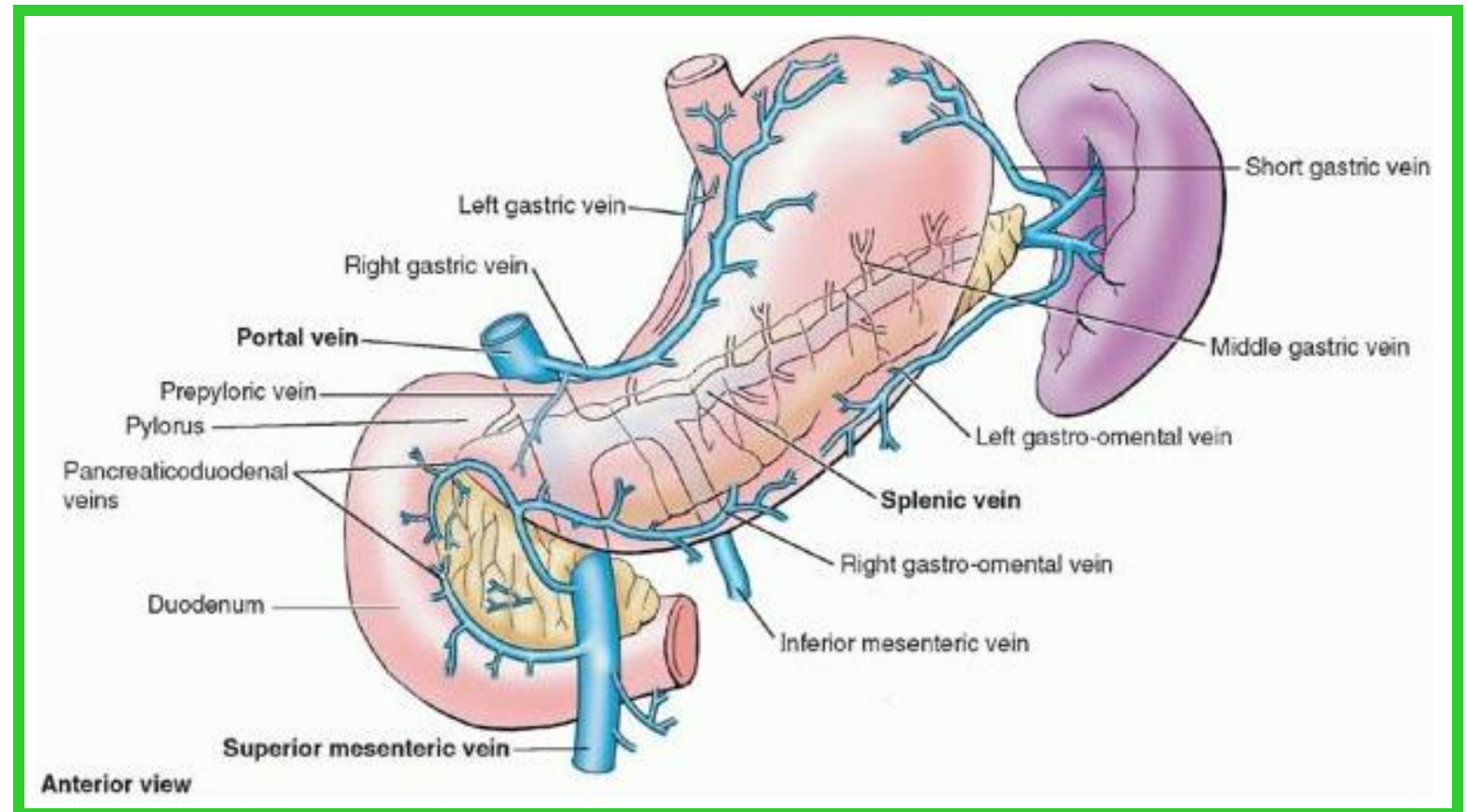


# Tributaries of the Portal Vein

❖ **Splenic vein:** This vein leaves the hilum of the spleen and passes to the right in **the splenicorenal ligament**. It unites with **the superior mesenteric vein** behind the neck of the pancreas to form **the portal vein**.

It receives the :

- ✓ Short gastric,
- ✓ left gastroepiploic,
- ✓ inferior mesenteric,
- ✓ pancreatic veins

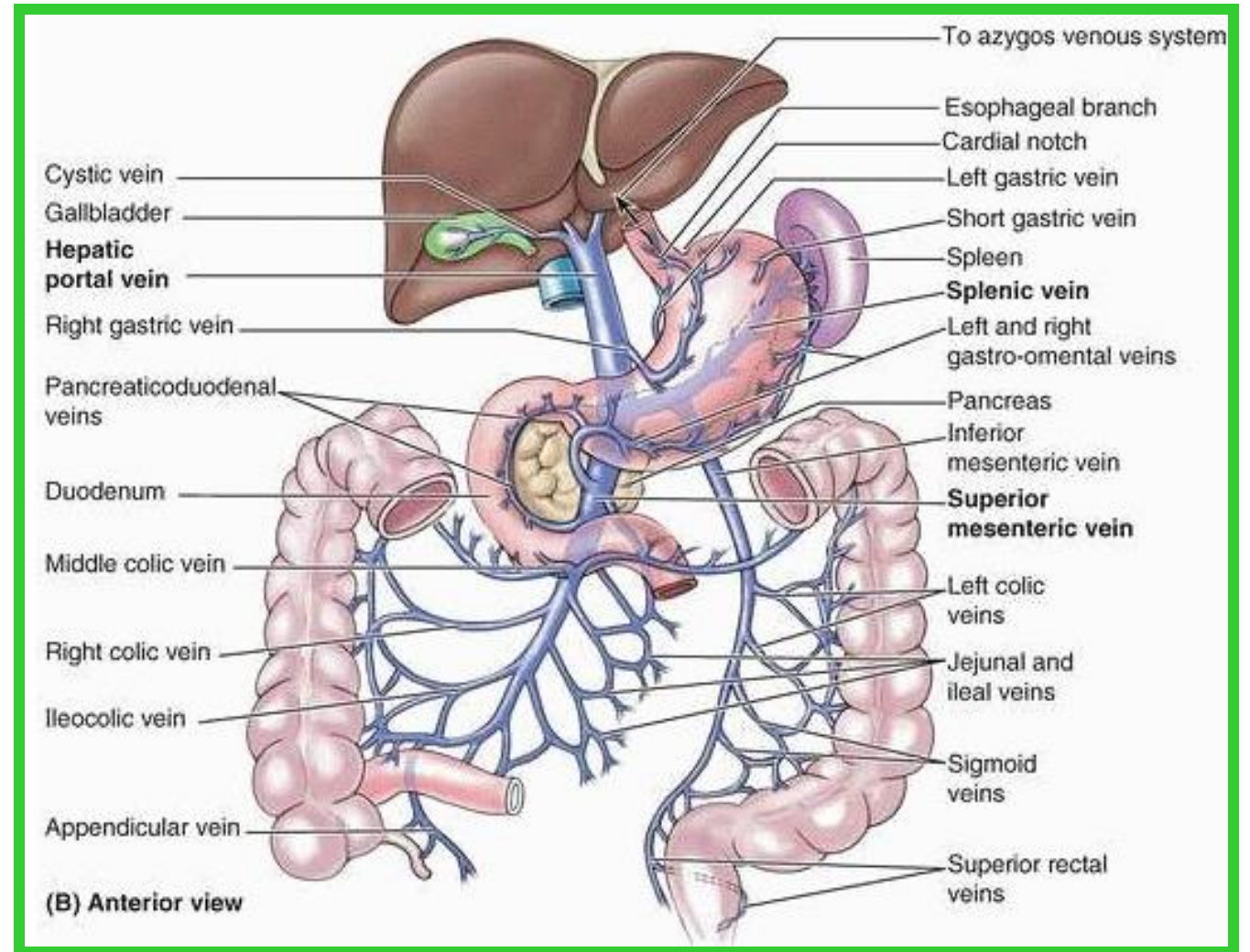


# Tributaries of the Portal Vein

❖ **Inferior mesenteric vein:** This vein ascends on the posterior abdominal wall and joins **the splenic vein** behind the **body of the pancreas**

It receives:

- ✓ **the superior rectal veins,**
- ✓ **the sigmoid veins, and**
- ✓ **the left colic vein**



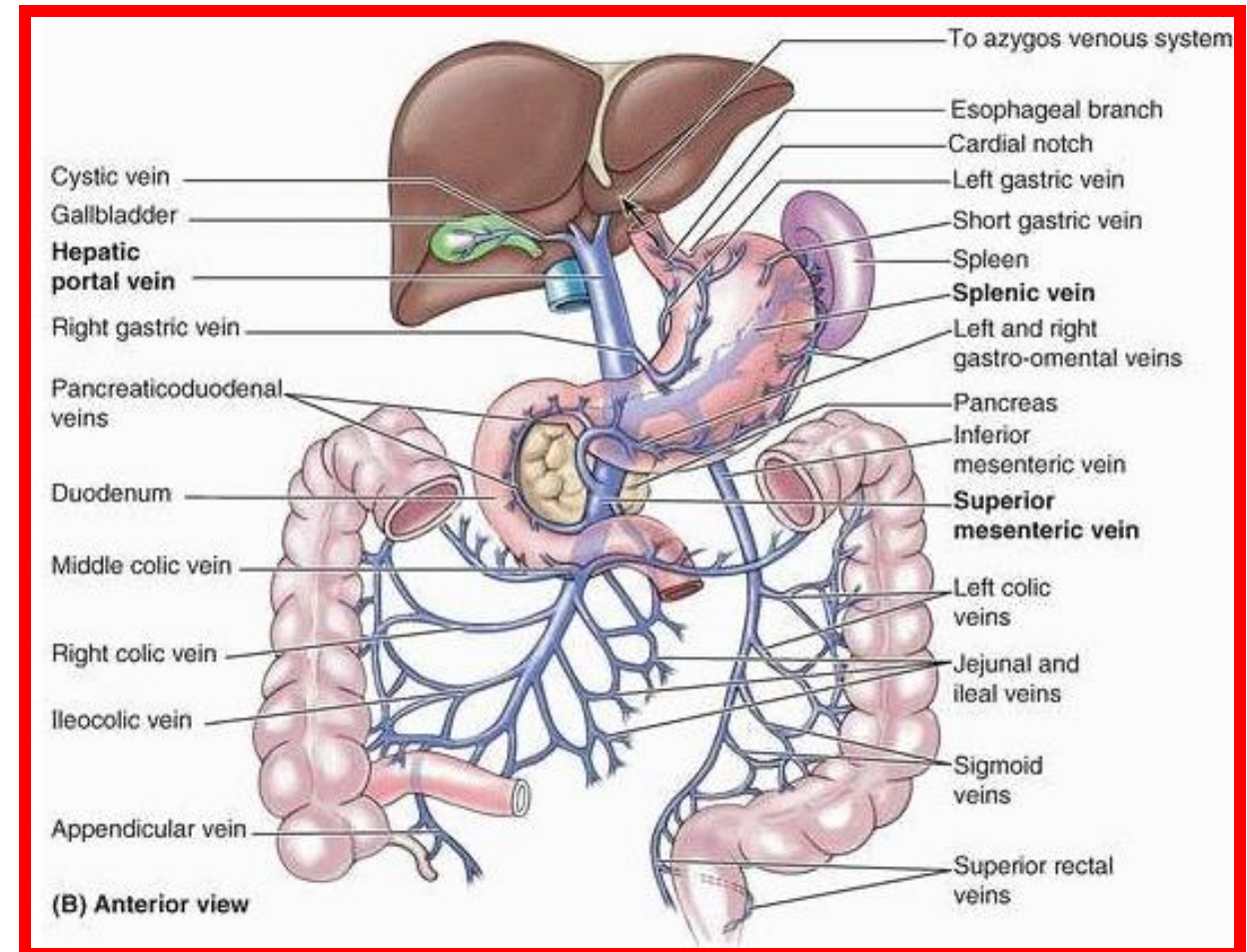
# Tributaries of the Portal Vein

Dr. Aiman Al Maathidy

❖ **Superior mesenteric vein:** This vein ascends in **the root of the mesentery of the small intestine**. It passes **in front of the third part of the duodenum** and joins the splenic vein behind the neck of the pancreas .

It receives :

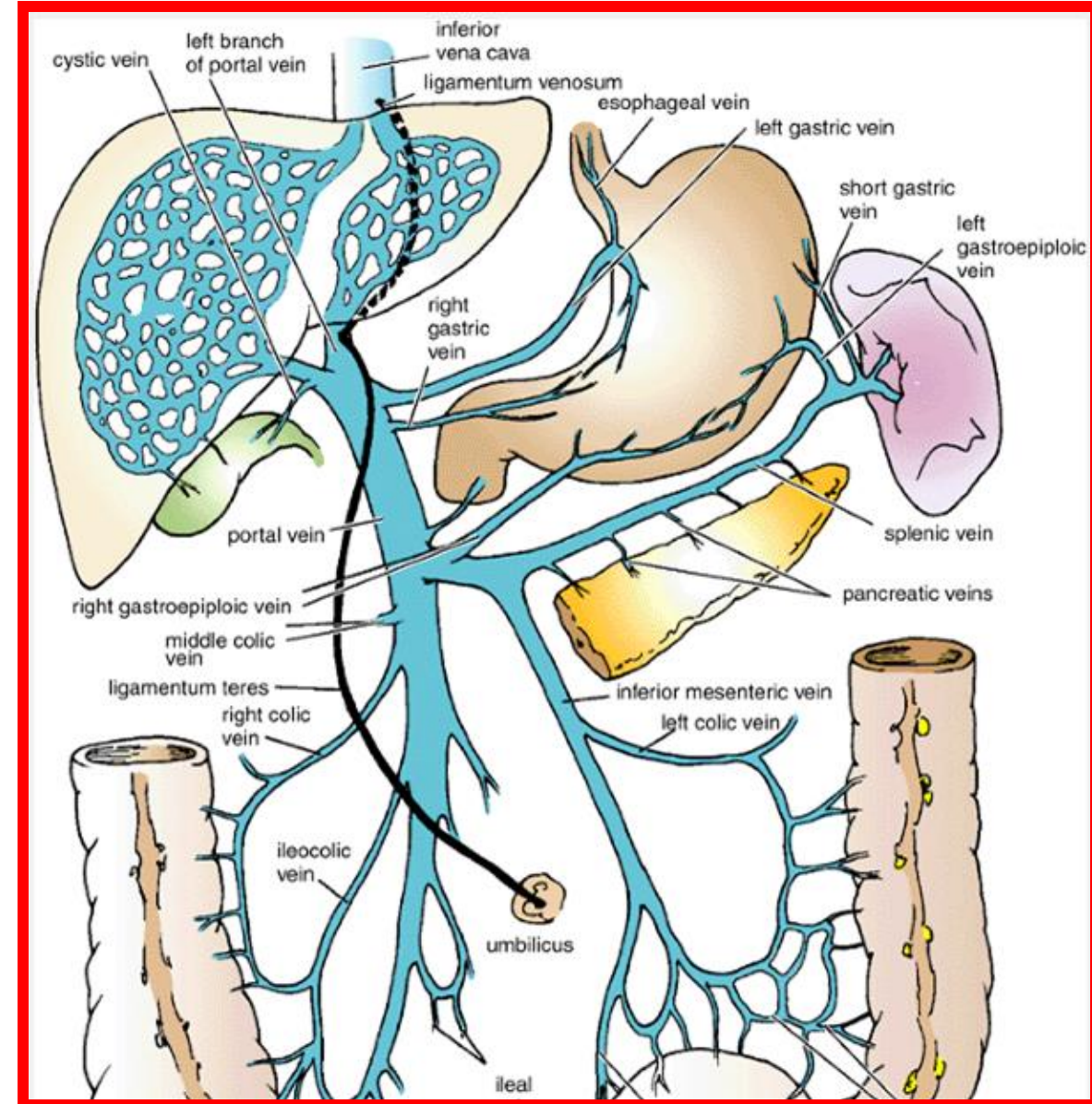
- ✓ The jejunal,
- ✓ The ileal,
- ✓ The ileocolic,
- ✓ The right colic,
- ✓ The middle colic,
- ✓ The inferior pancreaticoduodenal,
- ✓ The right gastroepiploic veins



# Tributaries of the Portal Vein

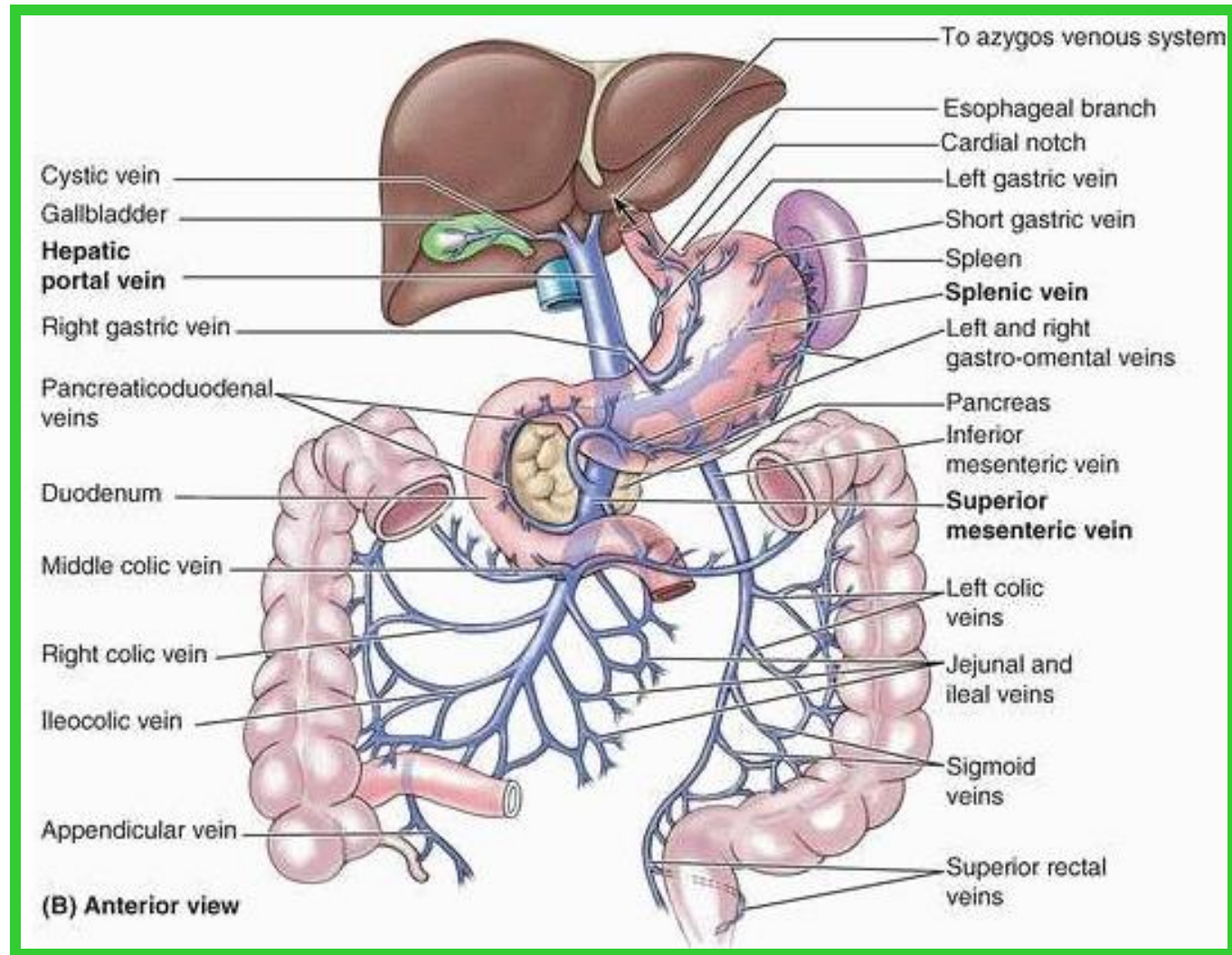
❖ **Left gastric vein:** This vein drains the left portion of the lesser curvature of the stomach and the distal part of the esophagus. It **opens directly** into the **portal vein**

❖ **Right gastric vein:** This vein drains the right portion of the lesser curvature of the stomach and **drains directly** into the **portal vein**



# Tributaries of the Portal Vein

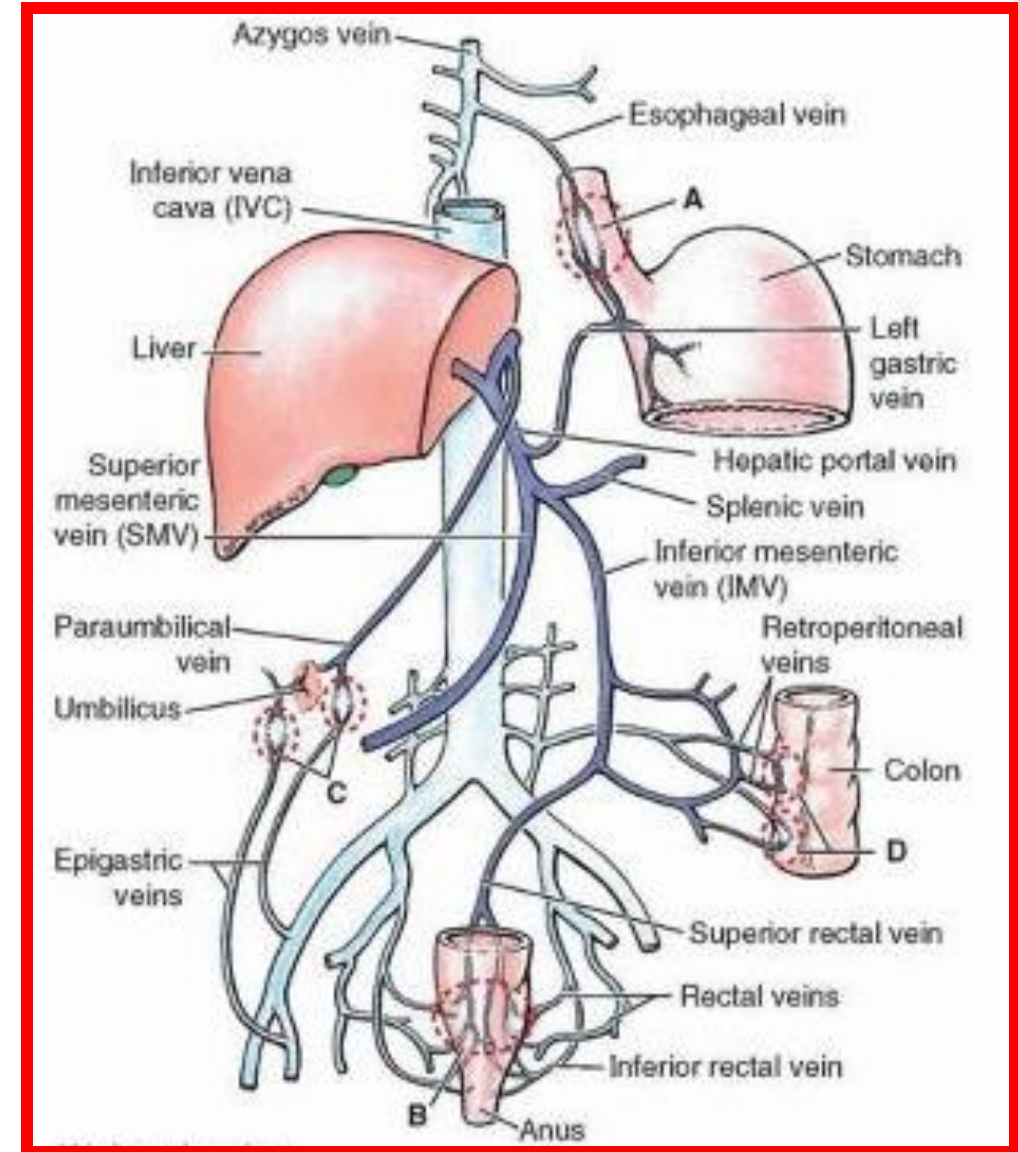
**Cystic veins:** These veins either drain the gallbladder directly into the liver or join the portal vein



# HEPATIC PORTAL VEIN AND PORTAL-SYSTEMIC ANASTOMOSES

**Portal-systemic anastomoses** in which the **portal venous system** communicates with the **systemic venous system**, are formed in the submucosa of :

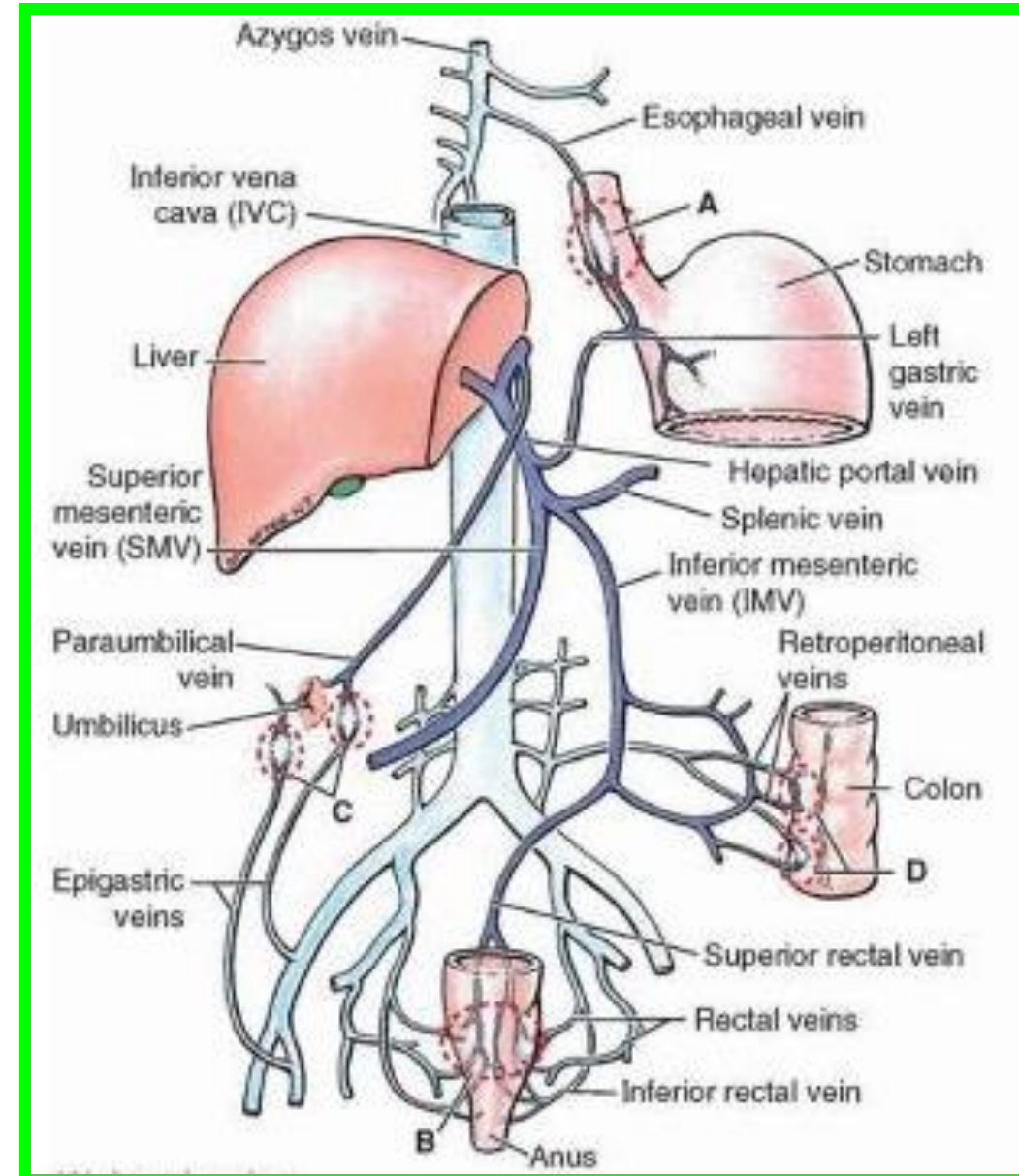
- ✓ The inferior esophagus,
- ✓ The submucosa of the anal canal
- ✓ The paraumbilical region,
- ✓ The posterior aspects (bare areas)
- ✓ At the posterior abdominal wall



# HEPATIC PORTAL VEIN AND PORTAL-SYSTEMIC ANASTOMOSES

❖ At the lower third of the esophagus, the esophageal branches of the **left gastric vein (portal tributary)** anastomose with the **esophageal veins** draining the middle third of the esophagus into **the azygos veins (systemic tributary)**.

❑ **Enlargement of these anastomoses** result to **oesophageal varices** leading to **hematemesis (vomiting of blood)**.



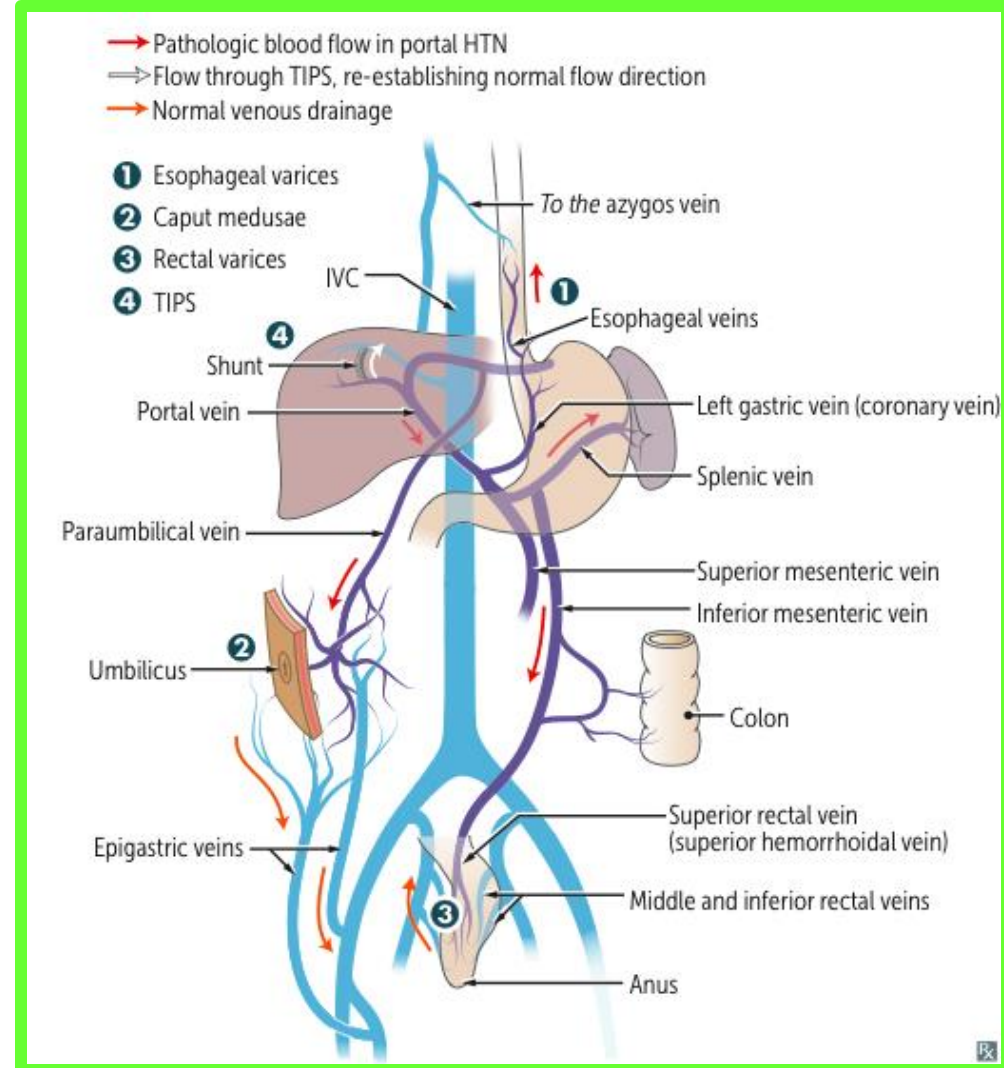
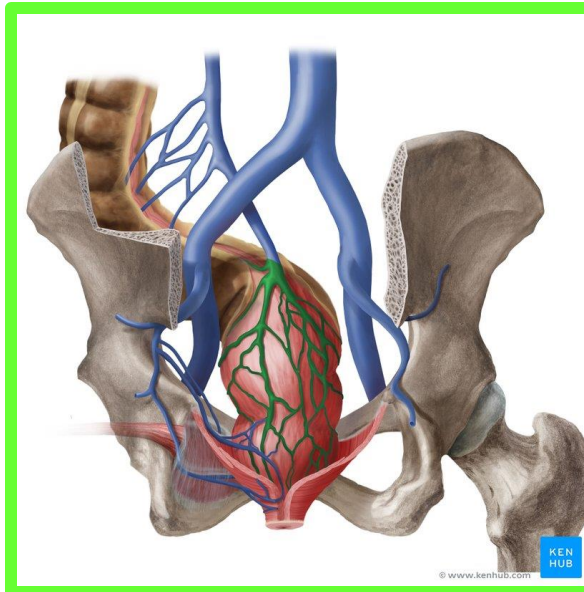
# HEPATIC PORTAL VEIN AND PORTAL-SYSTEMIC ANASTOMOSES

❖ Halfway down the anal canal, the **superior rectal veins (portal tributary)** anastomose with the **middle and inferior rectal veins (systemic tributaries)**

❑ Enlargement of these anastomoses leads to formation of piles.

Dr. Aiman Al-Maathidy  
Wednesday 22 April 2026

16

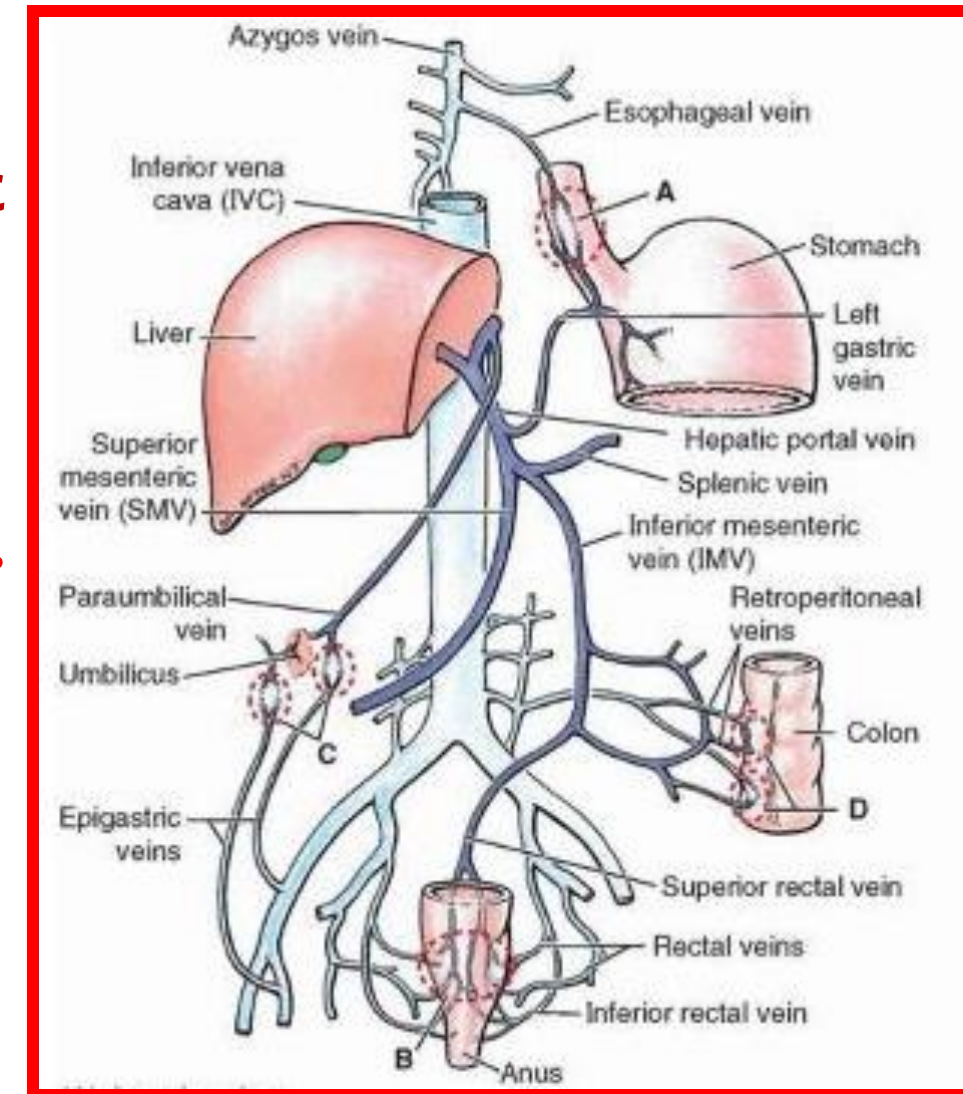


# HEPATIC PORTAL VEIN AND PORTAL- SYSTEMIC ANASTOMOSES

❖ The paraumbilical veins connect the left branch of **the portal vein** with **the superficial veins of the anterior abdominal wall (systemic tributaries)**.

(The paraumbilical veins travel in the falciform ligament and accompany the ligamentum teres).

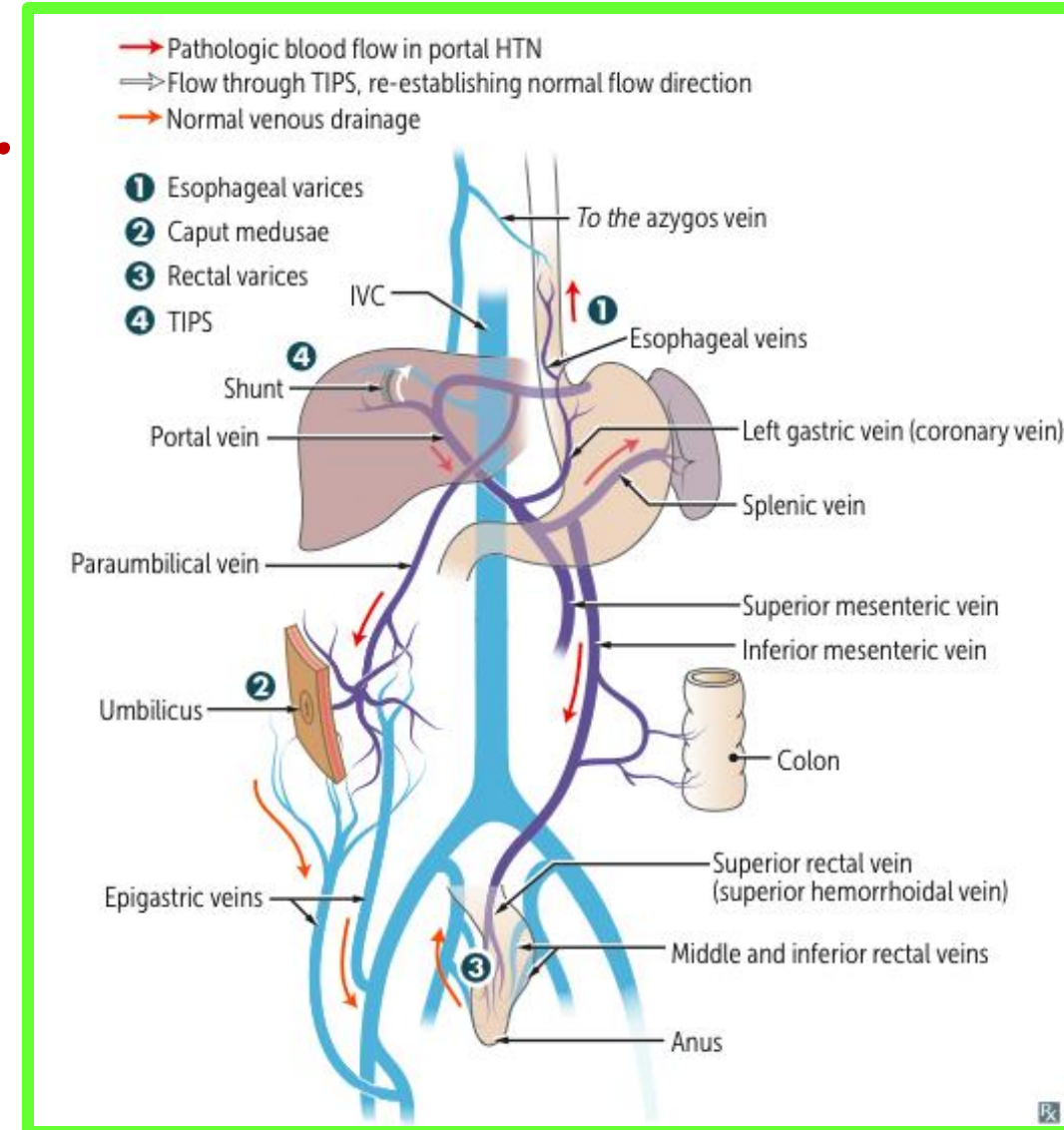
❑ **Enlargement of these anastomoses produces caput medusa (dilated veins radiating around the umbilicus).**



# HEPATIC PORTAL VEIN AND PORTAL-SYSTEMIC ANASTOMOSES

- ❖ **At the posterior abdominal wall, between**
  - Veins of the colon and duodenum (portal).**
  - Veins of the posterior abdominal wall and left renal vein (systemic).**

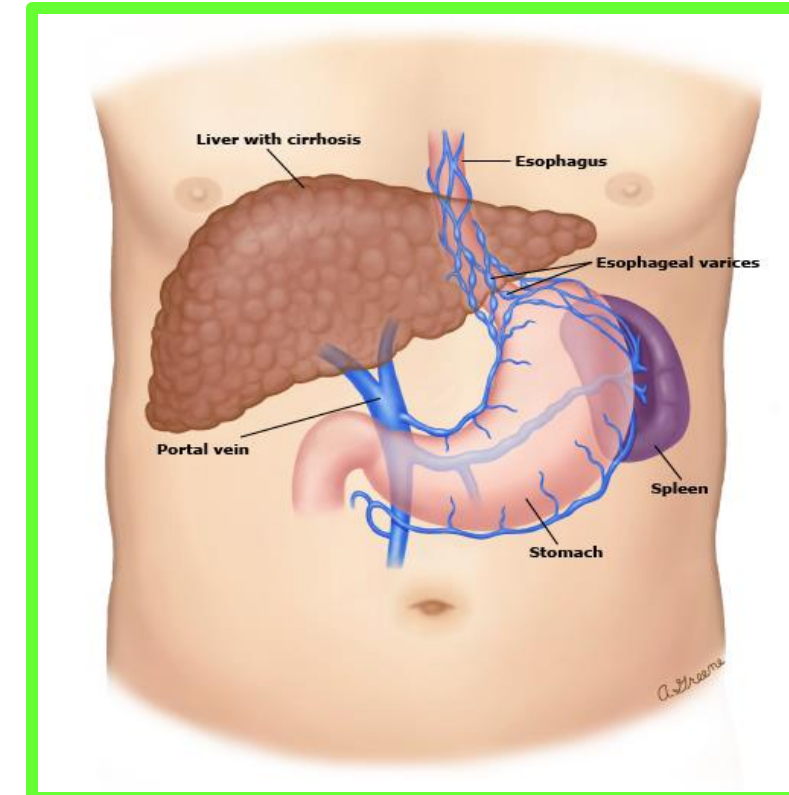
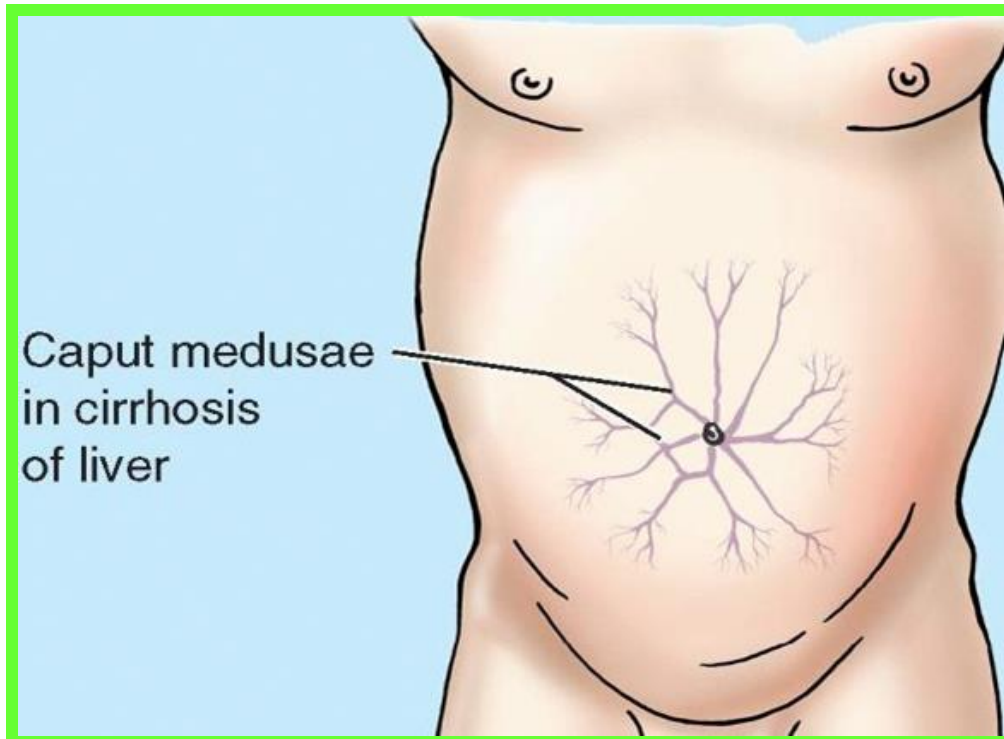
- ❖ **At the bare area of the liver, Between**
  - Veins of the liver (portal).**
  - Inferior phrenic veins of the diaphragm (systemic).**



# Portal Hypertension

Dr. Aiman Al Maathidy

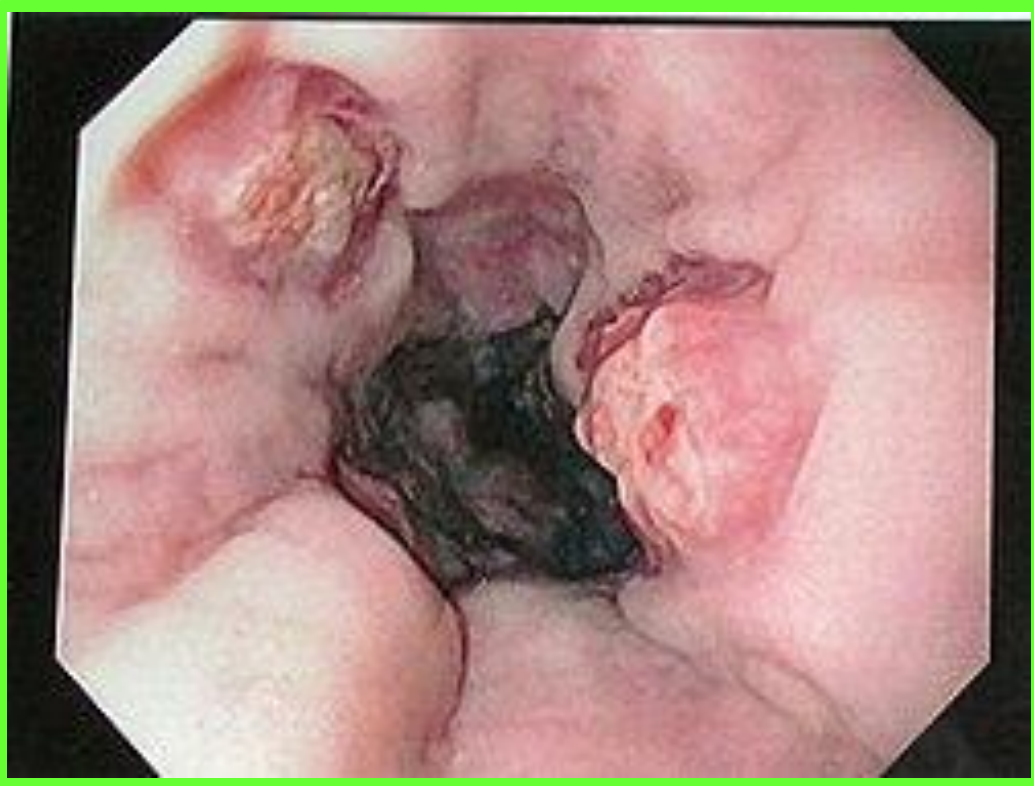When **scarring and fibrosis from cirrhosis of the liver** obstruct the **hepatic portal vein**, pressure rises in the hepatic portal vein and its tributaries, producing **portal hypertension**. At the sites of anastomoses between portal and systemic veins, portal hypertension produces **enlarged varicose veins** and blood flow from the portal to the systemic system of veins



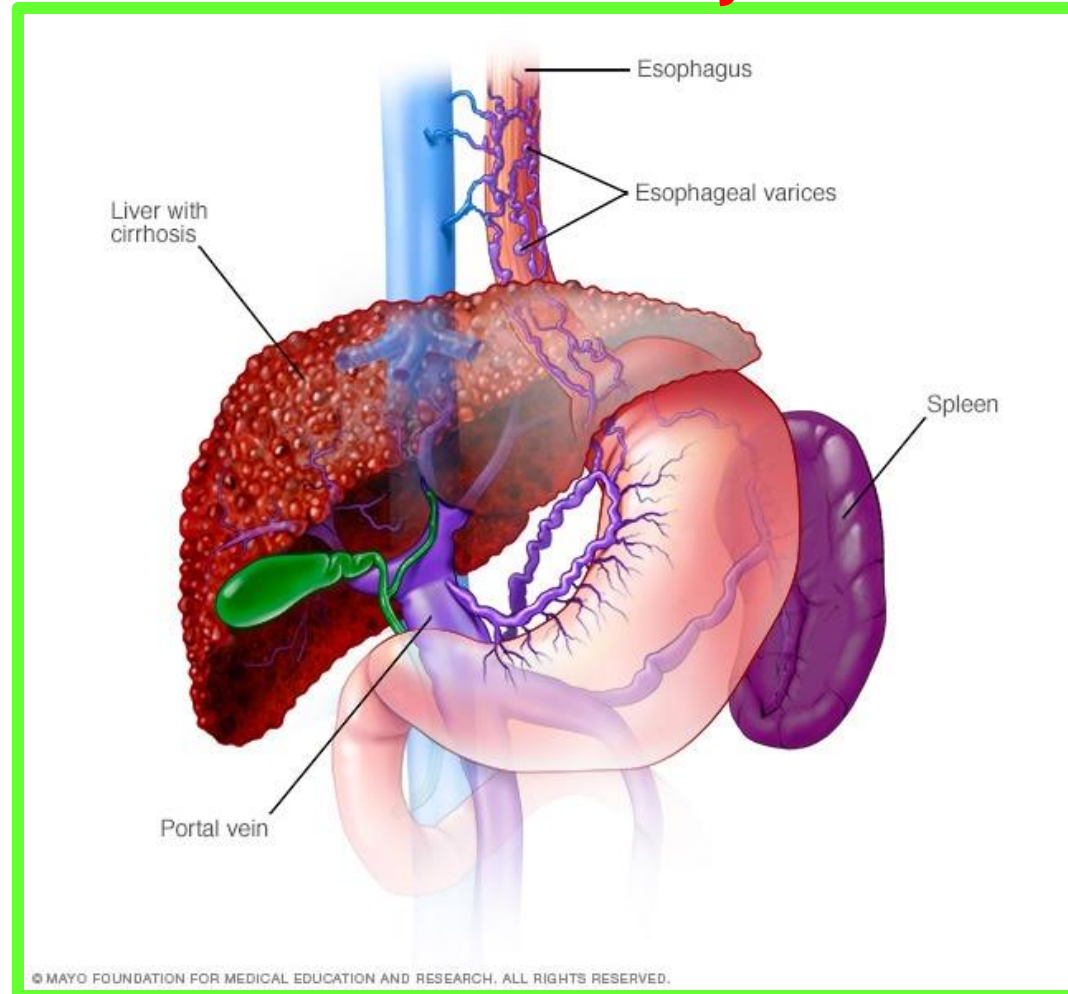
Wednesday 22 April 2026

# Portal Hypertension

The veins may become so dilated that their walls rupture, resulting in hemorrhage. Bleeding from esophageal varices (dilated esophageal veins) at the distal end of the esophagus is often **severe and may be fatal**.

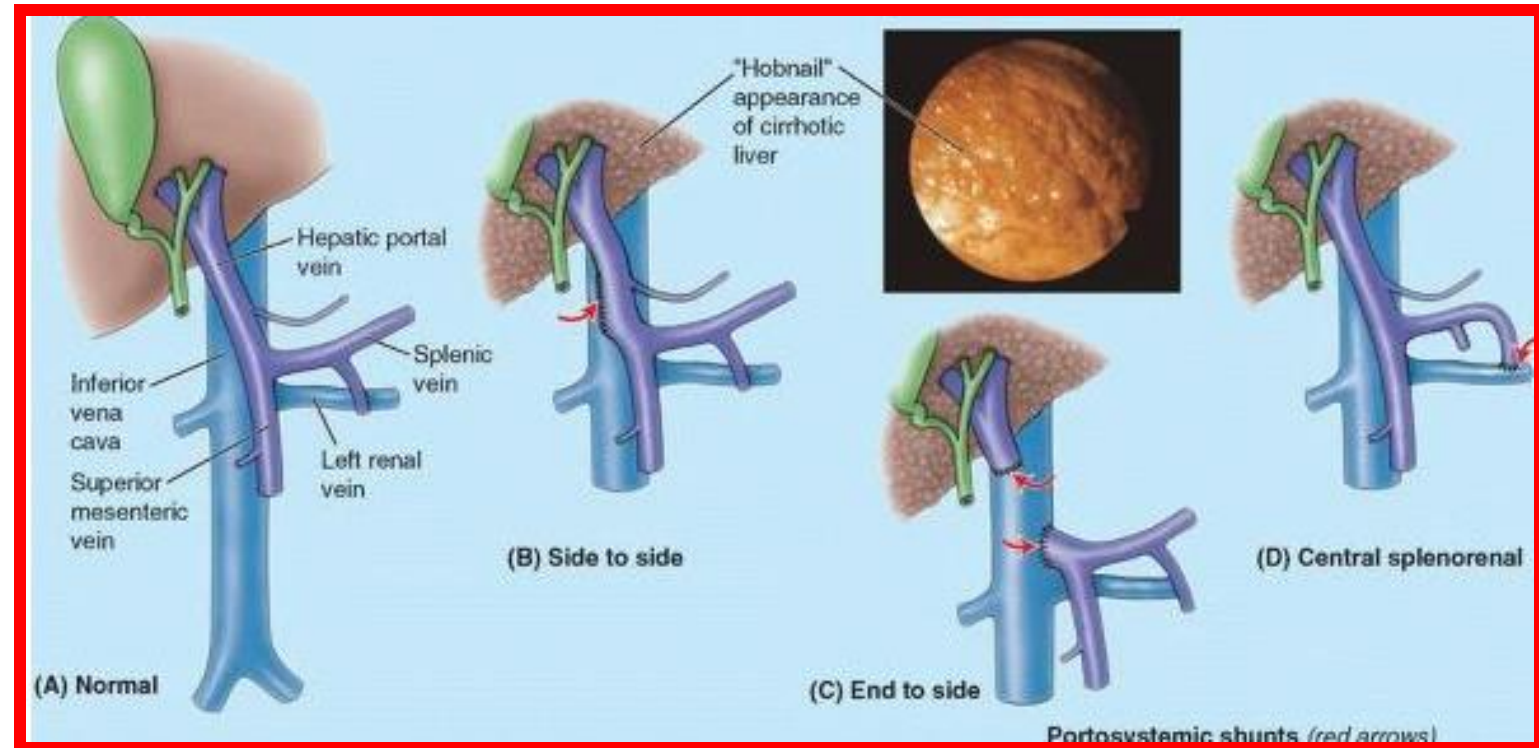


Dr. Aiman Al Maathidy  
Wednesday 22 April 2026

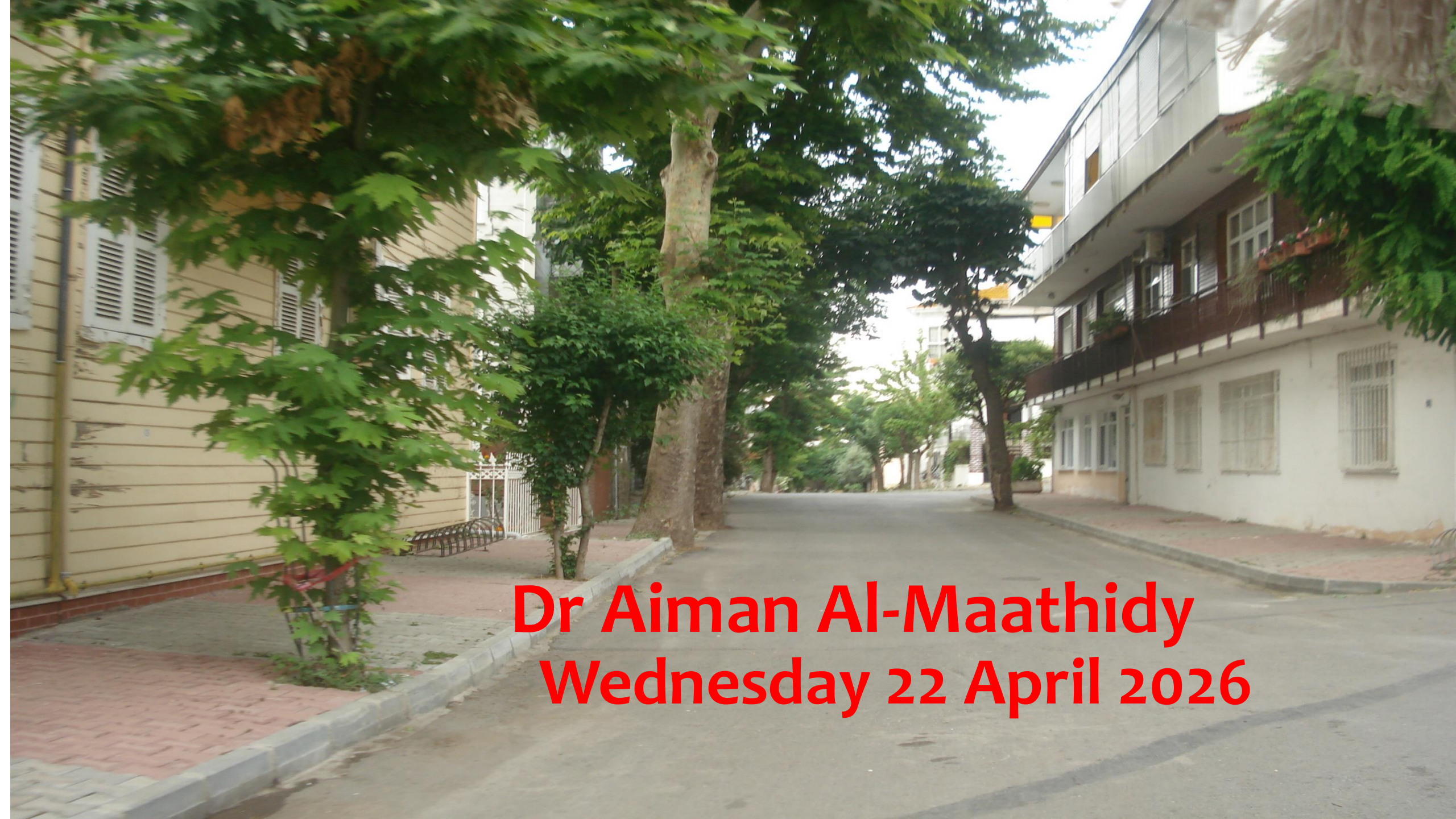


# Portal Hypertension

A common method for reducing portal hypertension is to divert blood from **the portal venous system** to **the systemic venous system** by creating a communication between **the portal vein** and **the IVC** or by joining **the splenic and left renal veins** — **a portacaval anastomosis or portosystemic shunt**



Dr. Aiman Al Maathidy  
Wednesday 22 April 2026

A photograph of a street scene. On the left is a yellow building with white shutters. On the right is a white building with a balcony. The street is paved and lined with trees. The text is overlaid in red at the bottom.

**Dr Aiman Al-Maathidy**  
**Wednesday 22 April 2026**